

**DIAGNOSTIC AND THERAPEUTIC INNOVATIONS
IN THE ERA OF PRECISION MEDICINE –
NUCLEAR MEDICINE MEETS NEURO-ONCOLOGY**

ABSTRACTBOOK

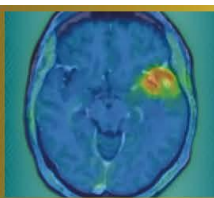
NMN Symposium: Precision Medicine

07.-08. May 2026 / Vienna, Austria
Apothekertrakt, Schönbrunn

www.nmn-society.org

Nuclear Medicine and Neurooncology (NMN)

Only the conflict of interests of individuals with a disclosure are included in the respective abstracts.



Abstract Number:2

Abstract Title: Features of PET/CT with FET interpretation after proton radiation therapy of patients with IDH wildtype glioblastoma

Authors:

Elena Gromova¹, Nikita Kataev¹, Daniil Susin¹

¹Ldc Mibs, Saint-Petersburg, Russian Federation

Background

To identify the features of PET/CT with fluoroethyltyrosine in patients with IDH wildtype glioblastoma who received proton therapy as part of adjuvant chemoradiation treatment.

Material/Methods

We evaluated 17 PET/CT c FET studies in 13 patients 3-18 (median 5.5, SD 12) months after proton therapy. PET/CT was performed at the decision of the neuro-oncologist for differential diagnosis of radionecrosis and progression.

PET-CT was performed according to the standard protocol: scanning 20 min after RFP injection, scanning time 20 min. The evaluation was performed by semi-quantitative method, with TBTmax calculation, as well as with comparison with MRI data and irradiation plans.

Radiation therapy was delivered to all patients with a scanning pencil beam using 2 5/13 (38%) or 3 8/13 (62%) fields. In 10/13 (76.9%) cases, at least one of the fields was not coplanar. Two radiation therapy regimens were used: 45 Gray for 15 fractions and 60 Gray for 30 fractions (112.5-120.0 BED)

Cases of RFP hyperfixation foci outside the initial volume of high (D95%) dose were considered separately - the zones of their occurrence, correlations between the necrosis site and the direction of proton therapy fields were determined separately.

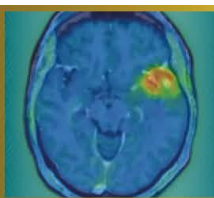
Results

In total, in 13 primary studies, 6 studies were interpreted as radionecrosis (TBRmax up to 2.4), 2 as disease progression (TBRmax 3.2), 5 could not be interpreted unambiguously according to current guidelines and required dynamic follow-up.

In two cases, we encountered cases of necrosis outside the original high volume (D95%). In both cases two fields were used, in one case coplanar. In both cases, radionecrosis occurred in the paraventricular regions of the lobar lobes (TBRmax 2.3).

Conclusion

1. TBRmax in cases diagnosed as radionecrosis is higher than in guidelines
2. Comparison with the radiation plan is important.
3. PET/CT before treatment to assess tumor metabolic activity - highly desirable



Abstract Number: 3

Abstract Title: Prognostic significance of PET RANO 1.0 response in patients with newly diagnosed IDH wild-type glioblastoma and longitudinal FET PETs

Authors:

Isabelle von Polenz¹, Katharina Müller², Lilian Wiegand¹, Maximilian Mair³, Jonas Reis⁴, Stephan Schönecker⁵, Robert Forbrig⁴, Florian Ringel⁶, Matthias Preusser³, Patrick Harter⁷, Louisa von Baumgarten⁶, Nathalie L. Albert¹

¹University Hospital of Munich, Department of Nuclear Medicine, Munich, ²University Hospital of Munich, Department of Neurology, Munich, ³Medical University of Vienna, Clinical Department of Oncology, Vienna, ⁴University Hospital of Munich, Department of Neuroradiology, Munich, ⁵University Hospital of Munich, Department of Radiation Oncology, Munich, ⁶University Hospital of Munich, Department of Neurosurgery, Munich, ⁷University Hospital of Munich, Department of Neuropathology, Munich

Objective

The PET RANO 1.0 criteria, introduced in 2024, enable standardized response classification of diffuse gliomas using [18F]FET PET imaging. However, their correlation with survival has not yet been sufficiently investigated. In this study, we therefore correlated the clinical course of glioblastoma patients with the PET RANO 1.0 response at defined timepoints.

Methods

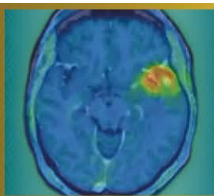
Patients with newly diagnosed IDH wild-type glioblastoma who underwent [18F]FET PET imaging before first-line radiotherapy (“baseline”) and three and/or six months after therapy initiation were included. We determined the response according to PET RANO 1.0 (progressive disease (PET-PD), stable disease (PET-SD), partial response (PET-PR), or complete response (PET-CR)) between all scans. Finally, we compared patients with PET-PD and PET-SD/PR/CR in terms of overall survival (OS), progression-free survival (PFS), and time to next intervention (TTNI). Kaplan-Meier and log-rank tests were used for statistical analyses.

Results

The PET intervals “baseline vs. 3 months” (n = 126), “baseline vs. 6 months” (n = 78), and “3 vs. 6 months” (n = 64) were examined in a cohort of 140 patients (median follow-up = 44.8 months). Across all three intervals, patients with PET-PD demonstrated a significantly shorter median OS compared with PET-SD/PR/CR (13.2 vs. 23.6 months, p = 0.003; 14.1 vs. 27.5 months, p < 0.001; and 14.3 vs. 36.4 months, p < 0.001, respectively). Similar significant differences were also observed for PFS and TTNI (all p < 0.001). Multivariate regression analyses at baseline revealed a prognostic relevance of MGMT methylation (HR = 0.55, p = 0.007, 59/135 patients).

Conclusion

Our results show a significant correlation between PET RANO 1.0 response and OS, PFS, and TTNI in patients with newly diagnosed glioblastoma. This suggests that standardized response classification according to PET RANO 1.0 and close follow-up using [18F]FET PET may support clinical management.



Abstract Number: 4

Abstract Title: [18F]FET PET enables histopathology-validated detection of non-contrast-enhancing glioblastoma

Authors:

Roman Stürzl¹, Sabrina Kirchleitner², Julia Lorenz³, Katharina Müller⁴, Veit Stöcklein², Stephanie Quach⁵, Lena Kaiser¹, Sophie Stöcklein⁶, Adrian Zounek¹, Enio Barci¹, Isabell von Polenz¹, Jens Blobner², Tobias Greve², Matthias Brendel^{1,7,8}, Patrick Harter⁹, Victoria Ruf⁹, Rainer Rupprecht¹⁰, Florian Ringel², Darius Kalasauskas², Markus Riemenschneider³, Niklas Thon¹¹, Louisa von Baumgarten^{2,12}, Jörg Christian Tonn², Nathalie Albert^{2,12}

¹Department of Nuclear Medicine, University Hospital, LMU Munich, Munich, Germany, ²Department of Neurosurgery, University Hospital, LMU Munich, Munich, Germany, ³Department of Neuropathology, University Hospital Regensburg, Regensburg, Germany, ⁴Department of Neurology, LMU University Hospital, LMU Munich, Munich, Germany, ⁵Department of Neurosurgery, University Hospital OWL, Campus Bielefeld-Bethel, Bielefeld, Bielefeld, Germany, ⁶Department of Radiology, University Hospital, LMU Munich, Munich, Germany, ⁷German Center for Neurodegenerative Diseases (DZNE), Munich, Munich, Germany, ⁸Munich Cluster for Systems Neurology (SyNergy), Munich, Munich, Germany, ⁹Center for Neuropathology and Prion Research, Faculty of Medicine, LMU Munich, Munich, Germany, ¹⁰Department of Psychiatry and Psychotherapy, University of Regensburg, Regensburg, Regensburg, Germany, ¹¹Department of Neurosurgery, Knappschaft Hospital, University Hospital Bochum, Bochum, Bochum, Germany, ¹²German Cancer Consortium (DKTK), Partner Site Munich, German Cancer Research Center (DKFZ), Heidelberg, Heidelberg, Germany

Background & aim

Preoperative delineation of tumor tissue in glioblastoma is crucial for planning surgical intervention as well as radiotherapy. While contrast-enhanced MRI (CE-MRI) is standard in routine clinical practice, it has limitations in detecting metabolically active tumor tissue in the absence of blood–brain barrier disruption. This study aimed to determine whether amino acid PET using O-(2-[18F]fluoroethyl)-L-tyrosine (FET) can overcome these limitations and provide a more sensitive assessment of tumor extent.

Patients & methods

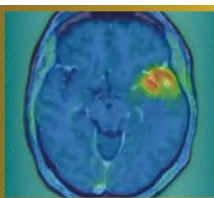
In this prospective, biopsy-validated single-center study, 472 spatially correlated biopsies from 61 patients with glioblastoma, IDH-wildtype (44 newly diagnosed, 17 recurrent) were histopathologically evaluated after preoperative FET PET and CE-MRI. Diagnostic metrics were calculated and compared between modalities using McNemar and Chi² tests (p = 0.05).

Results

FET PET achieved significantly higher sensitivity for tumor detection compared to CE-MRI (91.2% vs. 55.7%; p < 0.001). In comparison with T2/FLAIR, FET showed higher sensitivity (85.3%; p = 0.012) and markedly improved specificity (82.5% vs. 33.3%, p < 0.001). Importantly, FET reliably detected tumor tissue even in FET-positive but non-enhancing biopsies (positive predictive value/PPV 98.3%). Subgroup analyses confirmed the superiority of FET across all clinical and histological categories, including newly diagnosed and recurrent cases (p < 0.001), as well as in resection (p < 0.001; specificity p = 0.03) and biopsy subgroups (p < 0.001). FET was also significantly superior to CE-MRI in detecting tumor tissue irrespective of tumor cell density (“infiltration zone” vs. “solid tumor”; p < 0.001).

Discussion & conclusion

FET PET demonstrates significant, diagnostic superiority over CE-MRI for the visualization of glioblastoma tissue. Comparable PPVs in contrast-enhancing and non-enhancing regions indicate that FET PET detects tumor reliably, independent of the blood–brain barrier integrity. These findings support the integration of amino acid PET as a key component in surgical planning and target definition for glioblastoma.



Abstract Number:5

Abstract Title: Intra-arterial 4- [²¹¹At]astato-L-phenylalanine ([²¹¹At]APA) in [¹⁸F]fluoroethyl-L-tyrosine ([¹⁸F]FET) positive recurrent glioblastoma: study protocol for a phase 1 dose-escalation study (I-APACHE)

Authors:

Anass El Ghalbouni^{1,2}, Dr. Tom Snijders², Dr. Nelleke Tolboom¹, Dr. Berend van der Wildt¹, Dr. Morsal Samim¹, Prof. Dr. Irene van der Schaaf¹, Dr. Alex Poot¹, Dr. Arthur Braat^{1,3}

¹Radiology and Nuclear Medicine, UMC Utrecht, Utrecht, Netherlands, ²Neurology and Neurosurgery, Brain Center, UMC Utrecht, Utrecht, Netherlands, ³Nuclear Medicine, Netherlands Cancer Institute, Amsterdam, Netherlands

Background

Glioblastoma is an invariably fatal primary brain tumor with limited treatment options. Therapeutic approaches are currently under investigation, with [¹³¹I]IPA entering phase III clinical trials. Building on this concept, we propose the use of 4-[²¹¹At]astato-L-phenylalanine ([²¹¹At]APA). Compared with ¹³¹I, the α -emitter [²¹¹At] offers higher tumoricidal potential, while radiation exposure to family members and hospital personnel is minimal due to the absence of γ -emission. This enables outpatient-based treatment, thereby reducing patient burden. Based on prior experience, superselective intra-arterial administration is expected to improve intratumoral accumulation of [²¹¹At]APA. In this study, we will conduct a phase 1 dose-escalation study to assess the safety and preliminary efficacy of intra-arterial administered [²¹¹At]APA.

Material and Methods


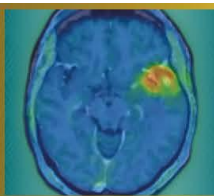
Patients are eligible if diagnosed with recurrent glioblastoma following standard-of-care temozolomide-chemoradiation and showing positivity on [¹⁸F]fluoroethyl-L-tyrosine ([¹⁸F]FET) PET. This 3+3 dose-escalation study will include four dose cohorts (starting at 50 MBq, up to 300 MBq). The dose-limiting toxicity period will be three weeks after the first cycle. Up to three cycles per participant are planned, administered at four-week intervals. Follow-up will continue for up to 42 weeks after completion of treatment. The primary endpoint is the maximum tolerated dose. Secondary outcomes include the maximum tolerated cumulative dose, preliminary efficacy, dosimetry and radiation safety.

Results

Currently, radiochemical production of [²¹¹At]APA is optimized and automated, as well as the logistical processes. Batch sizes are upscaled to >100 MBq, the minimally required patient dose. Preliminary production runs demonstrate high chemical yield, stability up to 24h and purity (>95%). Validation runs are scheduled for Q3 2026 for GMP production.

Conclusion

This is the first clinical trial to evaluate the safety and feasibility of [²¹¹At]APA in patients with recurrent glioblastoma. Investigating and confirming the feasibility of repeated superselective intra-arterial administrations will further contribute to maximizing the potential of this new radiopharmaceutical in neuro-oncology.



Abstract Number: 6

Abstract Title: Radionuclide Therapy with [¹⁷⁷Lu]Lu-DOTATATE in Refractory Meningiomas: Results from the French Multicenter MELUTE Cohort

Authors:

Dr Nicolas Garabedian¹, Dr Timothée Zaragori², Pr Emeline Tabouret³, Dr Catherine Ansquer⁴, Dr Sarah Boughdad⁵, Dr Caroline Bund⁶, Pr Catherine Cheze-Le-Rest⁷, Pr Jacques Darcourt⁸, Dr Gauthier Delaby⁹, Dr Inna Dygai-Cochet¹⁰, Pr Emmanuel Deshayes¹¹, Dr Agathe Edet-Sanson¹², Dr Anthime Flaus¹³, Dr Thibault Fidani¹⁴, Dr Tatiana Horowitz¹⁵, Dr Vija Lavinia¹⁶, Dr Pierre Meneret¹⁷, Dr Elisabeth Quak¹⁸, Dr Solene Querellou¹⁹, Dr Ghoufrane Tlili²⁰, Pr Matthieu Peyre²¹, Pr Thomas Gaillon²², Dr Caroline Boursier-Joppin²³, **Antoine Verger**¹

¹CHRU Nancy, Nancy, France, ²CHRU Nancy, Nancy, France, ³APHM, Marseille, France, ⁴CHU Nantes, Nantes, France, ⁵APHP, Paris, France, ⁶ICANS, Strasbourg, France, ⁷CHU Poitiers, Poitiers, France, ⁸Cote d'Azur University, Nice, France, ⁹CHRU Lille, Lille, France, ¹⁰CGFL Dijon - Centre Régional De Lutte Contre Le Cancer Georges-François Leclerc, Dijon, France, ¹¹Institut Régional du Cancer de Montpellier ICM, Montpellier, France, ¹²Centre Henri Becquerel, Rouen, France, ¹³CHU Lyon, Lyon, France, ¹⁴CHU Nîmes, Nîmes, France, ¹⁵APHM, Marseille, France, ¹⁶IUCT Oncopole, Toulouse, France, ¹⁷Centre Eugène Marquis, Rennes, France, ¹⁸Centre François Baclesse, Caen, France, ¹⁹CHU Brest, France, Brest, France, ²⁰CHU Bordeaux, Bordeaux, France, ²¹APHP, Paris, France, ²²AP-HM, Marseille, France, ²³CHRU Nancy, Nancy, France

Background

Evidence supporting the efficacy and safety of [¹⁷⁷Lu]Lu-DOTATATE in refractory meningiomas is mainly derived from small, single-center studies with heterogeneous protocols. The French national multicenter MELUTE study aimed to consolidate these findings using a standardized regimen within a compassionate use program approved by a national multidisciplinary tumor board.

Methods

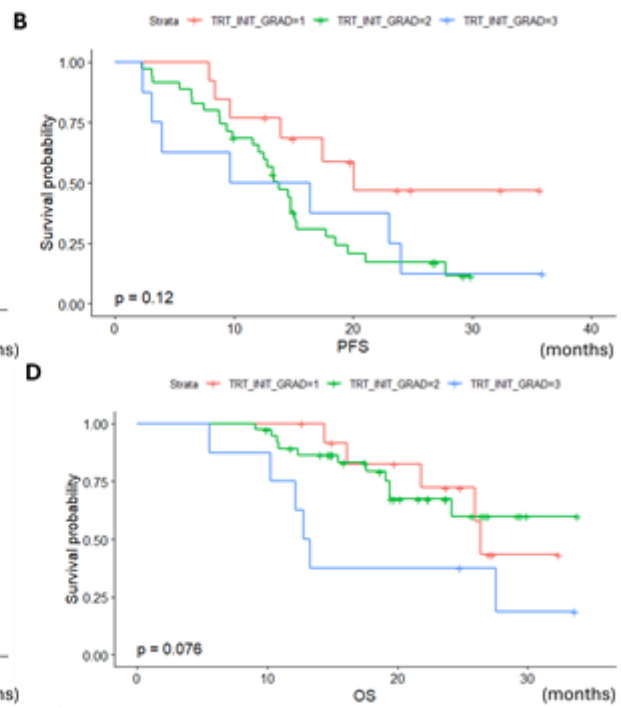
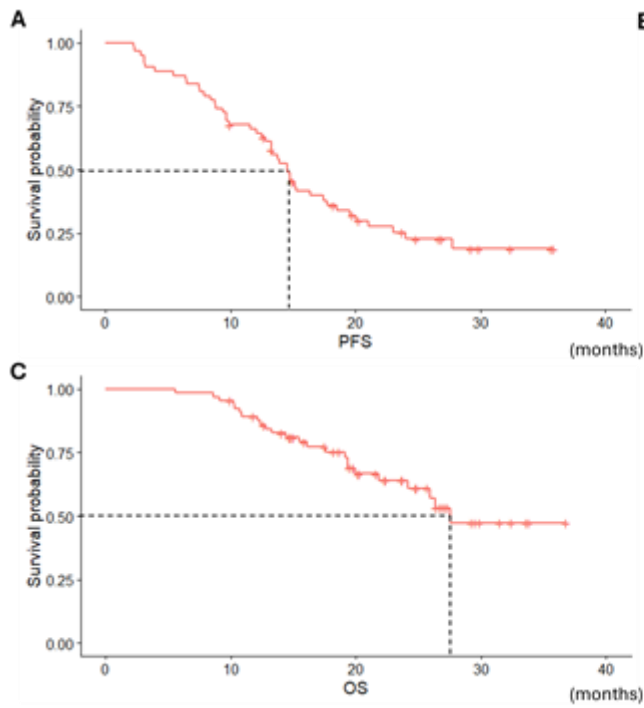
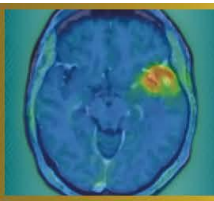
Patients with refractory meningiomas treated with [¹⁷⁷Lu]Lu-DOTATATE in 18 French centers between July 2022 and December 2024 were retrospectively included. Treatment consisted of 7.4 GBq administered every 8 weeks for up to four cycles. Clinical data, including demographics, histological grade, prior treatments, number of cycles, toxicity, disease progression, and survival status (October 1, 2025), were collected using an electronic case report form. Baseline [⁶⁸Ga]Ga-DOTATOC PET and pre- and post-treatment brain MRI scans were centrally reviewed. The primary endpoint was 6-month progression-free survival (PFS-6) assessed using volumetric RANO criteria. Secondary endpoints included progression-free survival (PFS), overall survival (OS), safety and tumor growth rates (TGRs) differences after treatment.



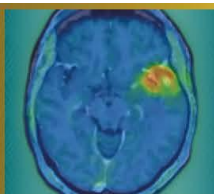
Results

Sixty-nine patients were included (mean age 65.1 ± 13.2 years; 52% female), including 13 grade 1, 42 grade 2, 8 grade 3, and 6 unclassified meningiomas. Most patients had undergone surgery (86%) and radiotherapy (93%), and 32% had received prior systemic therapy. Twelve patients (17%) did not complete all four cycles; only one discontinuation was related to toxicity. PFS-6 was 70%. Median PFS was 14.6 months and median OS was 27.6 months. Grade ≥3 adverse events occurred in 16% of patients, mainly lymphopenia. The difference in TGRs before versus after [¹⁷⁷Lu]Lu-DOTATATE therapy was -16.6 [-47.4; -2.1]% per 6 months. Meningioma grade independently predicted PFS, while higher KPS and corticosteroid use were protective; worse OS was associated with higher baseline TGR and prior systemic therapy.

Conclusion

MELUTE demonstrates promising efficacy and a favorable safety profile of [¹⁷⁷Lu]Lu-DOTATATE in refractory meningiomas with limited therapeutic options.





Abstract Number: 7

Abstract Title: Translational Potential of MAO-B PET Imaging as a Biomarker in Glioblastoma

Authors:

Justus Thevis^{1,11}, Laura M Bartos^{1,2,3}, Lea H Kunze^{1,4}, Manvir Lalia¹, Marlies Haertel¹, Isabelle S Fuxjäger⁵, Ha Eun Park¹, Karin Wind¹, Giovanna Palumbo¹, Rosel Oos¹, Patrick N Harter^{7,11,12}, Rudolf A Werner^{1,10}, Nathalie L Albert^{1,11,12}, Louisa von Baumgarten^{6,8,11,12}, Matthias Brendel^{1,4,9,12}

¹Department of Nuclear Medicine, LMU University Hospital, LMU Munich, Munich, Germany, ²Institute of Clinical Neuroimmunology, LMU University Hospital, LMU Munich, Munich, Germany, ³Biomedical Center (BMC), Faculty of Medicine, LMU Munich, Munich, Germany, ⁴German Center for Neurodegenerative Diseases (DZNE), Munich, Germany, ⁵German Center for Vertigo and Balance Disorders (DSGZ), Munich, Germany, ⁶Department of Neurology, LMU University Hospital, LMU Munich, Munich, Germany, ⁷Center for Neuropathology and Prion Research, Faculty of Medicine, LMU Munich, Munich, Germany, ⁸Department of Neurosurgery, LMU University Hospital, LMU Munich, Munich, Germany, ⁹Munich Cluster of Systems Neurology, Munich, Germany, ¹⁰Russell H. Morgan Department of Radiology and Radiological Sciences, Johns Hopkins School of Medicine, Baltimore, USA, ¹¹German Cancer Consortium (DKTK), Partner Site Munich, Munich, Germany, ¹²Bavarian Cancer Research Center (BZKF), Partner Site Munich, Munich, Germany

Background

Astrogliosis is a key feature of numerous neurological disorders; however, its role in neuro-oncological diseases remains poorly understood. [¹⁸F]deuterium-L-deprenyl (F-DED) PET enables non-invasive in vivo assessment of astrocyte activity. In glioblastoma (GB) it is currently unclear whether the [¹⁸F]F-DED PET signal primarily reflects reactive astrogliosis or is confounded by increased MAO-B expression in tumor cells. This study investigated the potential of [¹⁸F]F-DED PET to characterize astrogliosis in glioblastoma mouse models and GB patients.

Methods

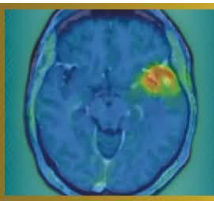
MAO-B expression in GB patients was analysed immunohistochemically in tumor tissue sections. In mice, tumors were induced by stereotactic inoculation of 1×10^3 SB28, 1×10^3 GL261 or 1×10^5 U87 cells. Longitudinal 60-min dynamic [¹⁸F]F-DED PET scans were performed between days 4 and 31 after inoculation. In addition, mouse brains were analysed using ex vivo autoradiography (ARG) and immunohistochemistry (IHC). Tracer uptake was quantified using tumor-to-background ratios (TBR) and volume of distribution (VT).

Results

Analysis of human GB samples revealed increased MAO-B expression in both tumor cells and surrounding astrocytes. In contrast, [¹⁸F]F-DED PET in all mouse models showed no relevant contrast between tumor and contralateral brain tissue (TBR SB28: 1.10; GL261: 1.07; U87: 1.03). Low intratumoral MAO-B expression was confirmed by VT analysis and ex vivo ARG. IHC demonstrated pronounced peritumoral astrogliosis. This astrogliosis was not associated with increased MAO-B expression.

Conclusions

In commonly used preclinical GB models, neither tumor cells nor peritumoral astrogliosis are characterized by increased MAO-B expression. These findings highlight limitations of these models in recapitulating the situation observed in human glioblastoma patients and suggest that distinct forms of astrocyte activation differ in their associated MAO-B expression.



Abstract Number: 8

Abstract Title: Comparative response assessment using PET-RANO 1.0 and RANO 2.0 in vorasidenib-treated IDH-mutant gliomas: the VORAFET study

Authors:

Prof. Diego Cecchin¹, Alberto Bosio^{2,3}, Dr. Tamara Ius⁴, Dr. Giovanni Librizzi^{5,6}, Dr. Mario Caccese³, Dr. Marta Padovan³, Francesco Cavallin⁷, Dr. Marta Maccari^{2,3}, Dr. Rossella Simeone¹, Dr. Francesca Serani¹, Prof. Luca Denaro⁴, Dr. Sara Lonardi³, Prof. Matthias Preusser⁸, Prof. Nathalie Lisa Albert⁹, Dr. Giuseppe Lombardi³

¹Unit of Nuclear Medicine, Department of Medicine -DIMED, University Hospital of Padua, Padova, Italy, ²Department of Surgery, Oncology and Gastroenterology, University of Padova, Padova, Italy, ³Medical Oncology 1, Veneto Institute of Oncology IOV - IRCCS, Padova, Italy, ⁴Academic Neurosurgery, Department of Neurosciences, University of Padova, Padova, Italy, ⁵Padova Neuroscience Center (PNC), University of Padova, Padova, Italy, ⁶Neuroradiology Unit, Padova University Hospital, Padova, Italy, ⁷Independent Statistician, Solagna, Italy, ⁸Division of Oncology, Department of Medicine I, Medical University of Vienna, Vienna, Austria, ⁹Department of Nuclear Medicine, LMU University Hospital, LMU Munich, Munich, Germany

Background

MRI-based response assessment may be suboptimal for capturing early treatment effects during isocitrate dehydrogenase (IDH) inhibition. We compared metabolic and morphological response classification using PET-RANO 1.0 and RANO 2.0 in vorasidenib-treated IDH-mutant gliomas and assessed treatment-related metabolic changes.

Methods

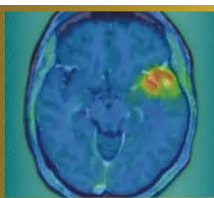
All consecutive patients treated at Veneto Institute of Oncology and at Padua University Hospital with vorasidenib (VOR) under a compassionate-use program (June 2024–March 2025) with baseline and follow-up [18F]FET PET/MR were retrospectively included. Response was assessed every 3 treatment cycles according to PET-RANO 1.0 and RANO 2.0. PET-positive tumor volumes and tumor-to-background ratios (TBR_{max}, TBR_{mean}) were analyzed. MRI response was evaluated using volumetric RANO 2.0 criteria.

Results

Twenty-six patients were included (10 astrocytomas, 16 oligodendrogliomas; 22 WHO grade 2, 4 non-enhancing WHO grade 3). Median follow-up from VOR initiation was 9 months (IQR 9–11). According to PET-RANO 1.0, partial metabolic responses (PET-PR) increased over time, from 20% at 3 months to 30.8% at 6 months and 63.6% at 9 months, while metabolic progression (PET-PD) was already detected in 18.2% at 9 months. Conversely, RANO 2.0 identified no partial responses at any timepoint, classifying most patients as stable disease (SD, 84.2%) or minor response (MR, 10.5%), with progression (PD) detected in only 5.3% at 9 months. Quantitative PET analysis showed an early and sustained reduction in metabolic activity. TBR_{mean} decreased significantly at 3 months (mean difference [MD] -0.04; 95% CI -0.08 to -0.01) and continued to decline at 9 months (MD -0.07; 95% CI -0.11 to -0.02). Compared to baseline, at 9 months, TBR_{max} decreased from 2.7 to 2.0 (MD -0.5; 95% CI -0.8 to -0.2) in all patients included. No significant changes were observed in PET volumes. Similarly, FLAIR-based tumor volume showed no significant variation (at 9 months: MD -2.2; 95% CI -5.1 to 0.7).

Conclusions

PET-RANO 1.0 enabled earlier detection of treatment response and progression compared with MRI-based RANO 2.0, highlighting clinically relevant limitations of morphology-driven MRI-based assessment. These findings support the clinical integration of amino acid PET into response monitoring strategies and warrant prospective validation of PET-derived biomarkers in IDH-mutant gliomas.



Abstract Number: 10

Abstract Title: Predictive PET imaging of tumor infiltration and recurrence in glioblastoma

Authors:

Keisuke Miyake¹, Masaki Tatano¹, Satoshi Mino¹, Kenta Suzuki¹, Takeshi Fujimori¹, Daisuke Ogawa¹, Tetsuhiro Hatakeyama¹, Masanobu Okauchi¹, Masahiko Kawanishi¹

¹Department Of Neurological Surgery, Kagawa University Faculty Of Medicine, Kagawa, Japan

Background

Glioblastoma (GBM) is characterized by highly infiltrative growth, and tumor recurrence frequently arises from regions surrounding the resection cavity or tumor margin. However, conventional MRI, including contrast-enhanced and FLAIR imaging, often underestimates early infiltrative changes. Amino acid PET using ¹¹C-methionine (MET) mainly reflects tumor cell density, whereas ¹⁸F-THK5351 (THK5351) PET, associated with reactive astrocytoma and gliosis, may visualize infiltrative tumor-related changes beyond structural abnormalities.

Materials and Methods

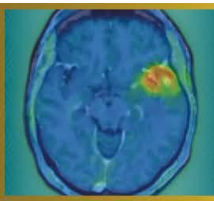
Thirty-three patients with newly diagnosed GBM who underwent surgical resection and preoperative THK5351 PET were retrospectively analyzed; MET PET was available in a subset. Metabolic tumor volumes (MTV) derived from MET and THK5351 PET were compared with MRI-derived FLAIR volumes. Spearman correlation coefficients were calculated between PET MTVs and FLAIR volume. Recurrence patterns were evaluable in 25 patients and classified as local recurrence confined to the resection cavity margin or distant recurrence, including contralateral, different lobar, or disseminated lesions.

Results

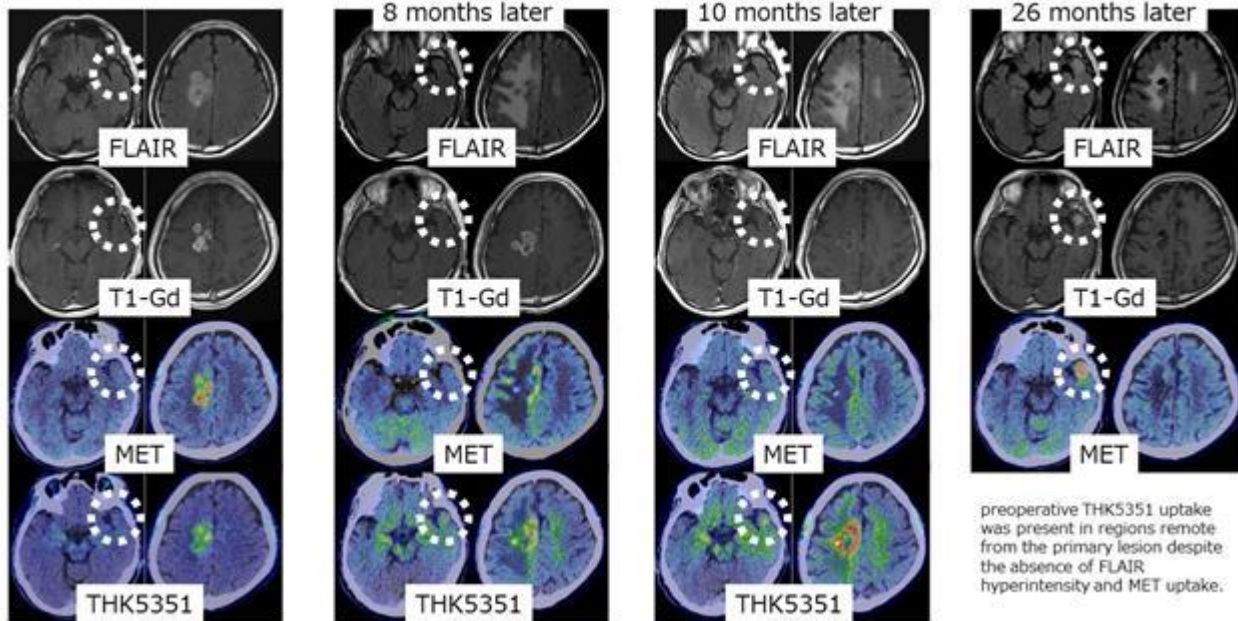
Both MET and THK5351 MTV correlated significantly with FLAIR volume; however, THK5351 MTV showed a stronger correlation than MET MTV ($p < 0.001$). MET and THK5351 MTVs were also correlated ($p < 0.001$). The median MTV/FLAIR ratio was higher for THK5351 (0.81) than for MET (0.62). Among 25 patients with documented recurrence, local recurrence occurred in 5 patients, whereas distant recurrence was observed in 2 patients. In distant recurrence cases, preoperative THK5351 uptake was present in regions remote from the primary lesion despite the absence of FLAIR hyperintensity and MET uptake.

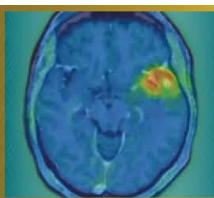
Conclusions

THK5351 PET demonstrates a stronger volumetric association with FLAIR abnormalities and wider metabolic tumor extent than MET PET. Importantly, THK5351 uptake can precede radiological recurrence in MRI- and MET-negative remote regions, suggesting that THK5351 PET may serve as a predictive imaging biomarker for infiltrative spread and distant recurrence in GBM.



Predictive PET imaging of tumor infiltration





Abstract Number: 11

Abstract Title: Comparison of [^{18}F] Fluciclovine PET, [^{18}F] FDG PET, and Contrast-Enhanced MRI in the Preoperative Identification of High-Grade Glioma

Authors:

Hiroto Koga^{1,2}, Shiro Watanabe^{1,2}, Kenji Hirata^{1,2}, Shigeru Yamaguchi³, Yukitomo Ishi³, Naoto Wakabayashi^{1,2}, Kohsuke Kudo¹

¹Department of Diagnostic Imaging, Graduate School of Medicine, Hokkaido University, Sapporo, Hokkaido, Japan,

²Department of Nuclear Medicine, Hokkaido University Hospital, Sapporo, Hokkaido, Japan, ³Department of Neurosurgery, Graduate School of Medicine, Hokkaido University, Sapporo, Hokkaido, Japan

Background

Accurate preoperative identification of high-grade glioma (HGG) is essential for surgical planning and treatment decision-making. [^{18}F] fluciclovine, a synthetic amino acid PET tracer originally developed for prostate cancer imaging, has been covered by the Japanese National Health Insurance System for imaging of high-grade glioma since June 2024. This study aimed to directly compare the diagnostic performance of [^{18}F] fluciclovine PET, [^{18}F] FDG PET, and contrast-enhanced MRI for identifying HGG in patients with clinically suspected brain tumors.

Material and Methods

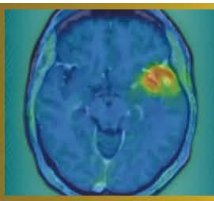
In this retrospective single-center study, patients who underwent preoperative [^{18}F] fluciclovine PET, [^{18}F] FDG PET, and contrast-enhanced MRI between July 2024 and December 2025 were analyzed. Histopathological diagnoses were established according to the 2021 WHO CNS classification. Tumor-to-background ratios (TBRs) were calculated using cortical (CX) and white matter reference regions (WM). Diagnostic performance metrics were assessed, optimal TBR cutoffs were determined using the Youden index. Receiver operating characteristic (ROC) analyses and DeLong tests were performed for modality comparison.

Results

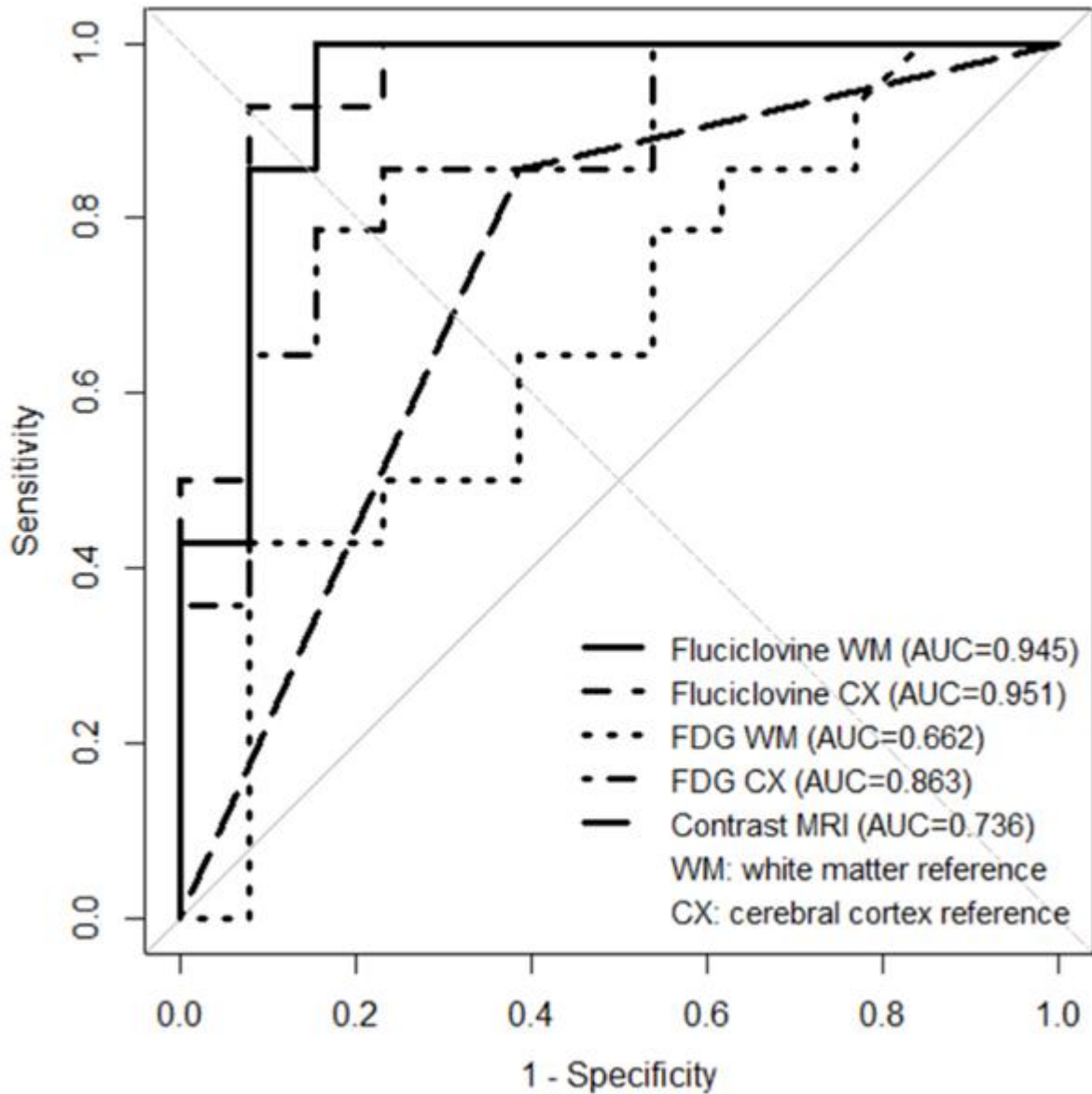
The study cohort consisted of 27 patients (14 high-grade gliomas [HGGs] and 13 non-HGGs). Using white matter as the reference region, [^{18}F] fluciclovine PET achieved a sensitivity of 100%, specificity of 84.6%, positive predictive value of 87.5%, negative predictive value of 100%, and accuracy of 92.6%. Similar performance was observed with cortical reference (sensitivity 92.9%, specificity 92.3%, accuracy 92.6%). In comparison, [^{18}F] FDG PET demonstrated lower diagnostic performance, with accuracies of 66.7–81.5%, and contrast-enhanced MRI showed an accuracy of 74.1%. Receiver operating characteristic analysis demonstrated the highest area under the curve for [^{18}F] fluciclovine PET (Figure).

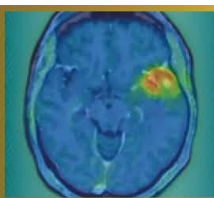
Conclusion

[^{18}F] fluciclovine PET demonstrated higher diagnostic performance for identifying high-grade glioma than [^{18}F] FDG PET and contrast-enhanced MRI. These findings suggest that [^{18}F] fluciclovine PET provides clinically relevant metabolic information and may have potential utility in the preoperative evaluation of suspected high-grade glioma.



ROC curves for HGG vs non-HGG





Abstract Number: 12

Abstract Title: Background Activity Assessment in ^{18}F -FET PET Imaging

Authors:

Poh Hui Phang¹, Dr Sarah Beishan Tai², Dr Wei Ming Chua^{2,3}, Assistant Professor Xuling Lin⁴, Associate Professor Chee Kian Tham⁵, Assistant Professor Ding Fang Chuang⁴, Ms Jacqueline Su-Lin Teo⁶, Assistant Professor Kevin Lee Min Chua⁷, Associate Professor Winnie Wing Chuen Lam²

¹Lee Kong Chian School of Medicine, Nanyang Technological University, Singapore, Singapore, ²Department of Nuclear Medicine and Molecular Imaging, Singapore General Hospital, Singapore, Singapore, ³Department of Neuroradiology, Singapore General Hospital, Singapore, Singapore, ⁴Department of Neurology, National Neuroscience Institute, Singapore, Singapore, ⁵Division of Medical Oncology, National Cancer Centre Singapore, Singapore, Singapore, ⁶SingHealth Investigational Medicine Unit, Singapore Health Services, Singapore, Singapore, ⁷Division of Radiation Oncology, National Cancer Centre Singapore, Singapore, Singapore (co-last author)

Background

Background activity measurements are key for calculation of various PET parameters for clinical interpretation of ^{18}F -FET PET imaging in glioblastoma. Hence, careful choice of background reference methods is needed to accurately calculate these parameters. Guidelines recommend using crescent-shaped background volume-of-interest (VOI). However, this approach can be time-consuming and impractical in clinical workflows. We evaluate a simpler spherical background VOI as a feasible alternative for ^{18}F -FET PET parameter calculations, while maintaining non-inferior accuracy in differentiating tumour recurrence from pseudoprogression.

Methods

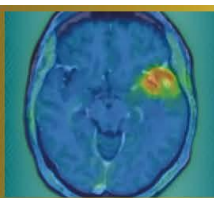
Two readers independently evaluated ten ^{18}F -FET PET scans of high-grade glioma patients with MRI findings equivocal for tumour recurrence versus pseudoprogression (eventual diagnosis N=11 vs N=1 lesions respectively). Background activity assessment was performed using spherical VOIs of 30mm diameter and crescent-shaped VOIs. Key PET parameters such as mean standardised uptake value (SUVmean) and tumour-to-brain ratio (TBR) were compared using paired two-tailed t-tests. Inter-reader variability and agreement were assessed using coefficient of variation (CoV) and intraclass coefficient correlation (ICC) respectively.

Results

Background SUVmean from the spherical method was significantly lower than the crescent method (1.02 vs 1.07, p=0.022). TBRmax from the spherical method was higher than that from the crescent method (5.70 vs 5.36, p<0.001). Nonetheless, the spherical method had comparable high sensitivity to the crescent method in distinguishing tumour recurrence from pseudoprogression (100% vs 100% respectively). However, due to the low number of pseudoprogression lesions, specificity could not be accurately assessed. CoV (5.13% vs 2.24%) and ICC (0.872 vs 0.983) metrics demonstrated good and excellent reliability for both the spherical and crescent method respectively.

Conclusions

Our preliminary results suggest that the spherical method holds promise as a viable, accurate and reliable alternative to the incumbent crescent method for background activity assessment in ^{18}F -FET PET imaging. Further recruitment and analysis of pseudoprogression cases may allow accurate determination of specificity and accuracy to support these findings.



Abstract Number: 13

Abstract Title: FET PET reveals considerable volumetric and spatial differences in tumor burden compared to conventional MRI in recurrent glioblastoma

Authors:

Norbert Galldiks^{1,2}, Julia Hilgers³, Keith George Ciantar³, Manuel Kraft¹, Jana-Marie Peplinski¹, Jan-Michael Werner¹, Michael Wollring¹, Isabelle Stetter¹, Garry Ceccon¹, Gereon Fink^{1,2}, Roland Goldbrunner⁴, Maximilian Ruge⁵, Nadim Shah³, Felix Mottaghy⁶, Karl-Josef Langen^{3,6}, Martin Kocher⁵, Philipp Lohmann^{3,6}

¹University Hospital Cologne, Dept. of Neurology, Cologne, Germany, ²Inst. of Neuroscience and Medicine (INM-3), Research Center Juelich, Juelich, Germany, ³Inst. of Neuroscience and Medicine (INM-4), Research Center Juelich, Juelich, Germany, ⁴University Hospital Cologne, Dept. of Neurosurgery, Cologne, Germany, ⁵University Hospital Cologne, Dept. of Stereotaxy and Functional Neurosurgery, Cologne, Germany, ⁶Dept. of Nuclear Medicine, University Hospital RWTH Aachen, Aachen, Germany

Background

In recurrent glioblastomas, changes in areas of contrast enhancement and the T2/fluid-attenuated inversion recovery (FLAIR) signal on conventional MRI represent the mainstay for local therapy planning. Nevertheless, compared to conventional MRI, the information on the tumor burden obtained from amino acid PET may be considerably different in terms of volumetric assessment and spatial orientation.

Methods

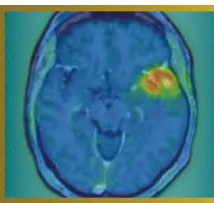
At suspected recurrence, 149 patients with histomolecularly characterized glioblastoma underwent O-(2-[¹⁸F]-fluoroethyl)-L-tyrosine (FET) PET and MR imaging including contrast-enhanced and FLAIR sequences. Contrast-enhancing and FLAIR volumes were automatically segmented using HD-GLIO, and FET PET tumor volumes were assessed using the nnUNet-based JuST_BrainPET segmentation tool based on a tumor-to-brain ratio of ≥ 1.6 . All segmentations were visually checked. Subsequently, an in-house developed workflow was used for a fully automated assessment of maximum and mean tumor-to-brain ratios. To evaluate spatial differences between the modalities, percentage overlap, the Dice similarity coefficient (DSC), and the 95th-percentile Hausdorff distance (HD95) were calculated. Recurrent disease was confirmed either by neuropathological evaluation of tissue obtained from surgery or stereotactic biopsy or prompted a change in treatment.

Results

All patients had measurable disease according to the PET RANO 1.0 criteria (mean tumor-to-brain ratio, 2.2 ± 0.2). In 52 patients (93%), the FET PET tumor volume was significantly larger than the contrast-enhancing volume (36.5 ± 31.6 mL vs. 18.5 ± 19.7 mL; $P < 0.001$). On average, FET PET tumor volumes extended by 30% beyond the combined contrast-enhancing and FLAIR volumes. The spatial similarity between FET uptake and contrast enhancement was limited (mean DSC, 0.40 ± 0.23), with an HD95 of 17.8 ± 12.2 mm. The comparison of FET uptake with the FLAIR hyperintensity revealed even lower spatial similarity (mean DSC, 0.35 ± 0.16), and a higher boundary discrepancy (HD95, 30.0 ± 14.2 mm).

Conclusions

Our results strongly support integrating both imaging modalities into treatment planning of patients with glioblastoma at recurrence.



Abstract Number: 14

Abstract Title: The added value of serial FET PET imaging to diagnose tumor progression in patients with glioblastoma

Authors:

Norbert Galldiks^{1,2}, Keith George Ciantar^{3,4}, Isabelle Stetter¹, Julia Hilgers³, Jana-Marie Peplinski¹, Manuel Kraft^{1,2}, Christian Filss^{3,5}, Gabriele Stoffels³, Karl-Josef Langen^{3,5}, Jan-Michael Werner¹, Philipp Lohmann^{3,5}

¹University Hospital Cologne, Dept. of Neurology, Cologne, Germany, ²Inst. of Neuroscience and Medicine (INM-3), Research Center Juelich, Juelich, Germany, ³Inst. of Neuroscience and Medicine (INM-4), Research Center Juelich, Juelich, Germany, ⁴Inst. for Imaging and Computer Vision, RWTH Aachen University, Aachen, Germany, ⁵Dept. of Nuclear Medicine, University Hospital RWTH Aachen, Aachen, Germany

Background

The vast majority of existing studies evaluating the diagnostic performance of O-(2-[18F]-fluoroethyl)-L-tyrosine (FET) PET to diagnose glioblastoma progression have relied primarily on single-scan assessments. Although the observed diagnostic performances are relatively high, uncertainties remain, especially in cases with borderline uptake close to recommended thresholds. To this end, we assessed the evolution of metabolic activity by comparing serial FET PET scans during the transition of glioblastoma progression.

Patients and methods

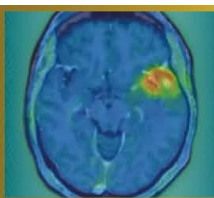
From 2019-2025, 131 patients with glioblastoma (CNS WHO 2021) who underwent 534 dynamic FET PET scans (median number, 3; range, 2-12) during the course of disease were retrospectively identified. Tumor-to-brain ratios (TBRmean, TBRmax), metabolic tumor volume (MTV), and time-to-peak (TTP) were obtained fully automated according to the current guidelines, at the time of suspected progression and in scans performed within a six-month window before glioblastoma progression. Progression was defined (clinico-)radiologically using the RANO criteria and subsequently prompted either neuropathological tissue confirmation following surgery, or initiation of new local or systemic treatment option, or combinations thereof.

Results

Seventy-one cases with progression in 61 patients were confirmed (eight patients had one additional progression, and one patient had two additional progressions). The median time between the two FET PET scans was 2.7 months (range, 0.9-6.0 months). At progression, TBRmean, TBRmax, and MTV were significantly increased compared to the reference scan (all $P \leq 0.002$). TTP values changed insignificantly ($P > 0.05$). While median percentage changes in the uptake parameters TBRmean and TBRmax showed moderate increases of 4% and 16%, respectively, the MTV exhibited a much more pronounced increase of 182%.

Conclusions

Our findings suggest that longitudinal volumetric assessment using serial FET PET is a critical marker for detecting the transition to glioblastoma progression. In clinical routine, the addition of information on MTV changes to the frequently used TBR may improve diagnostic certainty in identifying glioblastoma progression.



Abstract Number: 15

Abstract Title: Interim FDG-PET in primary central nervous system lymphoma

Authors:

Laura Rozenblum¹, Barbara Sicsic¹, Caroline Houillier², Khê Hoang-Xuan², Aurélie Kas¹

¹Nuclear Medicine Department, Pitié-Salpêtrière Hospital, Paris, France, ²Neuro-Oncology Department, Pitié-Salpêtrière Hospital, Paris, France

Background

Response assessment in primary central nervous system lymphoma (PCNSL) currently relies on International PCNSL Collaborative Group (IPCG) criteria, although MRI has shown limits to act as a surrogate marker of survival. Metabolic assessment using interim FDG-PET may provide earlier and more robust prognostic information. This study evaluated the prognostic value of interim brain FDG-PET using quantitative metrics and a dedicated interim response score.

Methods

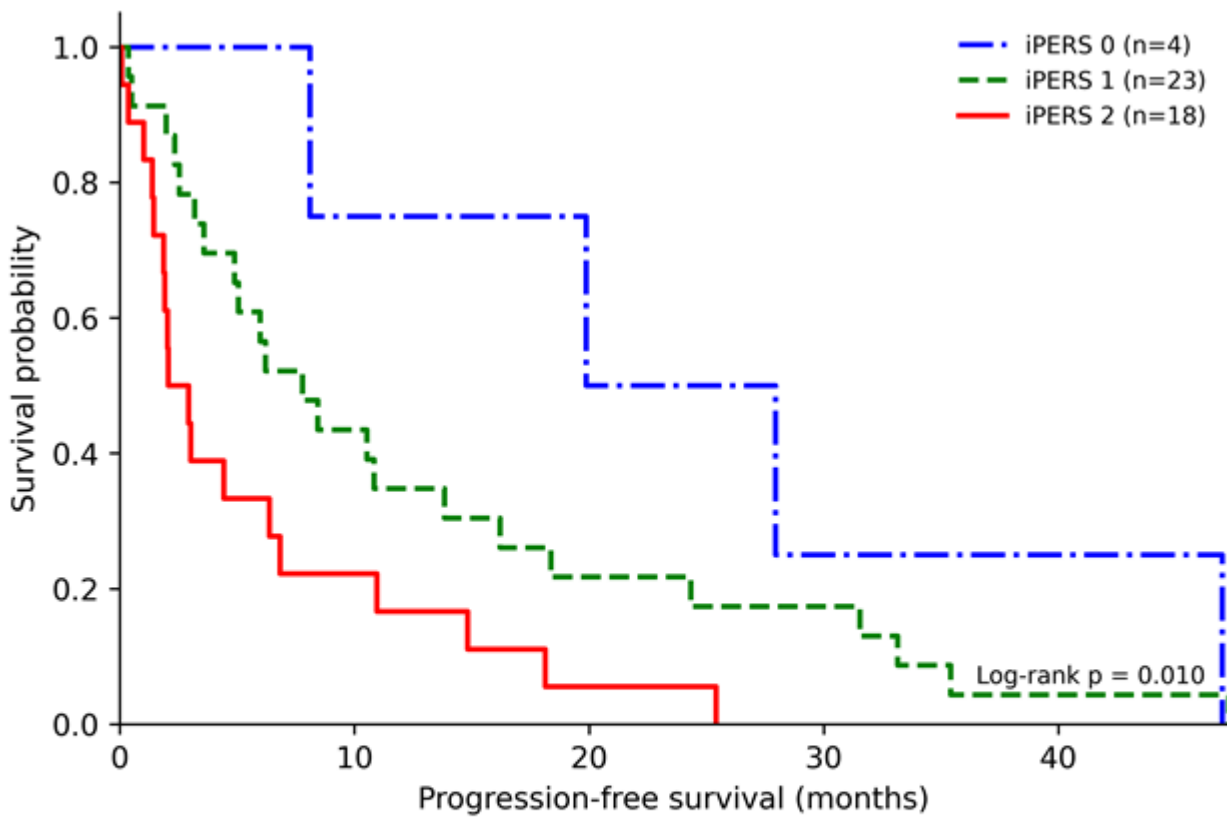
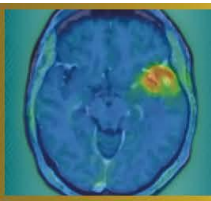
In this retrospective study, 113 immunocompetent patients with PCNSL treated with high-dose methotrexate-based chemotherapy were included. FDG-PET was performed at baseline and during interim assessment. Metabolic response was evaluated using the highest tumor-to-normal uptake ratio measured in a mirror area (hTNR_max). In addition, we developed the Interim PCNSL PET Response Score (iPERS), a three-level response score based on residual tumor uptake relative to physiological uptake in normal white matter (WM) in the centrum semiovale and gray matter (GM) in the unaffected superior frontal gyrus. Progression-free survival (PFS) and overall survival (OS) were analyzed using Kaplan–Meier estimates and Cox proportional hazards models.

Results

Elevated interim hTNR_max was independently associated with poorer PFS (hazard ratio [HR]: 4.32; 95% CI: 2.23–8.85; $P < 0.0001$) and OS (HR: 1.80; 95% CI: 1.24–2.53; $P = 0.003$) in multivariate analysis. The iPERS stratified patients into three distinct metabolic response groups with significantly different PFS outcomes: iPERS 0 (uptake \leq WM; median PFS: 23.9 months), iPERS 1 (uptake between WM and GM; median PFS: 7.8 months), and iPERS 2 (uptake $>$ GM; median PFS: 2.5 months). In contrast, interim MRI-based response categories (complete vs. partial response) did not significantly discriminate PFS.



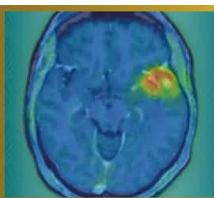
Conclusion

Interim FDG-PET provides clinically relevant prognostic stratification in PCNSL. Quantitative hTNR_max and the iPERS enable early identification of high-risk patients and may serve as candidate tools for response-adapted therapeutic strategies in future clinical trials.



Number at risk

Time (months)	0	6	12	18	24	30	35	41	47
iPERS 0	4	4	3	3	2	1	1	1	0
iPERS 1	23	14	8	6	5	4	2	1	1
iPERS 2	18	6	3	2	1	0	0	0	0



Abstract Number: 16

Abstract Title: Identification of prognostically relevant residual tumor burden in glioblastoma after surgery: A comparative analysis of MR-based RANO resect classes vs. [¹⁸F]FET PET

Authors:

Jens Blobner¹, Katharina J. Mueller², Michael Muether³, Wolfgang Roll⁴, Jonas Reis⁷, Maximilian J. Mair^{5,6}, Niklas Thon^{1,8}, Stephan Schoenecker⁹, Patrick N. Harter¹⁰, Louisa von Baumgarten^{1,2}, Florian Ringel¹, Joerg-Christian Tonn¹, Philipp Karschnia¹¹, Nathalie L. Albert⁶

¹Department of Neurosurgery, LMU University Hospital Munich, Munich, Germany, ²Department of Neurology, LMU University Hospital, Munich, Germany, ³Department of Neurosurgery, University Hospital Münster, Münster, Germany, ⁴Department of Nuclear Medicine, University Hospital Münster, Münster, Germany, ⁵Division of Oncology, Department of Medicine I, Medical University of Vienna, Vienna, Austria, ⁶Department of Nuclear Medicine, LMU University, Munich, Germany, ⁷Institute for Neuroradiology, LMU University Hospital, Munich, Germany, ⁸Department of Neurosurgery, Knappschaft University Hospital Bochum, Bochum, Germany, ⁹Department of Radiation Oncology, LMU University Hospital, Munich, Germany, ¹⁰Center for Neuropathology and Prion Research, Medical Faculty, Ludwig-Maximilians-University Munich, Munich, Germany, ¹¹Department of Neurosurgery, FAU University Hospital of the Friedrich-Alexander-University, Erlangen, Germany

Background

Accurate assessment of postoperative tumor burden is essential in glioblastoma. The RANO resect classification offers a stratification system based upon residual tumor volume determined by post-operative MRI. [¹⁸F]FET PET can detect metabolically active residual tumor invisible on MRI. The additional prognostic implications of postoperative PET to MRI remain ill-defined.

Methods

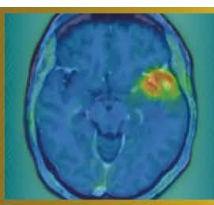
In this retrospective bicentric study, 140 patients with glioblastoma with evaluable postoperative MRI and [¹⁸F]FET PET were analyzed. Residual tumor volumes were delineated on postoperative MRI, and patients were classified according to the MRI-based RANO resect system. PET-derived residual tumor volumes were defined according to PET RANO 1.0 criteria. Spatial concordance was quantified using Dice coefficients. Prognostic associations were assessed with Cox regression. Incremental prognostic value of PET was examined using a two-stage approach with an imaging-only model (T1CE vs. T1CE+PET volume) and a fully adjusted model including clinical parameters.

Results

Postoperative PET-defined tumor volumes were substantially larger than MRI-defined volumes and showed minimal spatial overlap with a heterogeneous distribution across all RANO classes. PET-, contrast-enhanced T1 and T2/FLAIR-based tumor volumes were each independently associated with OS. The hazard of death increased continuously with increasing PET-derived residual tumor burden. In multivariable Cox regression, PET-positive residual tumor volume remained significantly associated with OS (adjusted HR 1.021 per cm³, 95% CI 1.008–1.033; **p = 0.0024). In the imaging-only model, the addition of PET increased the time-dependent area-under-the-curve (AUC(t)) across all evaluated time points between 6 and 24 months (ΔAUC 0.03–0.07) and improved Harrell's C (ΔC ≈ 0.03). In the fully adjusted model, PET provided significant non-redundant prognostic information (likelihood ratio test, *p = 0.0049).

Conclusion

Postoperative [¹⁸F]FET PET visualized metabolically active residual tumor not reliably identified by MRI and provides additional prognostic value in glioblastoma patients. Integrating PET into postoperative assessment may refine risk stratification beyond current MRI-based frameworks.



Abstract Number: 17

Abstract Title: Impact of FET PET on Proton Radiotherapy Target Delineation

Authors:

Daniil Susin¹, Elena Gromova¹, Marina Linnik¹

¹LDC MIBS, Saint-Petersburg, Russian Federation

Background

MRI-based proton radiotherapy planning may underestimate the extent of metabolically active tumour tissue in primary brain tumours. FET-PET provides complementary biological information and is increasingly used in clinical practice, yet its real-world impact on radiotherapy target delineation remains insufficiently quantified.

Methods

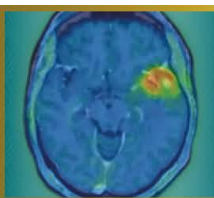
We retrospectively analysed patients with primary brain tumours (predominantly gliomas) who underwent FET-PET prior to proton radiotherapy planning at our centre. MRI-based gross tumour volumes (GTVs) were compared with FET-based metabolic tumour volumes (MTVs). Changes in target volume size and spatial configuration were assessed, and the clinical impact on proton radiotherapy planning was categorised in interdisciplinary consensus.

Results

In 25 patients, incorporation of FET-PET resulted in clinically relevant target volume modification in 36% of cases, predominantly through expansion of treatment volumes and inclusion of infiltrative tumour margins. In 12% of patients, FET-PET revealed spatially distinct intratumoral hotspots not apparent on MRI, supporting additional refinement of target delineation.

Conclusion

FET-PET frequently impacts target delineation for proton radiotherapy in routine care of patients with primary brain tumours, supporting its integration into proton radiotherapy planning workflows.



Abstract Number: 18

Abstract Title: Benefit of [177Lu]Lu-HA-DOTATATE in bone metastases in relapsed medulloblastoma, a case report

Authors:

Sabine L.A. Plasschaert¹, Leonor Teles¹, Dr. Nelleke Tolboom^{1,2}, Arthur J.A.T. Braat^{1,2}

¹Princess Máxima Center for Pediatric Oncology, Utrecht, Netherlands, ²University Medical Center Utrecht, Utrecht, Netherlands

Background

Relapsed medulloblastoma with extensive skeletal metastases is rare and carries a dismal prognosis, with limited therapeutic options. Expression of somatostatin receptor subtype 2 (SSTR2) enables molecular imaging and targeted radionuclide therapy.

Methods

We report the case of a 14-year old boy with relapsed medulloblastoma with extensive bone metastases. Initially diagnosed with a medulloblastoma, group 3, at age 8 years old, without any evidence of leptomeningeal metastases. He was treated according to standard risk medulloblastoma protocol including craniospinal irradiation and maintenance chemotherapy. A local relapse occurred twice, which was treated with local re-irradiation, the first time combined with bevacizumab, irinotecan and temozolomide. Subsequently, a regular MRI was performed, while he had diffuse pain in his back and neck. The MRI showed extensive bone metastases in the spine, legs, arms, ribs and skull, without any evidence of CNS recurrence. A biopsy of the 4th lumbar vertebrae confirmed relapse medulloblastoma, with clear SSTR2A positivity on the tumor cells at immunohistochemistry.

Results

A [68Ga]Ga-DOTATOC PET/CT was performed with very extensive SSTR2-positive skeletal lesions in all his bones. Whilst waiting for initiation of [177Lu]Lu-HA-DOTATATE therapy initiation, he rapidly developed a hypercalcemia and was mildly dehydrated with calciuria, considered to be a paraneoplastic syndrome, treated with pain killers and hyperhydration. He started [177Lu]Lu-HA-DOTATATE therapy, two cycles of 7.4 GBq with an interval of 4 weeks. Following his first [177Lu]Lu-HA-DOTATATE treatment, his hypercalcemia resolved in 1-2 weeks. At the same time, pain complaints subsided and his lab results normalized. After 2 cycles of [177Lu]Lu-HA-DOTATATE, he had a very good clinical response and the [68Ga]Ga-DOTATOC PET/CT showed a remarkable radiological response, with hardly any tumor activity visible. (Figure 1 (A) before start and (B) 4 weeks after [177Lu]Lu-HA-DOTATATE therapy).

Conclusion

This case shows the potential benefit from [177Lu]Lu-HA-DOTATATE therapy in bone metastases in relapsed medulloblastoma.

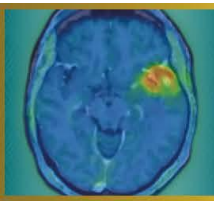
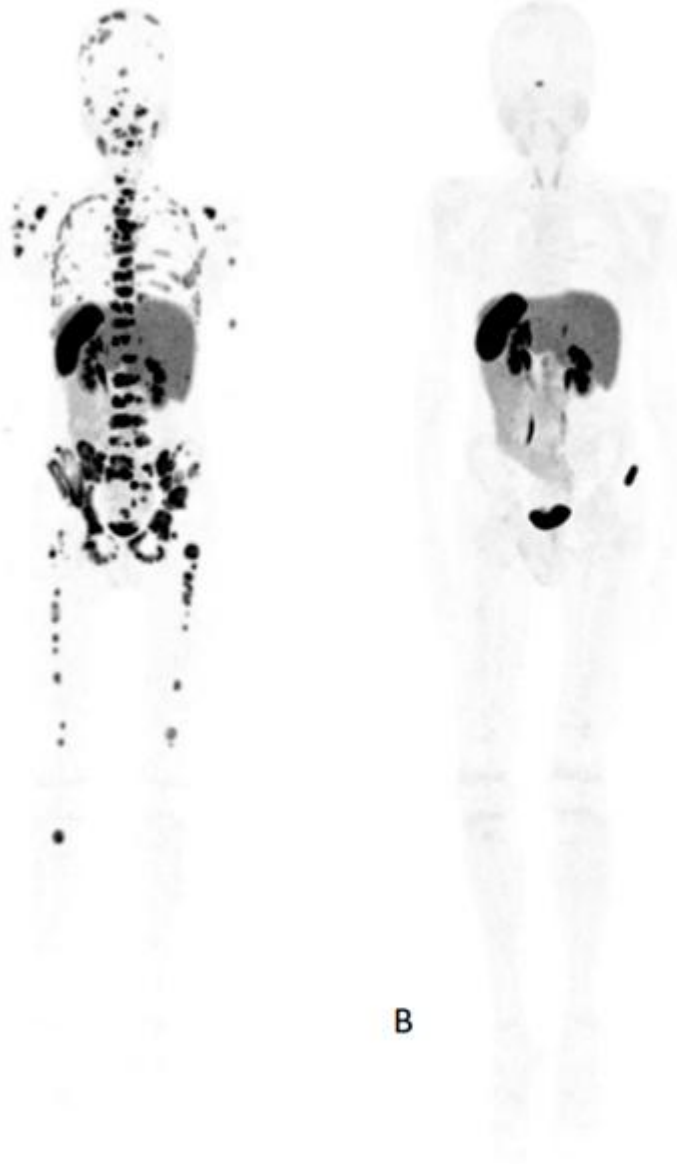
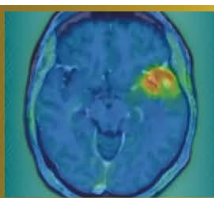


Figure 1 [68Ga]Ga-DOTATOC PET/CT scan (A) before start and (B) 4 weeks after [177Lu]Lu-HA-DOTATATE therapy)





Abstract Number: 19

Abstract Title: Subventricular zone involvement and metabolic phenotype: a combined MRI and ^{18}F -FET PET/CT biomarker for glioma prognosis

Authors:

Nina Vikhrova¹, Diana Kalaeva¹, Ivan Chekhonin¹, Galina Pavlova¹, Igor Pronin¹

¹N.N. Burdenko National Medical Research Center of Neurosurgery, Moscow, Russian Federation

Background

The subventricular zone (SVZ) is the largest neural stem cell adult brain reservoir and is considered a potential reservoir for glioma stem cells. While MRI-defined SVZ-contact is a known glioma negative prognostic factor, contrast-enhanced (CE) MRI lacks sensitivity for tumor infiltration. ^{18}F -FET PET/CT can detect metabolically active tumor cells. This study evaluated the combined prognostic value of anatomical SVZ involvement on MRI and metabolic activity on PET/CT

Methods

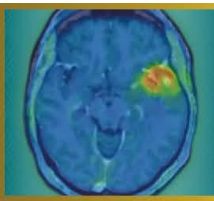
66 glioma patients (51 glioblastoma, 7 oligodendroglioma, 8 astrocytoma) were underwent 3.0T MRI and static ^{18}F -FET PET/CT. Tumors were stratified into two SVZ-groups on MRI: contact SVZ(+) and no contact SVZ(-). Metabolic tumor activity (TBR) were analyzed in each group. Progression-free survival(PFS) was assessed in SVZ(+) group. Non-parametric statistical tests and Kaplan-Meier method for assessing PFS were used.

Results

SVZ(+) was present in 90% patients. Conversely, SVZ(-) was identified in all histological subtypes, with the highest frequency observed in astrocytomas (n=5), followed by single cases in both glioblastoma and oligodendroglioma. All MRI CE+ lesions (n=56) were SVZ(+), while among CE- (n=10) this sign was observed in 50% of cases (p<0.001). TBR was significantly (p<0.001) higher in the SVZ(+) group compared to SVZ(-), cut off TBR=2,32 (SE95%, SP100%, AUC=0.98). Within SVZ(+) cohort, a high metabolic subgroup (defined by TBR>3.47) exhibited the worst prognosis, with median PFS 7.6months (95%CI: 6–12.2) compared to 19.4months (95%CI: 9–NA) in the low metabolic subgroup (p=0.049).

Conclusions

The results confirm that SVZ contact is a common marker of an aggressive glioma phenotype, characterized by contrast enhancement and high metabolic activity. The integration of MRI-based SVZ status and PET/CT-derived TBR enables effective risk stratification. Specifically, TBR>3.47 within SVZ(+) tumors is an independent predictor of short PFS. The assessment of SVZ involvement on MRI combined with amino acid PET/CT for metabolic evaluation provides a crucial integrated biomarker for prognostic stratification and treatment guidance.



Abstract Number: 20

Abstract Title: Validation of an optimized 18F-FET PET/CT quantification protocol : single-slice background SUV and tumor SUVpeak enhance reproducibility and prognostic accuracy in glioma management

Authors:

Nina Vikhrova¹, Diana Kalaeva¹, Anastasia Kopaneva¹, Igor Pronin¹

¹N.N. Burdenko National Medical Research Center of Neurosurgery, Moscow, Russian Federation

Background

Current guidelines endorse TBR based on SUVmax/mean and 6-slice SUVnorm but skip SUVpeak. Recent evidence highlights TBRpeak prognostic superiority over TBRmax. This study aimed to validate optimized protocol by defining simplest SUVnorm calculation and comparing diagnostic/prognostic value of TBRpeak versus conventional TBRmax.

Methods

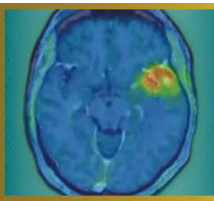
102 primary supratentorial glioma patients were underwent static 18F-FET PET/CT. SUVnorm was measured 'banana-shaped' VOI/ROI (mean values) in four ways: 1) 6-sliceVOI - reference; 2) 2-slice bottom VOI at the level of lateral ventricles; 3) 2-slice top VOI at the centrum semiovale level; 4) single-slice ROI in the middle. Tumor activity was quantified using round- shaped VOI SUVmax and SUVpeak, enabling calculation of corresponding TBRmax and TBRpeak. Analytical methods included repeated-measures ANOVA, Bland-Altman analysis for agreement assessment, ROC analysis for diagnostic performance, Cox proportional hazards modeling for survival endpoints.

Results

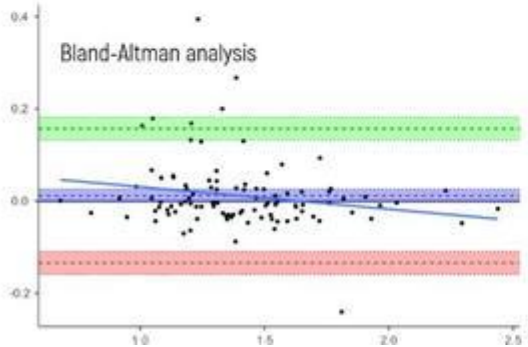
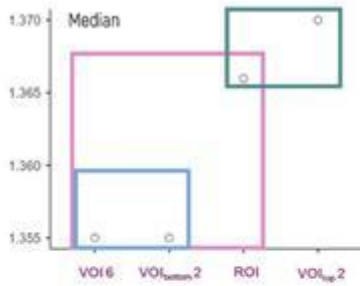
All SUVnorm calculations yielded highly similar median values(1.35-1.37). The simplest single-slice ROI was statistically comparable to the reference 6-slice VOI (p=0.19). Bland-Altman analysis confirmed their interchangeability. As hypothesized, SUVpeak was systematically and significantly lower than SUVmax (mean bias: 0.53 SUV, p<0.001), resulting in a concomitant mean reduction of 0.38 units in TBRpeak compared to TBRmax. However, for IDH status prediction, TBRpeak (AUC=0.749) demonstrated comparable diagnostic accuracy to TBRmax (AUC=0.738), the optimal cut-off for TBRpeak(2,20) was 15% lower than for TBRmax(2,53). In survival analysis, each unit increase in TBRpeak was associated with a higher risk of progression (HR 45% vs. 36% for TBRmax) and death (HR 47% vs. 35%).

Conclusions

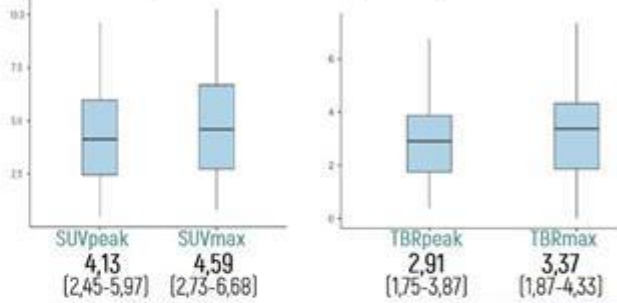
Our results confirms single-slice ROI provides valid, workflow-efficient background measurement. TBRpeak demonstrates prognostic superiority, serving as more robust biomarker of global tumor aggressiveness. TBRpeak prognostic superiority aligns with recent literature, confirming it as more robust global tumor aggressiveness biomarker, less susceptible to noise than TBRmax. Protocol maintains diagnostic performance, enhances practical feasibility, provides prognostically superior information compared to guideline-conventional TBRmax



Background SUVmean (SUVnorm)




Tumor SUVpeak vs SUVmax / TBRpeak vs TBRmax

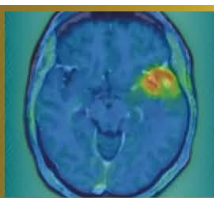


Progression Free Survival (PSF)

Hazard Ratio **TBRpeak** Cut-off 2,15
1,45 (1,09-1,93) p=0,01



Hazard Ratio **TBRmax** Cut-off 2,36
1,36 (1,07-1,73) p=0,012



Abstract Number: 21

Abstract Title: Impact of postoperative somatostatin-receptor-targeted PET imaging on residual tumor detection and surgical assessment of re-resection in meningioma

Authors:

Nina C. Teske¹, Nico Teske², Thomas Schabhüttl³, Moritz Ueberschaer⁴, Sebastian N Marschner^{5,6}, Christian Schichor¹, Florian Ringel¹, Nathalie L. Albert^{3,6}, Tobias Greve^{1,7}

¹Department Of Neurosurgery, LMU University Hospital, LMU Munich, Munich, Germany, ²Department of Neurosurgery, FAU University Hospital of the Friedrich-Alexander-University, Erlangen, Germany, ³Department of Nuclear Medicine, LMU Hospital, LMU Munich, Munich, Germany, ⁴Department of Neurosurgery, University Hospital Salzburg, Paracelsus Medical University, Salzburg, Austria, Salzburg, Austria, ⁵Department of Radiation Oncology, LMU University Hospital, LMU Munich, , Munich, Germany, ⁶German Cancer Consortium, Partner Site Munich, Munich, Germany, ⁷Bavarian Cancer Research Center, Partner Site Munich, Munich, Germany

Objective

Residual tumor after meningioma surgery increases recurrence risk, yet postoperative assessment relies mainly on MRI with limited sensitivity. Somatostatin receptor (SSTR)–targeted PET may improve residual tumor detection, but its impact on postoperative surgical decision-making remains unclear. We evaluated whether postoperative SSTR-PET detects residual tumor beyond MRI and identifies potentially resectable disease, and exploratorily assessed progression in conservatively managed patients with retrospectively resectable residual tumor.

Methods

We retrospectively analyzed patients with intracranial meningioma who underwent surgical resection followed by postoperative MRI and SSTR-targeted PET. MRI was reviewed by a board-certified neurosurgeon to assess residual tumor, technical resectability, and potential clinical benefit of re-resection, including possible Simpson grade reduction. Assessments were repeated after inclusion of SSTR-PET.

Results

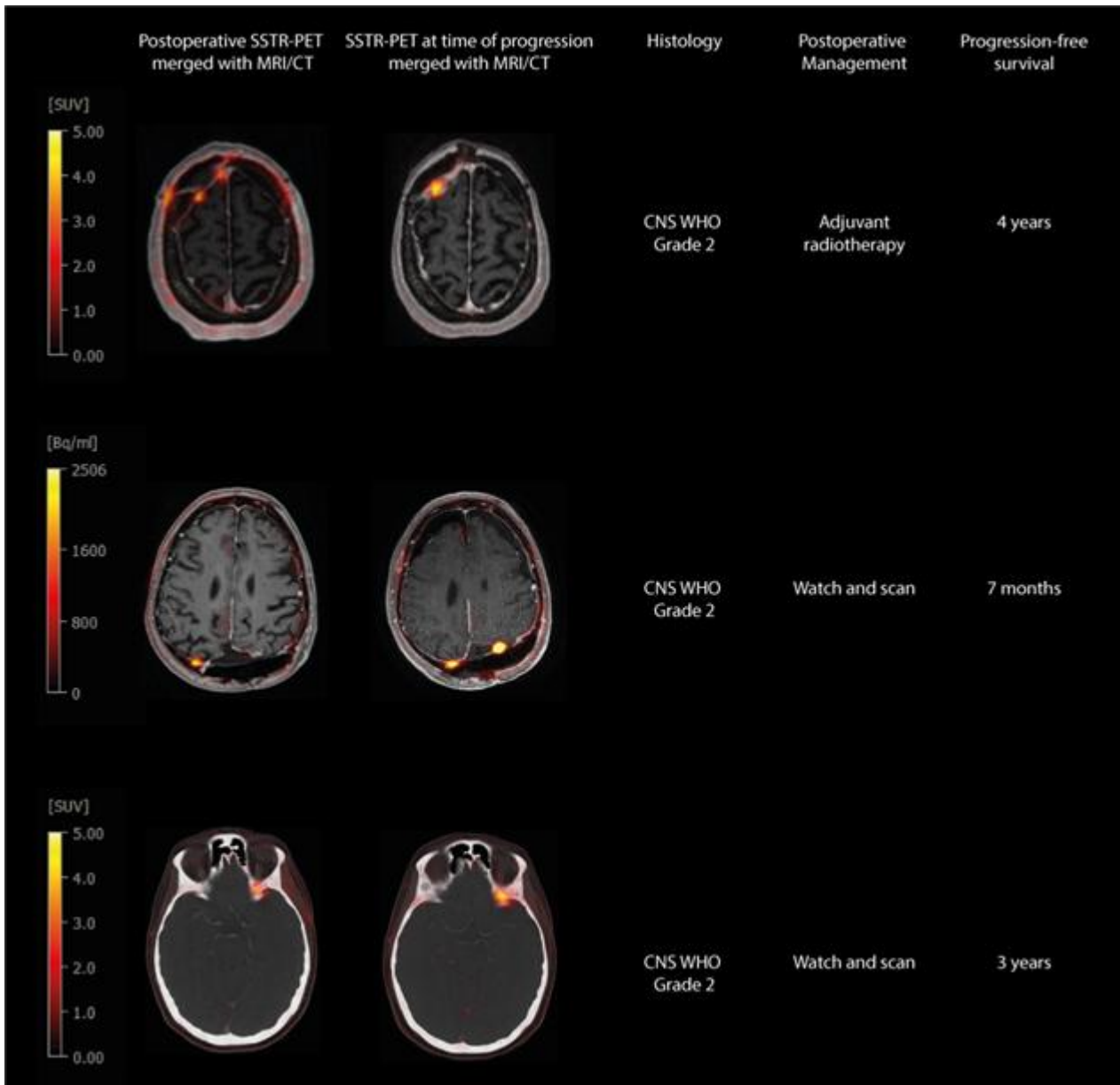
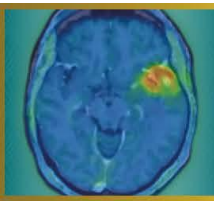
Forty patients were included (27 skull base, 4 convexity, 9 parafalcine meningiomas). Postoperative MRI detected residual tumor in 24/40 patients (60%), whereas SSTR-PET identified residual disease in 32/40 patients (80%), resulting in a significantly higher detection rate ($p = 0.0078$).

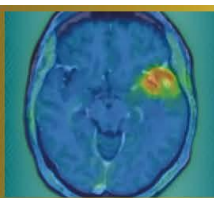
Based on MRI, complete and partial re-resection was considered feasible in 3/40 (7.5%) and 16/40 patients (40%), respectively; after inclusion of SSTR-PET, feasibility increased to 7/40 (17.5%) and 19/40 patients (47.5%). A clinically meaningful, potentially Simpson grade–reducing re-resection was identified in 4/40 patients (10%) based on MRI alone and in 8/40 patients (20%) after inclusion of SSTR-PET ($p = 0.219$), including 4 patients classified as completely resected on MRI alone.

During follow-up 12/40 patients (30%) experienced disease progression. Of those, 10/12 patients (83%) had detected residual tumor on postoperative SSTR-PET, including 3 patients classified as completely resected on MRI but retrospectively considered amenable to clinically meaningful re-resection based on PET (Fig. 1).

Conclusion

Postoperative SSTR-PET improves residual tumor detection compared with MRI and identifies additional potentially resectable disease. PET-guided assessment provides clinically relevant information for postoperative decision-making and may support re-resection in selected patients.





Abstract Number: 22

Abstract Title: [18F]FET PET Hypermetabolism in Diffuse Lower Grade Glioma Correlates With Glioma-Related Epilepsy

Authors:

Zeynep Özdemir¹, Wolfgang Roll², Prof. Walter Stummer¹, Prof. Stjepana Kovac³, PD Dr. med. Michael Mütter¹

¹Department of Neurosurgery, University Hospital Münster, Münster, Germany, ²Department of Nuclear Medicine, University Hospital Münster, Münster, Germany, ³Department of Neurology, University Hospital Münster, , Germany

Objective

Diffuse lower-grade gliomas (DLGG) often present with epileptic seizures, which can severely impact the quality of life. [18F]FET PET is routinely used to assess glioma metabolism, but differences in metabolic activity between DLGG patients with and without glioma-related epilepsy (GRE) have not yet been assessed systematically. The objective of this retrospective study is to explore differences in metabolic activity in DLGG of patients with and without GRE.

Methods

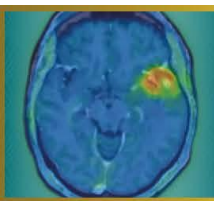
This single-center retrospective study included 121 patients with supratentorial IDH-mutant WHO grades 2 and 3 tumors with preoperative [18F]FET PET between 2015 and 2025. DLGG were characterized according to the PET-RANO 1.0 criteria. Only the occurrence of seizures prior to the initial surgery was defined as GRE in this study. In addition to conventional descriptive statistics, a multivariable logistic regression analysis was conducted to evaluate the association between PET hypermetabolism and GRE, as well as other clinical variables.

Results

Seventy-eight patients (64%) demonstrated PET measurable disease; 57 (73%) of these presented with epileptic seizures compared to 17 (40.0%) in the non-hypermetabolic group ($p = 0.0004$). In the hypermetabolic group, those with GRE exhibited significantly higher median TBRmax (3.020 [IQR 2.35 – 4.00]) and TBRmean (2.2 [IQR 1.8 – 2.5]) values than those without GRE (TBRmax 2.4 [IQR 2.00 – 3.175], TBRmean 1.9 [IQR 1.7 – 2.2]). PET-positive tumor volume did not significantly differ among groups. In multivariable analyses, PET hypermetabolism was independently associated with higher odds of preoperative seizure presentation (OR 3.46; 95% CI 1.50 – 8.15).

Conclusions

This exploratory study demonstrates increased metabolic activity on [18F]FET PET in DLGG patients with GRE. Further research on the expression of amino acid transporters and glutamatergic mechanisms could clarify the molecular relationship between tumor metabolism and epileptogenesis.



Abstract Number: 23

Abstract Title: 68Ga/177Lu-PSMA theranostics in recurrent high-grade glioma

Authors:

Anna Maria Karlberg^{1,2}, Benedikte Emilie Vindstad^{1,3}, Hanne Tøndel¹, Håkon Johansen^{1,2}, Thomas Morten Keil¹, Erik Magnus Berntsen^{1,2}, Ole Solheim^{1,2}, Silje Kjærnes Øen¹, Tora Skeidsvoll Solheim^{1,2}, Live Eikenes^{1,2}

¹St. Olavs Hospital, Trondheim University Hospital, Trondheim, Norway, ²Norwegian University of Science and Technology, Trondheim, Norway, ³LMU University Hospital, LMU Munich, Munich, Germany

Background

This study evaluated 68Ga/177Lu-PSMA theranostics as a treatment alternative for patients with recurrent high-grade glioma, aiming to improve diagnostic and therapeutic strategies and potentially enhance overall survival and quality of life.

Material and Methods

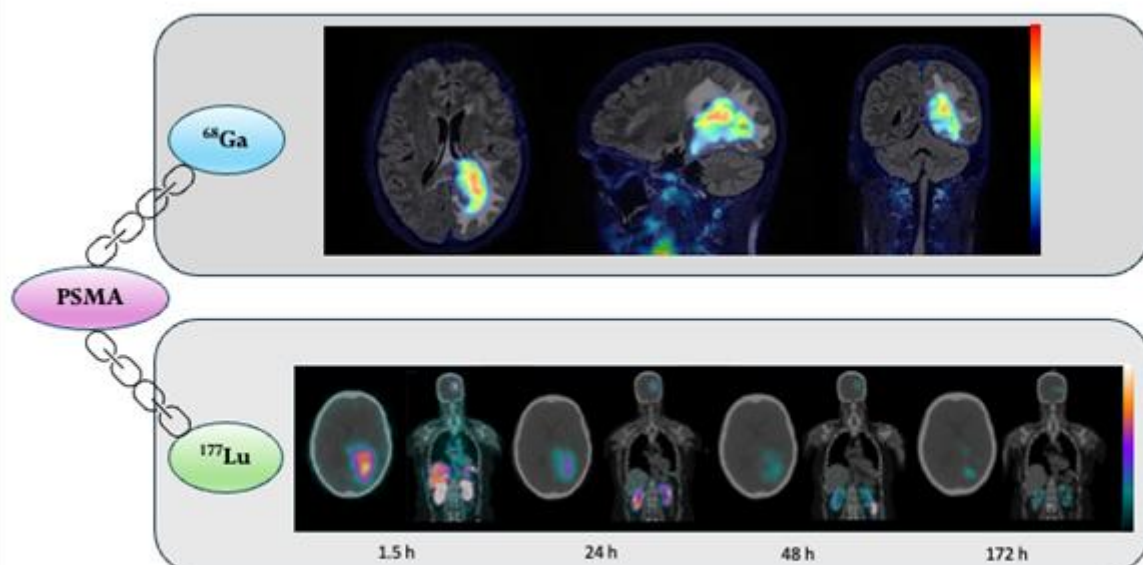
All patients received standard treatment with surgery, radiotherapy and chemotherapy prior to inclusion, and were left with no other treatment options at recurrence/progression. Eligible patients were selected for treatment based on a positive 68Ga-PSMA-PET examination. 177Lu-PSMA (7.4 GBq) was administered with 6-8 weeks intervals and continued as long as the patient tolerated the treatment well. The safety, tolerability and efficacy of 177Lu-PSMA were assessed during study visits in each treatment cycle using PET/MR, SPECT/CT, neurological tests, quality of life questionnaires and blood tests.

Results

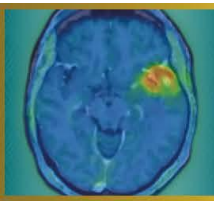
Ten patients were enrolled (grade 4 glioblastoma: n=6; grade 4 astrocytoma: n=1; grade 3 astrocytoma: n=3). 68Ga-PSMA-PET prior to treatment demonstrated tumor uptake in nine patients (median SUVmax: 6.4, range: 2.0-10.3), while uptake in normal brain was low (median SUVmean: 0.09, range: 0.02-0.11). Six patients met the eligibility criteria and have completed treatment. A total of 20 treatments have been administered (1-7 per patient). Median absorbed doses per treatment ranged from 2.6 Gy (range: 0.8-9.3 Gy) for tumors, 2.9 Gy (range: 1.2-4.4 Gy) for kidneys and 2.3 Gy (range: 0.5-3.4 Gy) for parotid glands. No grade 3 or grade 4 toxicities were observed. The most commonly patient reported symptoms were fatigue, transient xerostomia, and nausea. Radiological evaluation (MRI, RANO) demonstrated stable disease in half of the patients during the treatment cycles and progression in the other half. Figure 1 shows PET/MR and SPECT/CT images from one of the patients.

Conclusion

Despite low tumor doses, the radiological stability of disease observed in half of the patients is promising. However, higher tumor doses may be required to achieve improved therapeutic efficacy.



A patient with a grade 4 glioblastoma treated with the radiotracer ¹⁷⁷Lu-PSMA at St. Olavs hospital (ClinicalTrials.gov.ID: NCT05644080). Top row: PET/MR images of the tumor uptake of ⁶⁸Ga-PSMA for diagnosis (SUV scale: 0-9). Bottom row: SPECT/CT images over the uptake of the therapeutic radiotracer ¹⁷⁷Lu-PSMA. Images at 1.5 h, 24 h, 48 h and 172 h post treatment show tumor accumulation of ¹⁷⁷Lu-PSMA up to 7 days post therapy. (SPECT scale; 0-200 counts for 1.5 h, 24 h and 48 h, and 0-50 counts for 172 h).



Abstract Number: 24

Abstract Title: IPAX BRiGHT: Pivotal study of iodofalan (^{131}I) with or without lomustine vs lomustine alone for the treatment of patients with radiographically confirmed recurrent glioblastoma at first recurrence

Authors:

Arthur J A T Braat^{1,2}, Dr. Nelleke Tolboom¹, Andrew Scott³, Hui Gan³, **Daniela Divlianska**⁴, David Cade⁴, John de Groot⁵

¹University Medical Centre Utrecht ²Netherlands Cancer Institute ³Austin Health ⁴Telix Pharmaceuticals ⁵University of California San Francisco

Background

With limited treatment options for glioblastoma, theranostic radiopharmaceuticals may address this unmet need. Glioblastomas overexpress LAT1, the target for 4-L- ^{131}I -iodophenylalanine (iodofalan [^{131}I]). In IPAX-1 (Phase 1 study), iodofalan (^{131}I) plus external beam radiation therapy in patients with recurrent glioblastoma demonstrated acceptable tolerability and specific tumor targeting. IPAX BRiGHT (NCT07100730) will evaluate iodofalan (^{131}I) ± lomustine versus lomustine alone in patients with recurrent glioblastoma at first recurrence.

Materials and Methods

This multicenter, open-label study will include two parts: 1) safety and dosimetry lead-in, and 2) randomized treatment expansion. Eligibility criteria include age ≥18-years; previously confirmed glioblastoma (IDH-wildtype) diagnosis; and radiographic evidence of first recurrence or progressive glioblastoma after first-line treatment. Patients will be followed by conventional MRI and [^{18}F]FET PET every 8 weeks. Safety, including clinical laboratory assessments and adverse events, will be continuously monitored throughout study. Part 1 will utilize a Bayesian Optimal Interval (BOIN) design to determine iodofalan (^{131}I) maximum tolerated dose with lomustine, with a deescalation design (Figure). Arm A and B will receive three 42-day cycles of lomustine (Arm A: 90mg/m²; Arm B: 70mg/m²) plus iodofalan (^{131}I). If both Arm A and B close due to reaching elimination boundary for lowest dose level, Arm C will open. Arm C will receive three 28-day cycles of iodofalan (^{131}I) monotherapy. Iodofalan (^{131}I) will be administered in all arms starting at 12 GBq total activity in 3x4 GBq fractions. Part 1 co-primary endpoints are safety and tolerability. In Part 2, patients will be randomized 1:1 to receive iodofalan (^{131}I) ± lomustine at dose confirmed in Part 1 or lomustine 110 mg/m² alone. Part 2 primary endpoint is OS.

Results

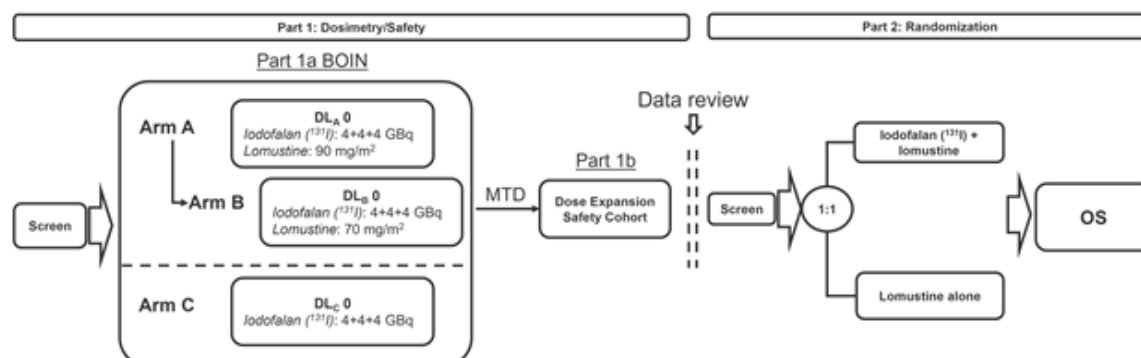
IPAX-BRiGHT is ongoing; no results are available.


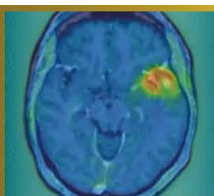
Conclusion

Iodofalan (^{131}I) ± lomustine is expected to improve clinical outcomes in patients with recurrent glioblastoma.

This study is sponsored by Telix Pharmaceuticals.

Figure. Study design.





Abstract Number: 25

Abstract Title: IPAX-2: Phase 1 safety and dose finding study of iodofalan (^{131}I) plus standard of care in patients with newly diagnosed glioblastoma

Authors:

Josef Pichler¹, Nimit Singhal², Hui Gan³, Arthur J A T Braat⁴, Wade Pullin⁵, Daniela Divlianksa⁶, David Cade⁶

¹Department of Internal Medicine and Neuro-oncology, Kepler University Hospital, Johannes Kepler University

²Royal Adelaide ³Austin Health ⁴University Medical Centre Utrecht ⁵Gold Coast University Hospital ⁶Telix Pharmaceuticals

Background

Glioblastoma overexpresses LAT1, the target of 4-L- ^{131}I iodo-phenylalanine (iodofalan [^{131}I]). In the Phase 1 IPAX-1 study, ^{131}I -iodofalan plus external beam radiation therapy in patients with recurrent glioblastoma demonstrated acceptable tolerability and specific tumor targeting. IPAX-2 (NCT05450744) will evaluate iodofalan (^{131}I) plus standard of care (SoC) in patients with newly diagnosed glioblastoma.

Materials and Methods

This Phase 1, multicentre, open-label, single-arm, parallel-group, dose-finding study will evaluate safety of ascending radioactive dose levels of iodofalan (^{131}I) plus SoC in patients with newly diagnosed glioblastoma. Eligibility criteria include age ≥ 18 years; histologically-confirmed intracranial glioblastoma following surgical resection; no prior systemic therapy or radiation for glioblastoma; a Karnofsky Performance Status ≥ 70 ; plan to begin chemoradiation 3-6 weeks after surgical resection with Stupp regimen; adequate organ function; and adequate tissue samples previously archived.

Four cohorts (n=3/cohort) will encompass 3+3 dose escalation, beginning with iodofalan (^{131}I) intravenously administered as 2 doses of 3 GBq each (dose escalation schedule: 2x3 GBq, 2x4 GBq, 2x5 GBq, 2x6 GBq). Dose 1 will be 7 days prior to chemoradiation, and dose 2 will be after last chemoradiation session. Chemoradiation will consist of 6 weeks of external beam radiation therapy (60 Gy/30 fractions) plus temozolomide 75 mg/m² daily. Following dose 2, patients will receive a 4-week treatment break before starting 6 maintenance cycles of temozolomide 150-200 mg/m² on days 1-5 every 28 days. [^{18}F]FET PET will be used for metabolic tumor response assessment and excluding pseudoprogression. The co-primary objectives are 1) determine dose-limiting toxicity, maximum tolerated dose, and recommended Phase 2 dose, and 2) determine the incidence of treatment-emergent adverse events.

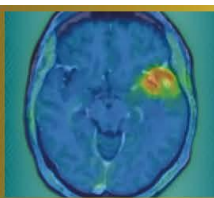
Results

IPAX-2 is ongoing; no results are available.

Conclusion

Iodofalan (^{131}I) plus SoC has potential to improve clinical outcomes in patients with newly diagnosed glioblastoma.

This study is sponsored by Telix Pharmaceuticals.



Abstract Number: 26

Abstract Title: Study protocol for PRECISE, a pilot clinical trial of transarterial radioembolisation in patients with recurrent glioblastoma

Authors:

Gaia Ninatti^{1,2}, Hamed Asadi¹, Andrew Owen¹, Lawrence Cher¹, Sweet Ping Ng¹, Mark Brooks¹, Kylie Wilkie², Arthur Braat³, Andrew M Scott^{1,2}, Hui Gan^{1,2}

¹Austin Health, Melbourne, Australia, ²Olivia Newton-John Cancer Research Institute, Melbourne, Australia, ³UMC Utrecht, Utrecht, the Netherlands

Background

Despite maximal multimodal treatment, patients with glioblastoma (GBM) inevitably experience disease recurrence, and prognosis in the recurrent setting remains poor, with limited therapeutic options and modest survival benefit. The absence of treatments that meaningfully prolong survival highlights the need for new therapeutic approaches. Transarterial radioembolization (TARE) is an established locoregional treatment modality in liver malignancies, based on selective intra-arterial delivery of high-dose internal radiation to tumour vasculature. Although experience in brain tumours is limited, early data suggest that TARE is technically feasible and well tolerated. The PRECISE study will evaluate the safety and tolerability of TARE using 90Y-labelled resin microspheres (SIR-Spheres®) in patients with recurrent GBM.

Material and Methods

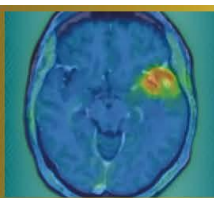
PRECISE is a prospective, single-centre pilot study planned to enrol 12 adults (≥18 years) with recurrent GBM. Key eligibility criteria include histologically confirmed IDH-wildtype GBM (WHO CNS 2021), radiological evidence of progression according to RANO criteria, and suitability for TARE. Screening assessment will include brain MRI, [18F]FET PET, and a planning angiographic procedure with intra-arterial administration of 99mTc-MAA. 99mTc-MAA SPECT will be used to assess tumour targeting, exclude relevant non-target activity, and perform voxel-based dosimetry for treatment planning. Eligible patients will undergo TARE with SIR-Spheres®. Activity will be prescribed to achieve complete tumour coverage, targeting a tumour V100 ≥90%. Treatment will consist of a single administration, with optional one-time re-treatment if appropriate. Primary endpoints are treatment-related adverse events within 30 days following TARE, graded according to CTCAEv5.0. Secondary endpoints include technical success rate, objective response rate and disease control rate according to RANO and PET RANO criteria, progression-free survival, and overall survival.

Results

Study commencement is anticipated in Q3 2026.

Conclusion

PRECISE is a pilot clinical trial evaluating the safety and tolerability of TARE using SIR-Spheres® in recurrent GBM, and will generate early clinical and dosimetric data to inform the design of future studies.



Abstract Number: 27

Abstract Title: Impact of Reconstruction Methods on Quantitative [18F]FET PET/CT Parameters in Pediatric Brain Tumor Imaging

Authors:

Tamara Antonevskaya¹, Mikhail Yadgarov¹, Yury Likar¹

¹Dmitry Rogachev National Medical Research Center Of Pediatric Hematology, Oncology And Immunology, Moscow, Russian Federation

Background

Accurate and reproducible quantification of metabolic parameters from [18F]FET PET/CT is essential in neuro-oncology. Reconstruction methods may influence measurement consistency, affecting clinical interpretation.

Material and Methods


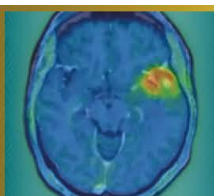
This retrospective study analyzed 15 pediatric patients with median age of 11 years (range: 1-16 years) with primary brain tumors. PET/CT datasets from one digital scanner (Discovery MI Gen 2, GE HealthCare) were processed using various reconstruction algorithms (OSEM+PSF, OSEM+PSF+TOF) and reconstruction parameters (iterations, subsets and Gaussian filter). Quantitative parameters such as SUVmax, SUVmean, tumor-to-background ratios (TBR), and volumetric measurements (MTV) were extracted and compared across reconstruction methods. Bland-Altman Method was used to assess reproducibility and agreement.

Results

The analysis revealed that the reconstruction algorithm introduces a positive bias in SUVmax and TBRmax (biases +0.387 and +1.753, respectively), indicating higher values in most cases. The use of larger window size of Gaussian filter generally decreases SUVmax, and related parameters, as well as MTV (biases of -0.853 and -0.765, respectively). Variability in number of iterations strongly impacts SUVmax, TBRmax and MTV, with biases up to +0.807, +2.133 and +1.257, respectively. Variations in the number of subsets show the most variability overall, with biases reaching +3.275 for MTV and +2.133 for SUVmax. The least impacted parameter overall was background SUVmean, showing minimal bias under different reconstruction methods. In comparison, TBRmean and SUVmean were more sensitive to parameter changes, but still exhibited no substantial variation.

Conclusions

Reconstruction methods substantially influence quantitative [18F]FET PET/CT parameters in brain tumor imaging. Standardized reconstruction protocols are vital for ensuring measurement reliability, supporting consistent interpretation in clinical and research contexts. Protocol harmonization remains critical for optimizing the utility of [18F]FET PET/CT in pediatric neuro-oncology.



Abstract Number: 28

Abstract Title: Functional connectivity decline in glioma patients is associated with metabolic tumor progression according to the PET RANO 1.0 criteria

Authors:

Manuel Kraft^{1,2}, Julia Hilgers², Jana-Marie Peplinski¹, Jan-Michael Werner¹, Garry Ceccon¹, Michael Wollring¹, Isabelle Stetter¹, Gereon R. Fink^{1,2}, Karl-Josef Langen^{2,3}, Felix M. Mottaghy³, Keith George Ciantar^{2,4}, Nadim J. Shah², Philipp Lohmann^{2,3}, Martin Kocher^{2,5}, Norbert Galldiks^{1,2}

¹Dept. of Neurology, University Hospital Cologne, Cologne, Germany, ²Inst. of Neuroscience and Medicine (INM-3, INM-4), Research Center Juelich, Juelich, Germany, ³Dept. of Nuclear Medicine, RWTH Aachen University Hospital Aachen, Aachen, Germany, ⁴Inst. for Imaging and Computer Vision, RWTH Aachen University, Aachen, Germany, ⁵Dept. of Stereotactic and Functional Neurosurgery, University Hospital Cologne, Cologne, Germany

Background

The emerging field of cancer neuroscience suggests intense structural and functional connections between gliomas and the CNS, leading to large-scale network alterations. These could be reflected in functional connectivity (FC), measured using resting-state fMRI (rs-fMRI). Functional network connectivity data obtained from single scans has been associated with tumor grade and overall survival. Using repeated scans, we examined changes in FC in patients with gliomas and their association with metabolic changes in amino acid PET using the tracer O-(2-[¹⁸F]-fluoroethyl)-L-tyrosine (FET).

Materials and methods

In a retrospective study, 45 patients with gliomas (WHO CNS 2021: glioblastoma, n=27; astrocytoma, n=8; oligodendroglioma, n=10), who underwent both rs-fMRI and FET PET before and after (mean time interval, 6 months) chemoradiation (n=27), surgery (n=9), or no treatment (n=9) were evaluated. Metabolic changes in FET PET were assessed using the PET-RANO 1.0 criteria, dividing into patients with metabolic progression (n=22, comprising Progressive Disease) and those without metabolic progression (n=23, comprising Complete Response, Partial Response, and Stable Disease). FC was assessed by examining the BOLD-activity time course correlations in rs-fMRI. Out of seven canonical resting-state networks, the individual network at risk for each patient was identified through maximum proportional tumor overlap with the network. Finally, changes in FC within the networks at risk were analyzed.

Results

Within individual networks at risk, there was a significant difference in FC changes between the two groups (p=0.024). Patients with metabolic tumor progression in FET PET showed a decrease in FC over time, whereas patients without metabolic tumor progression showed an increase in FC.

Discussion and conclusion

Our data suggest that FC declines throughout the course of metabolic tumor progression and increases following effective treatment in patients with gliomas. This highlights a possible role for rs-fMRI in predicting tumor progression and treatment response.

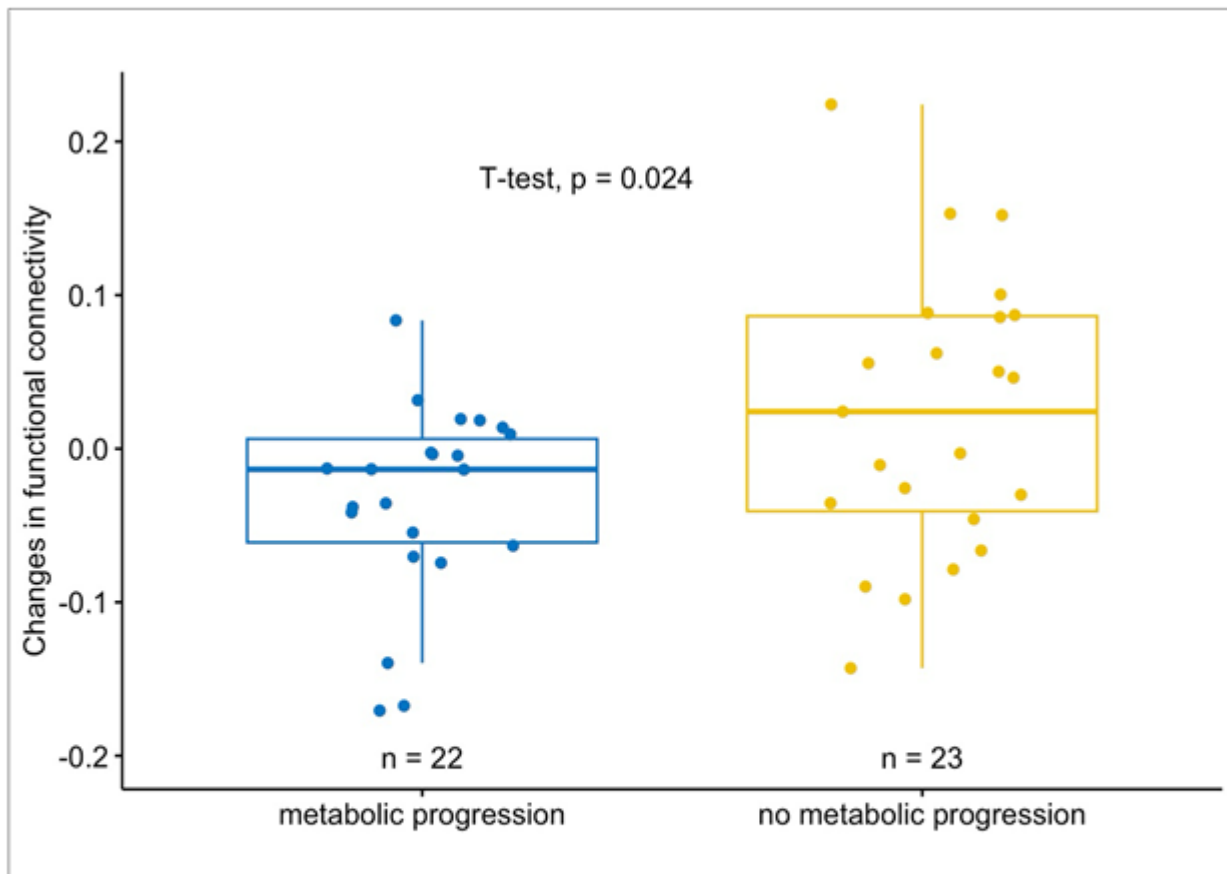
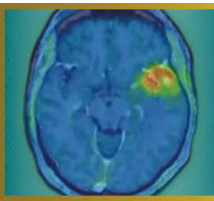
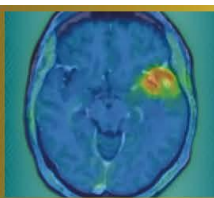


Figure 1. FC Changes Within the Network at Risk by Metabolic Changes

Boxplots depicting significant differences in changes in functional connectivity within the *network at risk* between patients with and without metabolic tumor progression in FET PET



Abstract Number: 29

Abstract Title: The NMN-BBB score as a prognostic marker in newly diagnosed glioblastoma: a single-center, retrospective study

Authors:

Roman Stürzl¹, Katharina J Müller², Jonas Reis³, Thomas Schabhüttl^{1,4}, Isabelle von Polenz¹, Lena Kaiser¹, Maximilian J Mair^{1,4}, Louisa von Baumgarten^{2,5,6,7}, Patrick Harter^{6,7,8}, Stephan Schönecker⁹, Darius Kalasauskas⁵, Florian Ringel⁵, Prof. Matthias Preusser⁴, Nathalie L Albert^{1,6,7}

¹Department of Nuclear Medicine, LMU University Hospital, LMU Munich, Munich, Germany, ²Department of Neurology, LMU University Hospital, LMU Munich, Munich, Germany, ³Institute of Neuroradiology, LMU University Hospital, LMU Munich, Munich, Deutschland, ⁴Division of Oncology, Department of Medicine I, Medical University of Vienna, Vienna, Austria, ⁵Department of Neurosurgery, LMU University Hospital, LMU Munich, Munich, Deutschland, ⁶Bavarian Cancer Research Center (BZKF), Partner Site Munich, Munich, Deutschland, ⁷German Cancer Consortium (DKTK), Partner Site Munich, Munich, Germany, Munich, Deutschland, ⁸Center for Neuropathology and Prion Research, Faculty of Medicine, LMU Munich, Munich, Deutschland, ⁹Department of Radiation Oncology, LMU University Hospital, LMU Munich, Munich, Deutschland

Background

The NMN-BBB score integrates contrast-enhanced MRI and [18F]FET PET to semi-quantitatively grade blood-brain barrier (BBB) disruption within metabolically active glioblastoma tissue and has been proposed as a pragmatic tool to facilitate patient selection for clinical trials. In this retrospective single-center study we investigated the prognostic value of the NMN-BBB score.

Methods

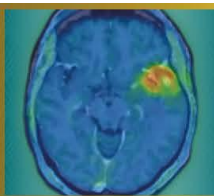
141 patients with newly diagnosed glioblastoma, IDH-wildtype were included. We analyzed progression-free survival (PFS), overall survival (OS) and time-to-next-intervention (TTNI) using Kaplan-Meier estimates, uni- and multivariate Cox regression. For exploratory purposes NMN-BBB scores X, 1 and 2 (n=56) as well as score 3-5 (n=85) were grouped.

Results

PFS differed significantly between NMN-BBB score groups. Median PFS was 19.2 months in patients with a score of X, 1 or 2 and 12.5 months in those with score 3-5 (p<0.001). A higher score was associated with shorter PFS in univariable Cox regression (p=0.005) and remained significant after multivariable adjustment (p=0.002). OS also differed significantly with a median of 45.8 months for score X-2 and 18.0 months for score 3-5 (p=0.006). These findings were persistent in both univariate (p=0.007) and multivariate models (p<0.001). TTNI was also significantly shorter in the higher-score group. Median TTNI was 10.7 months for score 3-5 and 15.4 months for score X-2 (p=0.046) with the association remaining significant in both uni- and multivariable analyses.

Conclusion

The NMN-BBB score showed an inverse association with patient outcome parameters including PFS, OS and TTNI. Further studies are needed to validate our findings. The NMN-BBB score may support baseline risk stratification and patient selection for clinical trials in newly diagnosed glioblastoma.



Abstract Number: 30

Abstract Title: SSTR PET Characteristics of Newly Diagnosed Meningiomas: Correlation with Neuropathological Diagnosis and Molecular Profile

Authors:

Thomas Schabhüttl^{1,2}, Maximilian J. Mair^{1,2}, Thomas Eska^{3,4}, Enio Barci¹, Ergi Istrefi¹, Tobias Greve^{5,8}, Christian Schichor⁵, Annamaria Biczok⁶, Matthias Philipp Fabritius⁷, Prof. Matthias Preusser², Patrick Harter^{3,4,8}, Nathalie L. Albert^{1,4,8}

¹Department of Nuclear Medicine, LMU University Hospital, LMU Munich, Munich, Germany, ²Division of Oncology, Department of Medicine I, Medical University of Vienna, Vienna, Austria, ³Center for Neuropathology and Prion Research, Institute of Neuropathology, Medical Faculty LMU University Hospital, LMU Munich, Munich, Germany, ⁴German Cancer Consortium (DKTK) partner site Munich, Germany and German Cancer Research Center (DKFZ), Heidelberg, Germany, ⁵Department of Neurosurgery, LMU University Hospital, LMU Munich, Munich, Germany, ⁶Department of Neurosurgery, University Hospital Heidelberg, Heidelberg University, Heidelberg, Germany, ⁷Department of Radiology, LMU University Hospital, LMU Munich, Munich, Germany, ⁸Bavarian Cancer Research Center (BZKF), Munich, Germany

Background

This study investigates the association between somatostatin receptor (SSTR) PET imaging features and histological as well as molecular characteristics of newly diagnosed meningiomas.

Methods


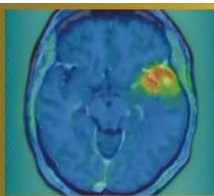
Patients with newly diagnosed, histologically confirmed meningioma who underwent preoperative SSTR PET/CT (⁶⁸Ga]Ga-DOTATATE/-DOTATOC or [¹⁸F]F-SiTATE) were retrospectively analyzed. Clinical, demographic, histological (WHO grade, histological subtype), and molecular data (copy number variations (CNV), DNA methylation profile) were collected. PET/CT parameters included SUVmax, SUVmean, PET volume (using a fixed SUV threshold of ≥ 4.0), lesion size on CT (maximum perpendicular diameter), as well as the presence of multifocality, osseous involvement, and intralesional heterogeneity.

Results

A total of 121 patients with newly diagnosed meningioma (108 WHO grade 1, 13 WHO grade 2) were evaluated. Median SUVmax was 17.4 in WHO grade 1 and 23.4 in WHO grade 2 meningiomas ($p = 0.68$), with a corresponding SUVmean of 8.4 and 8.3, respectively. PET volume was significantly larger in WHO grade 2 compared with WHO grade 1 meningiomas (41.9 mL vs. 18.1 mL; $p < 0.001$), in line with results previously described in the literature. Multifocality, osseous involvement, and intralesional heterogeneity did not differ between WHO grades. In subgroup analyses, secretory meningiomas demonstrated a significantly higher SUVmax compared with other histological subtypes (62.2 vs. 16.2 (meningothelial) vs. 16.1 (transitional) vs. 21.5 (atypical); $p < 0.001$ for pairwise comparisons). Molecular pathological analyses are currently ongoing and will be supplemented.

Conclusions

While WHO grade 1 and WHO grade 2 meningiomas do not show significant differences in uptake intensity or uptake patterns, WHO grade 2 meningiomas exhibit significantly larger PET volumes. Among histological subgroups, secretory meningiomas demonstrate more than a threefold higher uptake intensity compared with other subtypes. Ongoing molecular pathological correlations will clarify whether PET differences are also observed among molecular subtypes.



Abstract Number: 31

Abstract Title: Noninvasive discrimination of CDKN2A/B status and WHO grading using [18F]FET-PET imaging in IDH-mutant astrocytoma

Authors:

Katharina J. Müller¹, Maximilian Mair², Jan-Michael Werner³, PD Dr. med. Michael Müther⁴, Wolfgang Roll⁵, Artem Chaban⁶, Jonas Reis⁷, Thomas Schabhüttl^{2,8}, Julia Hilgers⁹, Keith George Ciantar^{9,10}, Philipp Lohmann^{9,11}, Patrick Harter¹², Louisa von Baumgarten^{1,13}, Claira Delbridge¹⁴, Igor Yakushev⁶, Johannes Hainfellner¹⁵, Georg Widhalm¹⁶, Markus Hacker¹⁷, Norbert Galldiks^{3,9}, Matthias Preusser², Nathalie L. Albert⁸

¹Department of Neurology, LMU University Hospital, LMU Munich, Munich, Germany, ²Division of Oncology, Department of Medicine I, Medical University of Vienna, Vienna, Austria, ³Department Neurology, Faculty of Medicine and University Hospital Cologne, Cologne, Germany, ⁴Department of Neurosurgery, University Hospital Münster, Münster, Germany, ⁵Department of Nuclear Medicine, University Hospital Münster, Münster, Germany, ⁶Department of Nuclear Medicine, Technical University Hospital of Munich, Munich, Germany, ⁷Department of Neuroradiology, LMU University Hospital, LMU Munich, Munich, Germany, ⁸Department of Nuclear Medicine, LMU University Hospital, Munich, Germany, ⁹Institute of Neuroscience and Medicine (INM-3, INM-4), Research Center Juelich (FZJ), Juelich, Germany, ¹⁰Institute for Imaging and Computer Vision, RWTH Aachen University, Aachen, Germany, ¹¹Department for Nuclear Medicine, RWTH Aachen University Hospital, Germany, ¹²Center for Neuropathology and Prion Research, LMU University Hospital, Munich, Germany, ¹³Department of Neurosurgery, LMU University Hospital, Munich, Germany, ¹⁴Institute of Pathology, Department of Neuropathology, Technical University Hospital of Munich, Munich, Germany, ¹⁵Department of Neurology, Medical University of Vienna, Vienna, Germany, ¹⁶Department of Neurosurgery, Medical University of Vienna, Vienna, Germany, ¹⁷Division of Nuclear Medicine, Medical University of Vienna, Vienna, Germany

Background

With the introduction of the 2021 WHO classification, molecular profiling has become central to glioma diagnosis. Homozygous CDKN2A/B deletion defines WHO grade 4 in IDH-mutant astrocytoma, independent of histologic features. However, molecular diagnostics are time-consuming, underscoring the clinical need for surrogate biomarkers that enable early identification of aggressive tumor biology. The aim of this study was to investigate the value of [18F]FET-PET imaging for prediction of molecular tumor biology in IDH-mutant astrocytoma.

Methods


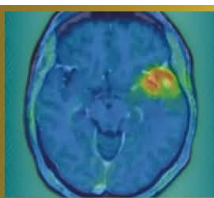
In this multicentric, retrospective study we correlated [18F]FET-PET metrics DNA-methylation-based molecular diagnosis. The discovery cohort (University Hospital of Munich) included 89 patients with IDH-mutant astrocytoma, all with known CDKN2A/B status and available [18F]FET-PET (imaging performed 3 months before/after NGS). Quantitative PET parameters (SUVmax, SUVmean, TBRmax, TBRmean, PET-positive volume) were analyzed. Findings were validated in an external cohort of 119 patients with IDH-mutant astrocytoma from four independent neuro-oncological centers.

Results

In the discovery cohort (n=89, median age 41 years, IQR 18-64), tumors with homozygous CDKN2A/B loss demonstrated a median TBRmax of 2.6 (IQR, 2.5–3.7), which was significantly higher than in WHO grade 2 and 3 astrocytoma (median TBRmax in WHO grade 2: 1.5; IQR 1-2.2; median TBRmax in WHO grade 3: 1.8; IQR 1-2.2; p=0.003). ROC analysis demonstrated that TBRmax (at a cutoff of 2.4) identified astrocytomas with molecular and/or histologic WHO grade 4 with a sensitivity of 0.93 and specificity of 0.82 (AUC=0.89, p<0.001). These results were reproducible in the external validation cohort, yielding a sensitivity of 0.81 and specificity of 0.83 (AUC=0.87, p<0.001).

Conclusion

[18F]FET-PET-derived TBRmax is significantly increased in cases with homozygous CDKN2A/B loss and/or histologic WHO grade 4 and may serve as a noninvasive surrogate for high-grade astrocytoma. Integration of PET imaging with genomic profiling has the potential to support treatment planning, however further investigation for optimized thresholding is warranted.



Abstract Number: 32

Abstract Title: The prognostic significance of TSPO-PET imaging in IDH-mutant glioma: a single-center, retrospective study

Authors:

Katharina J. Müller¹, Roman Stürzl², Sabrina Kirchleitner³, Isabelle von Polenz², Viktoria Ruf⁴, Veit M. Stoecklein^{3,5}, Jonas Reis⁶, Stefanie Quach^{3,7}, Lena Kaiser², Julia Lorenz⁸, Adrian Zounek², Patrick N. Harter^{4,5,9}, Rainer Rupprecht¹⁰, Markus J. Riemenschneider⁸, Matthias Brendel^{2,11,12}, Niklas Thon³, Joerg-Christian Tonn³, Louisa von Baumgarten^{1,3,5,9}, Nathalie L. Albert²

¹Department of Neurology, LMU University Hospital, LMU Munich, Germany, Munich, ²Department of Nuclear Medicine, LMU University Hospital, LMU Munich, Germany, ³Department of Neurosurgery, LMU University Hospital, LMU Munich, Germany, ⁴Center for Neuropathology and Prion Research, Faculty of Medicine, LMU Munich, Germany, ⁵German Cancer Consortium (DKTK), Partner Site Munich, a Partnership Between DKFZ and LMU University Hospital, Munich, Germany, ⁶Institute of Neuroradiology, LMU University Hospital, LMU Munich, Germany, ⁷Department of Neurosurgery (Evangelisches Klinikum Bethel), Medical School, Bielefeld University, Bielefeld, Germany, ⁸Department of Neuropathology, Regensburg University Hospital, Regensburg, Germany, ⁹Bavarian Cancer Research Center (BZKF), Munich, Germany, ¹⁰Department of Psychiatry and Psychotherapy, Molecular Neurosciences, University of Regensburg, Regensburg, Germany, ¹¹German Center for Neurodegenerative Diseases (DZNE) Munich, Munich, Germany, ¹²Munich Cluster for Systems Neurology (SyNergy), Munich, Germany

Purpose

Clinical prognostication and decision-making in IDH-mutant glioma is increasingly complex, especially with new targeted treatment options like IDH-inhibitors. Individual patient risk stratification for better treatment planning is needed; however, standard prognostic models rely on clinical and histologic parameters as well as MRI, which may not fully reflect the tumor's biological behavior. Positron emission tomography (PET) imaging of the 18 kDa translocator protein (TSPO) is known as surrogate marker of activated microglia and macrophages and enables non-invasive assessment of the tumor microenvironment and peri-/intratumoral inflammation as well as TSPO-positive tumor cells. The aim of this study was to investigate TSPO-PET imaging in IDH-mutant glioma and its association with outcome.

Methods

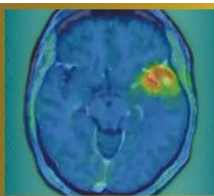
In this monocentric, retrospective study, 46 patients with newly diagnosed IDH-mutant glioma who had undergone TSPO-PET imaging with [¹⁸F]GE180 prior to any therapeutic intervention were included. Quantitative PET parameters including mean and maximum standardized uptake values (SUVmax, SUVmean) and the respective PET-positive tumor volumes were evaluated for their association with clinical data and time to next intervention (TTNI), and overall survival (OS).

Results

The cohort consisted of 27 patients (58.7%) with astrocytoma, IDH-mutant (median age 36 years (30-51)) and 19 patients (41.3%) with oligodendroglioma, IDH-mutant and 1p/19q-codeleted (median age 41 years (36-48)). High SUVmax on TSPO-PET imaging was associated with shorter TTNI, and OS (p=0.0118 and p=0.0459, respectively). In multivariate analyses adjusting for age, KPS, WHO grade, FET-PET-positive volume, and tumor area on contrast-enhanced MRI, the TSPO-PET-positive signal (SUVmax) remained independently associated with TTNI (hazard ratio (HR)=4.342, 95% CI: 1.222 to 15.47, p=0.0238).

Conclusions

This study highlights the potential prognostic utility of TSPO-PET imaging in newly diagnosed IDH-mutant glioma. Our findings support the inclusion of PET imaging in future clinical trials to develop imaging-based risk models for better prognostication and individualized treatment guidance.



Abstract Number: 33

Abstract Title: [18F]FET PET characteristics in recurrent oligodendroglioma – considerations for clinical trials

Authors:

Maximilian Mair^{1,2}, Jera Isakaj¹, Jonas Reis³, Enio Barci¹, Jonathan Weller⁴, Sophie Katzendobler⁴, Matthias Preusser², Patrick N. Harter^{5,6,7}, Louisa von Baumgarten^{4,6,7,8}, Niklas Thon^{4,9}, Nathalie L. Albert^{1,6,7}

¹Department of Nuclear Medicine, LMU University Hospital, LMU Munich, Munich, Germany, ²Division of Oncology, Department of Medicine I, Medical University of Vienna, Vienna, Austria, ³Institute of Neuroradiology, LMU University Hospital, LMU Munich, Munich, Germany, ⁴Department of Neurosurgery, LMU University Hospital, LMU Munich, Munich, Germany, ⁵Center of Neuropathology and Prion Research, LMU University Hospital, LMU Munich, Munich, Germany, ⁶Bavarian Cancer Research Center (BZKF), Partner Site Munich, Munich, Germany, ⁷German Cancer Consortium (DKTK), Partner Site Munich, Munich, Germany, ⁸Department of Neurology, LMU University Hospital, LMU Munich, Munich, Germany, ⁹Department of Neurosurgery, Knappschaft University Hospital Bochum, Bochum, Germany

Background

Oligodendroglioma (IDH-mutant, 1p/19q-codeleted) has a comparably favorable prognosis among diffuse gliomas, but recurrences are frequent and challenging to treat after previous therapy. While measurable disease according to MRI is frequently used as an inclusion criterion for clinical trials in glioma, uptake in amino acid PET might represent a rational eligibility criterion in this setting. However, such parameters are poorly characterized.

Material and Methods


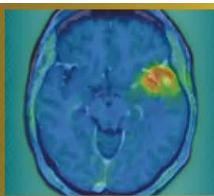
In this retrospective cohort study, patients with oligodendroglioma (IDH-mutant, 1p/19q-codeleted) and O-(2-[18F]-fluoroethyl)-L-tyrosine ([18F]FET) PET at recurrence (histologically verified and/or high clinical/radiological suspicion) were included. PET imaging was evaluated according to PET RANO 1.0 criteria, and uptake (maximum/mean tumor-to-background ratios; TBRmax, TBRmean) as well as PET-positive volume (PET volume) were measured.

Results

In total, 146 patients with overall 148 recurrences of oligodendroglioma (IDH-mutant, 1p/19q-codeleted) were included, of whom 80 (54.8%) were male. Median age at PET at recurrence was 49 years (range: 21-77), and median time from first documented surgery to PET at recurrence was 5.6 years (range: 0.2-18.3). According to PET RANO 1.0 criteria, PET measurable disease was observed in 132/148 (89.2%), followed by non-measurable in 14/148 (9.5%) and no measurable disease in 2/148 (1.4%) at recurrence. Median TBRmax was 2.91 (range: 1.48-9.39), median TBRmean was 1.97 (range: 1.65-3.00), and median PET volume was 15.2 mL (range: 0.16-199.64). In 29 patients, data from previous PET at initial diagnosis were available. In these cases, there was no difference in TBRmax ($p = 0.214$) or TBRmean ($p = 0.702$) between initial diagnosis and recurrence.

Conclusion

The majority of oligodendrogliomas at recurrence shows high uptake in amino acid PET and measurable disease according to PET RANO 1.0 criteria. These findings could inform the design of clinical trials investigating novel therapeutic agents including radiolabeled amino acid analogues in this patient population.



Abstract Number: 34

Abstract Title: Validation of PET RANO 1.0 criteria in a retrospective, single-center cohort of patients with IDH-mutant glioma

Authors:

Maximilian Mair^{1,2}, Theodora Aras-Brendler¹, Jonas Reis³, Isabelle von Polenz¹, Lilian Wiegand¹, Roman Stürzl¹, Enio Barci¹, Katharina J. Müller⁴, Jonathan Weller⁵, Sophie Katzendobler⁵, Matthias Preusser², Stephan Schönecker⁶, Patrick N. Harter^{7,8,9}, Niklas Thon^{5,10}, Louisa von Baumgarten^{4,5,8,9}, Nathalie L. Albert^{1,8,9}

¹Department of Nuclear Medicine, LMU University Hospital, LMU Munich, Munich, Germany, ²Division of Oncology, Department of Medicine I, Medical University of Vienna, Vienna, Austria, ³Institute of Neuroradiology, LMU University Hospital, LMU Munich, Munich, Germany, ⁴Department of Neurology, LMU University Hospital, LMU Munich, , Germany, ⁵Department of Neurosurgery, LMU University Hospital, LMU Munich, Munich, Munich, Germany, ⁶Department of Radiation Oncology, LMU University Hospital, LMU Munich, Munich, Germany, ⁷Center of Neuropathology and Prion Research, Faculty of Medicine, LMU Munich, Munich, Germany, ⁸Bavarian Cancer Research Center (BZKF), Partner Site Munich, Munich, Germany, ⁹German Cancer Consortium (DKTK), Partner Site Munich, Munich, Germany, ¹⁰Department of Neurosurgery, Knappschaft University Hospital Bochum, Bochum, Germany

Background

PET RANO 1.0 criteria were designed as a consensus-based, standardized framework for response assessment in glioma. However, validation in well-annotated cohorts as well as correlative analyses with outcome are urgently needed.

Material and Methods


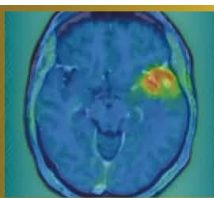
Patients with IDH-mutant glioma and at least two O-(2-[¹⁸F]-fluoroethyl)-L-tyrosine ([¹⁸F]FET) PET scans during one treatment line in 02/2013 - 08/2025 were eligible for this retrospective study. PET-based response assessment was performed applying PET RANO 1.0 criteria based on maximum and mean tumor-to-background ratios (TBRmax/TBRmean) and PET volume. Intervention-free survival (IFS) was used as survival endpoint.

Results

219 patients (106 [48.4%] astrocytoma, 110 [50.2%] oligodendroglioma, 3 with inconclusive 1p/19q testing) with 251 lesions were included. Of these, 117 (53.4%) were male, and responses in 220 treatment lines (173 [78.6%] first line treatment; 47 [21.4%] recurrence/progression) were analyzed. Time between PET scans was 6.7 months in median (range: 2.4-11.8). During first-line treatment, PET-based complete remission (PET-CR) was seen in 7/173 (4.0%), partial remission (PET-PR) in 32/173 (18.5%), stable disease (PET-SD) in 74/173 (42.8%), and progressive disease (PET-PD) in 60/173 (34.7%) patients. PET-PD was primarily based on PET volume increase alone (27/60, 45.0%) or combined with an increase in maximum/mean tumor-to-background ratios (TBRmax/TBRmean; 19/60, 31.7%), followed by new measurable disease in 14/60 (23.3%) patients. IFS was longer in patients with PET-SD/-PR/-CR (33.6 months; 95%CI: 27.1-48.3) compared to PET-PD (13.3 months; 95%CI: 9.5-27.6; p = 0.005). At recurrence, PET-CR was observed in 3/47 (6.4%), PET-PR in 16/47 (34.0%), PET-SD in 24/47 (51.1%) and PET-PD in 4/47 (8.5%) patients, with numerical IFS differences (p = 0.16) according to PET response.

Conclusion

PET RANO 1.0 responses are prognostically relevant in IDH-mutant glioma. Further analyses integrating MRI-based response assessment are ongoing to inform the development of rational clinical trial endpoints in this population.



Abstract Number: 35

Abstract Title: A Phase 1 trial to determine the maximum tolerated dose and patient-specific dosimetry of fractionated intracavitary radioimmunotherapy with Lutetium-177 labeled 6A10 Fab fragments in patients with glioblastoma – an updated interim report

Authors:

Wolfgang Roll¹, PD Dr. med. Michael Mütter¹, Guido Böning², Franz-Josef Gildehaus², Claire Delbridge³, Nathalie L. Albert², Michael Schäfers¹, Astrid Delker², Lars Stegger¹, Reinhard Zeidler⁴, Hans-Jürgen Reulen², Prof. Walter Stummer¹

¹University Hospital Münster, Münster, Germany, ²LMU University Hospital, Ludwig-Maximilians-University, Munich, Germany, ³Technical University of Munich, Munich, Germany, ⁴Helmholtz Center Munich, Munich, Germany

Background

Following maximal safe resection and standard adjuvant radio- and chemotherapy, approved maintenance therapies for glioblastoma are lacking. Intracavitary radioimmunotherapy (iRIT) injected into the resection cavity offers a promising strategy for improving local tumor control. This is an updated interim report of the NOA-22 study (NCT05533242).

Material and Methods

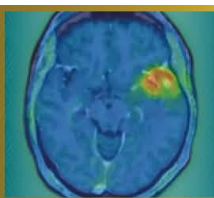
This prospective single-armed, multicenter phase 1 study, following a modified 3+3-design, investigates the use of 6A10-Fab fragments targeting carbonic anhydrase XII, labeled with lutetium-177 ([¹⁷⁷Lu]Lu-6A10- Fab). Patients with glioblastoma after concomitant radio-chemotherapy and adjuvant standard chemotherapy with no or small residual disease are included. The injected activity is adapted to the volume of the resection cavity, resulting in a dose of 44Gy (cohort 1), 48Gy (cohort 2) and 52Gy (cohort 3). Primary study objective is to determine the maximum tolerated dose and safety of adjuvant radio-immunotherapy with [¹⁷⁷Lu]Lu-6A10-Fab.

Results

Following the completion of cohorts 1 and 2, which comprised three patients each, two patients have entered cohort 3. Two patients from cohort 1 presented with reversible adverse events of grades 2 and 3 (CTCAE 5.0). One patient presented with perifocal brain edema that decreased after a course of steroid treatment. A second patient experienced a single seizure that responded to steroids and antiepileptic medication, accompanied by increasing perifocal edema on MRI. No hematological adverse events of grades 3 or higher occurred. Dosimetry did not reveal absorbed doses above the upper dose limits for organs at risk. So far, no patient experienced progressive disease after accrual start in January 2024 (follow-up range: 5-24 months).

Conclusion

Intracavitary administration of [¹⁷⁷Lu]Lu-6A10-Fab appears feasible and safe. The study is currently enrolling its final patients in cohort 3, and we expect complete 6-month follow-up for the full cohort by the end of 2026 to initiate per-protocol analyses.



Abstract Number: 36

Abstract Title: Assessment of 18F-FET PET-based response to contemporary CNS-active systemic agents in patients with brain metastases using the PET RANO BM 1.0 criteria

Authors:

Jana-Marie Peplinski¹, Julia Hilgers², Keith George Ciantar^{2,3}, Manuel Kraft^{1,2}, Jan-Michael Werner¹, Garry Ceccon¹, Michael Wollring¹, Isabelle Stetter¹, Gabriele Stoffels², Gereon R. Fink^{1,2}, Karl-Josef Langen^{2,4}, Philipp Lohmann^{2,4}, Norbert Galldiks^{1,2}

¹Dept. of Neurology, Faculty of Medicine and University Hospital Cologne, Cologne, Germany, ²Inst. of Neuroscience and Medicine (INM-3, INM-4), Research Center Juelich, Juelich, Germany, ³Inst. for Imaging and Computer Vision, RWTH Aachen University, Aachen, Germany, ⁴Dept. of Nuclear Medicine, RWTH Aachen University Hospital, Aachen, Germany, Germany

Background

Following multimodal brain metastases treatment, amino acid PET may improve diagnostic certainty when MRI findings remain equivocal. We evaluated the recently defined amino acid PET-based response assessment criteria (PET RANO BM 1.0) for their ability to predict longer progression-free survival (PFS) in patients with brain metastases treated with contemporary CNS-active systemic agents.

Patients and Methods

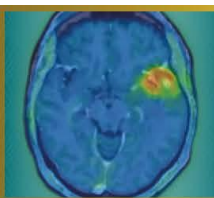
From 2015-2025, 242 patients with brain metastases who underwent 556 O-(2-[¹⁸F]-fluoroethyl)-L-tyrosine (FET) PET scans (median number, 4; range, 1-8) during the course of disease were retrospectively identified. Search criteria for data evaluation were (i) patients with brain metastases secondary to melanoma, non-small cell lung cancer, or breast cancer, (ii) treatment involving targeted therapies or immune checkpoint inhibitors (with or without concurrent radiosurgery), and (iii) presence of both a baseline FET PET scan before treatment initiation and at follow-up. Tumor-to-brain ratios (TBR_{mean}, TBR_{max}) and metabolic tumor volumes were obtained fully automated according to the current guidelines. Univariate survival estimates were performed to evaluate the value of the PET RANO BM 1.0 criteria to predict a significantly longer PFS.

Results

Twenty-three patients with 50 brain metastases secondary to melanoma (n=14 patients), non-small cell lung cancer (n=7 patients), or breast cancer (n=2 patients) fulfilled the search criteria. The median time between the two FET PET scans was 4.0 months (range, 2.0-24.0 months). According to the PET RANO BM 1.0 criteria applied to each brain metastasis, patients fulfilling the criterion PET-based Stable Disease (n=0), Partial Response (n=8), or Complete Response (n=1) had a significantly longer PFS than patients with PET-based Progressive Disease (n=14) (18.0 vs. 6.0 months; P=0.036).

Conclusion

Our data suggest that the PET RANO BM 1.0 criteria are helpful to predict significantly longer PFS in patients with brain metastases undergoing contemporary CNS-active systemic agents. Prospective validation of these amino acid PET response criteria is warranted.



Abstract Number: 37

Abstract Title: Evaluation of glioblastoma-brain assembloids as an advanced in vitro model for preclinical targeted radionuclide testing

Authors:

Sarah Waelkens^{1,2}, Charlotte Segers¹, Veronique Bogaerts¹, Tomas Opsomer¹, Frederik De Smet², Roel Quintens¹

¹Radiobiology Unit, Institute for Nuclear Medical Applications, Belgian Nuclear Research Centre, SCK CEN, Mol, Belgium, ²Laboratory of Precision Cancer Medicine, Translational Cell and Tissue Research Unit, Department of Imaging and Pathology, KU Leuven, Leuven, Belgium

Background

In vitro models constitute the first step in preclinical targeted radionuclide therapy (TRT) evaluation, but traditionally rely on 2D-cultures that poorly capture tumor heterogeneity, spatial target expression, and tumor-microenvironment interactions, critical factors in glioblastoma (GBM). This limits prediction of radioligand uptake and TRT-specific effects, such as crossfire- and bystander-signaling. While advanced 3D co-culture systems better preserve architectural and microenvironmental features, they remain underexplored for TRT research. GBM-brain assembloids, combining patient-derived tumor spheroids with stem cell-derived cortical organoids, represent a promising model.

Material and Methods

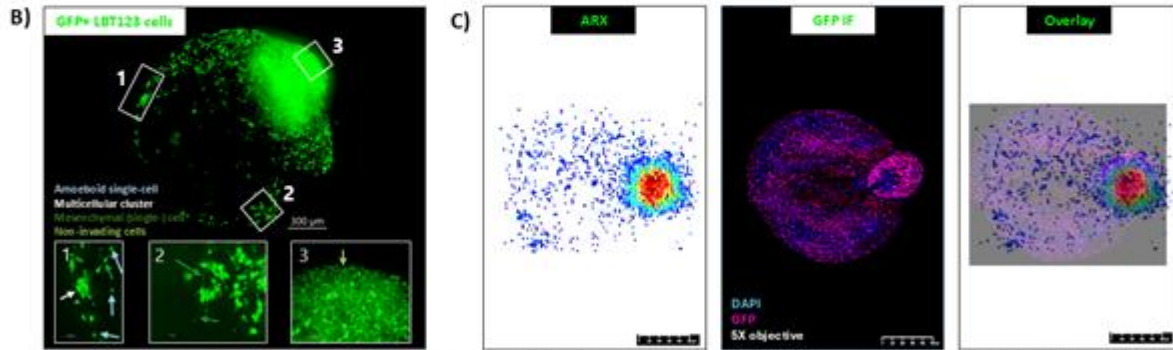
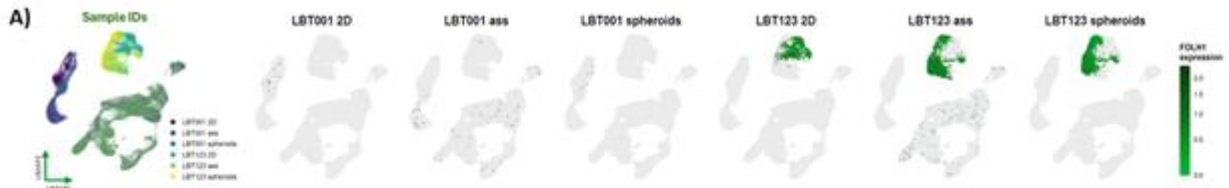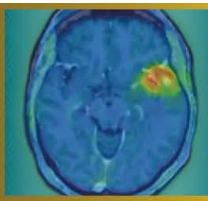
A panel of patient-derived GBM cell lines (PDGCLs) was screened for clinically relevant TRT targets, identifying prostate-specific membrane antigen (PSMA) as highly expressed in a subset of tumors. GBM-brain assembloids from two PDGCLs were generated by co-culturing GBM spheroids with cortical brain organoids. PSMA expression was evaluated using western blotting, immunofluorescence (IF), and single-cell RNA sequencing (scRNAseq) on spheroids and assembloids. Spatial distribution and specific binding of [¹⁷⁷Lu]Lu-PSMA-I&T (10nM, 40MBq/nmol) were assessed by in vitro autoradiography on cryosectioned spheroids and assembloids in the presence or absence of a structurally unrelated blocking agent 2-PMPA, and later combined with IF.

Results


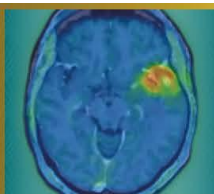
Two PDGCLs were selected: PSMA-negative LBT001 and PSMA-positive LBT123. Both successfully formed assembloids with invading GFP-positive tumor cells. scRNAseq demonstrated PSMA expression exclusively in tumor cells of LBT123-derived assembloids, with no expression in healthy organoid cells nor LBT001 cells. LBT123-specific target expression was further corroborated by western blotting and IF. In vitro autoradiography combined with PSMA/GFP IF confirmed highly selective [¹⁷⁷Lu]Lu-PSMA-I&T binding in PSMA/GFP-positive tumor regions, with no binding in surrounding healthy organoid cells.

Conclusion

GBM-brain assembloids demonstrate spatially resolved, tumor-specific TRT binding within a physiologically relevant microenvironment. This finding provides a foundation for further studies, and we propose assembloids represent a promising model for evaluating radioligand affinity and specificity, therapeutic efficacy, and radiobiological effects, including potential bystander- and crossfire-interactions.



A) Single-cell RNA sequencing analysis of two patient-derived glioblastoma (GBM) cell lines cultured under 2D, spheroid, and assembloid conditions. Uniform Manifold Approximation and Projection (UMAP) of batch-corrected single-cell transcriptomes across all culture systems, colored by cell line and model (left) and FOLH1 expression levels per model (remaining).
B) GFP-positive LBT123 glioblastoma cells exhibit distinct invasion patterns within cortical brain organoids. Representative confocal image of a cleared assembloid. Scale bar = 300 μ m.
C) Immunofluorescence staining for GFP on LBT123 glioblastoma-brain assembloid cryosections [blue = DAPI, purple = GFP] compared with autoradiography (ARX) of [125 I]-PSMA-I&T (10 nM, 40 MBq/nmol) on an adjacent section, with merged overlay. Cryosections thickness = 12 μ m.



Abstract Number: 38

Abstract Title: FET-PET in Glioblastoma (FIG) Study (TROG 18.06): Towards FET-PET-Guided Radiotherapy Target Volume Delineation in Glioblastoma

Authors:

Eng-Siew Koh¹, Professor Roslyn J. Francis^{2,3}, Professor Sze Ting Lee^{4,5}, Associate Professor Eddie Lau^{5,6}, Assoc. Professor Elizabeth Thomas², Professor Hui K. Gan^{4,7}, Angela Whitehead⁸, Alisha Moore⁸, Rachael Dykyj⁸, Olivia Cook⁸, Alana Rossi⁸, Dr Nathaniel Barry⁹, Professor Martin Ebert^{9,10}, Associate Professor Sweet Ping Ng¹¹, Associate Professor Mark B. Pinkham^{12,13}, Michael Back¹⁴, Dr Nicholas Bucknell¹⁰, Professor Dale L. Bailey^{15,16}, Assoc. Professor Bradford A. Moffat¹⁷, Assoc. Professor Greg Fitt^{6,18}, Dr Isidoro Ruisi Ruisi¹, Prof Andrew Scott^{4,5}

¹Liverpool Hospital, University Of New South Wales, Sydney, Australia, ²Department of Nuclear Medicine, Sir Charles Gairdner Hospital, Nedlands, Perth, Australia, ³Medical School, The University of Western Australia, Crawley, Australia, ⁴Tumour Targeting Program, Olivia Newton-John Cancer Research Institute, Heidelberg, Australia, ⁵Department of Molecular Imaging and Therapy, Austin Health, Heidelberg, Australia, ⁶Department of Radiology, Austin Health, Heidelberg, Australia, ⁷Austin Health, Department of Medical Oncology, Melbourne, Australia, ⁸TROG Cancer Research, Newcastle, Australia, ⁹School of Physics, Mathematics and Computing, University of Western Australia, Crawley, Australia, ¹⁰Department of Radiation Oncology, Sir Charles Gairdner Hospital, Perth, Nedlands, Australia, ¹¹Austin Health, Department of Radiation Oncology, Heidelberg, Australia, ¹²Department of Radiation Oncology, Princess Alexandra Hospital, Brisbane, Australia, ¹³Icon Cancer Centre North Lakes and Greenslopes Private Hospital, Brisbane, Australia, ¹⁴Department of Radiation Oncology, Royal North Shore Hospital, St Leonards, Sydney, Australia, ¹⁵Faculty of Medicine & Health, University of Sydney, Camperdown, Australia, ¹⁶Department of Nuclear Medicine, Royal North Shore Hospital, Sydney, Australia, ¹⁷Melbourne Brain Centre Imaging Unit, Department of Radiology, University of Melbourne, Melbourne, Australia, ¹⁸Department of Radiology, University of Melbourne, Melbourne, Australia

Background

The FET-PET in Glioblastoma (FIG) study (TROG 18.06) is a prospective, multi-site phase 2 trial evaluating the impact of O-(2-[¹⁸F]-fluoroethyl)-L-tyrosine positron emission tomography (FET-PET) on radiation target (RT) volume definition and treatment response assessment (pseudo versus true progression) in glioblastoma.

Materials and Methods

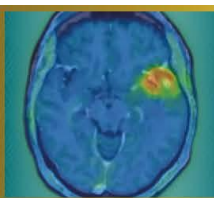
Eligible patients with Glioblastoma from 11 credentialled Australian centres are enrolled into Group 1 (FET-PET1 at pre-chemoradiation) or Group 2 (FET-PET2 post-chemoradiation). The Timepoint 1 workflow involves: (1) standard adjuvant radiation planning with delineation of RT target volumes based on MRI, and (2) generation of hybrid volumes incorporating centrally reviewed nuclear medicine physician (NMP)-derived biological tumour volumes (BTVs) from FET-PET1, using MiM software (v7.0). All submitted NMP BTVs and radiation oncology (RO) contours undergo protocolised central review, with resubmission required for non-compliance.

Results

As at February 2026, 284 participants have enrolled (Group 1: 161; Group 2: 123), with n=139 evaluable Glioblastoma FET-PET1 cases and n=5 Grade 4 IDHmutant cases acquired. Pre-trial credentialling identified interobserver BTV variation in 25/72 (34.7%) submissions including 12 major deviations. Of the 144 prospective FET-PET1 BTVs, 20 (13.9%) required resubmission, most due to static GTV over-contouring (n=12), MiM workflow errors (n=3), misinterpretation of static FET signal (n=3) and dynamic changes in volume of interest (n=1). To date, full central RO review of clinical and hybrid RT volumes has demonstrated a 9/54 (16%) resubmission rate, with 10/54 (19%) deemed a conditional pass and 35/54 (65%) cases passed outright. A dedicated MiM trial workflow will support radiation dosimetric and volumetric comparison of MRI-only versus FET-PET-informed RT target volumes in the evaluable cohort.

Conclusions

Robust credentialling and centralised quality assurance programmes should be embedded within multi-centre molecular imaging-integrated neuro-oncology trials. The FIG trial remains the largest prospective study of its kind and will inform integration of FET-PET-guided approaches to adjuvant radiation planning in Glioblastoma.



Abstract Number: 39

Abstract Title: Diagnostic accuracy of long-axial-field-of-view [18F]FET PET/CT in high-grade glioma - semi-quantitative cutoff values for tumour detection

Authors:

Michelle Amon¹, Dr. med. Alexandra Lazar², Dr. med Piotr Radojewski³, Prof. Dr. med. Axel Rominger¹, Dr. Hasan Sari⁴, Dr. med. Clemens Mingels¹

¹Department of Nuclear Medicine, Inselspital, Bern University Hospital, Bern, Switzerland, ²Vita-Salute San Raffaele University, Milan, Italy, ³University Institute of Diagnostic and Interventional Neuroradiology, Inselspital Bern University Hospital and University of Bern, Bern, Switzerland, ⁴Siemens Healthineers International AG, Zurich, Switzerland

Background

Long-axial field-of-view (LAFOV) PET/CT has shown improved image quality due to its higher sensitivity. In this work, we aimed to explore potential new cutoff values for LAFOV [18F]FET PET/CT in high-grade glioma for early differentiation between tumour recurrence and radiation necrosis.

Material and Methods

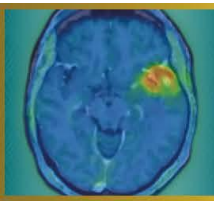
In this ongoing retrospective evaluation, 28 patients with high-grade glioma who underwent LAFOV [18F]FET PET/CT (Biograph Vision Quadra, Siemens Healthineers) for the assessment of tumour recurrence after surgery and radiotherapy. Dynamic scans were acquired for 40 minutes upon injection of 191 ± 10 MBq [18F]FET. Last 20 minutes of data were reconstructed into static PET images. Lesions were manually delineated; parameters of interest were the maximum standardized uptake value (SUV_{max}), tumour-to-background ratios (TBR) from static images and visual analysis of the time-activity curves (TAC). Background uptake was assessed at the semioval centre of the contralateral hemisphere. For diagnostic accuracy a composite reference standard (histopathology, imaging and follow-up up to 24 months) was used. Receiver operating characteristic (ROC) curve analysis was performed to determine optimal TBR cutoff values.

Results

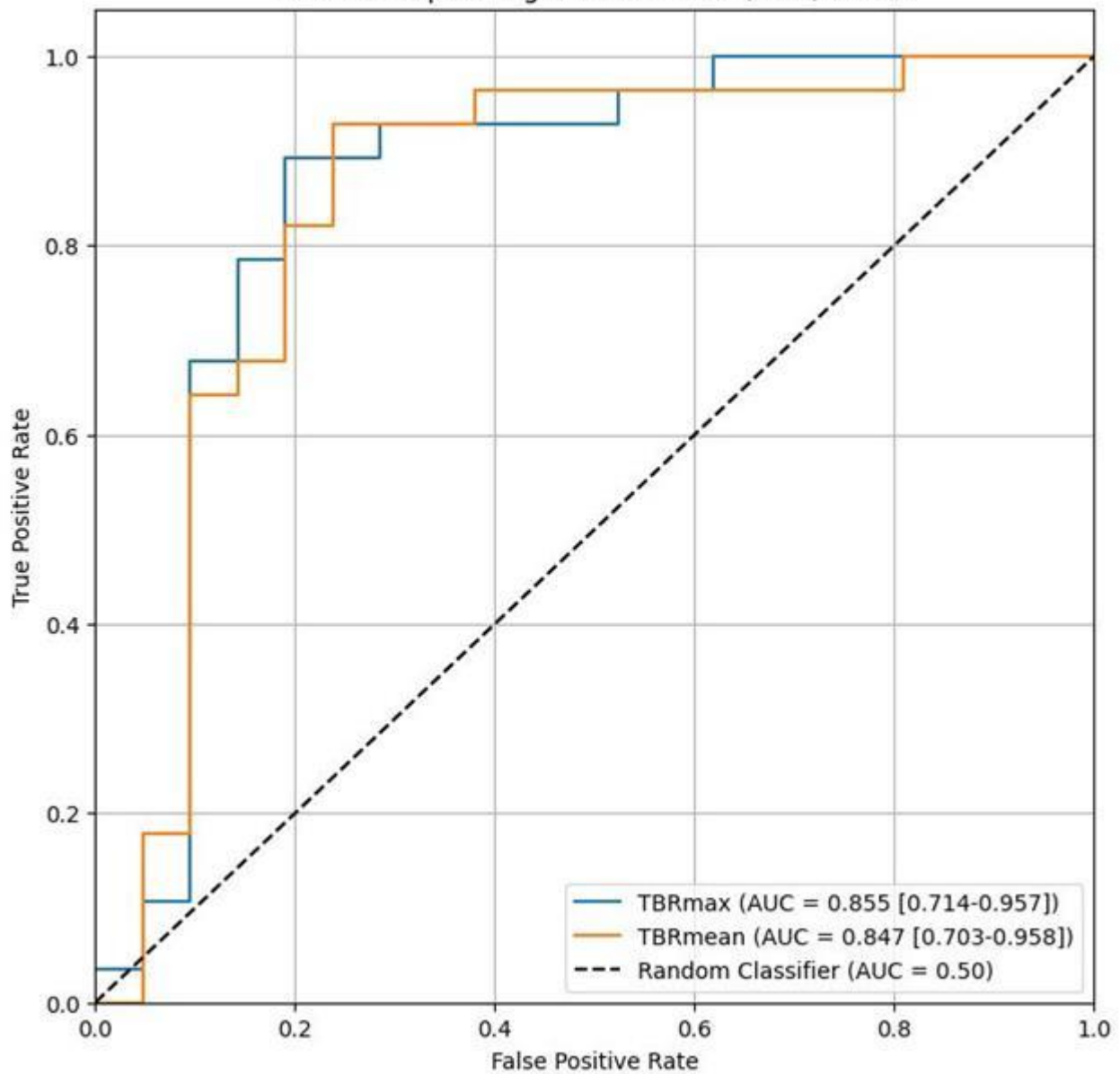
Tumour recurrence was detected in 28/49 lesions. TBR_{max} and TBR_{mean} were significantly different between tumour recurrence and treatment-related changes ($p < 0.001$), with values of 1.60 (IQR 0.98) and 1.34 (IQR 0.90) treatment-related changes and, respectively, 3.47 (IQR 0.96) and 2.60 (IQR 0.87) for recurrence. ROC analysis identified an optimal TBR_{max} cutoff of 2.53 (sensitivity 89%, specificity 81%, AUC 0.855) and TBR_{mean} cutoff of 1.90 (sensitivity 93%, specificity 77%, AUC 0.847) for differentiating recurrent glioma from radio necrosis. TAC analysis showed moderate sensitivity (57%) but high specificity (81%), and a significant association (OR 5.67, 95% CI 1.51-21.25; Fisher's $p = 0.009$) with the outcome.


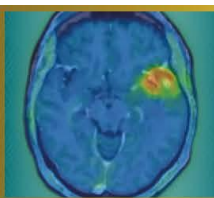
Discussions and conclusion

In this preliminary analysis, LAFOV [18F]FET PET/CT demonstrated high diagnostic accuracy for differentiating tumour recurrence from radionecrosis. The identified cutoff values were comparable to currently established TBR thresholds used in clinical practice, indicating consistent quantitative performance with LAFOV imaging.



Receiver Operating Characteristic (ROC) Curve





Abstract Number: 40

Abstract Title: Follow-up on the preclinical evaluation of [¹⁸F]AG-120, a radiotracer for the detection of the mutant isocitrate dehydrogenase 1 in a rat model of glioma

Authors:

Barbara Wenzel¹, Lisa Wiesner¹, Winnie Deuther-Conrad¹, Sebastian Greiser², Stadjana Dukić-Stefanović¹, Rodrigo Teodoro¹, Andreas Maurer¹, Klaus Kopka^{1,3}, Tareq A. Juratli^{4,5}, Thu Hang Lai⁶, **Magali Toussaint**¹

¹Helmholtz-Zentrum Dresden-Rossendorf, Institute of Radiopharmaceutical Cancer Research, Department of Experimental Neurooncological Radiopharmacy, Leipzig, Germany, ²Fraunhofer Institute for Cell Therapy and Immunology, Leipzig, Germany, ³Technische Universität Dresden, School of Science, Faculty of Chemistry and Food Chemistry, Dresden, Germany, ⁴National Center for Tumor Diseases (NCT) Dresden, University Hospital Carl Gustav Carus, Dresden, Germany, ⁵Department of Neurosurgery, Faculty of Medicine and University Hospital Carl Gustav Carus, Technische Universität Dresden, Dresden, Germany, ⁶ROTOP Pharmaka GmbH, Dresden, Germany

Background

In this interim analysis, we propose an update on our previous published work aiming at developing a radioligand to noninvasively and quantitatively detect IDH1R132H by PET. We previously demonstrated in vitro the selective uptake of [¹⁸F]AG-120 with no saturation up to two-hours. The one-hour PET scans performed in U251-IDH1 or U251-IDH1R132H glioma models, demonstrated a slightly higher retention in the latter (Tumor-to-Background Ratio TBR[30-60min]: ~1.1 vs. ~1.6).

Methods

Here, we further investigate the in vivo kinetic of [¹⁸F]AG-120, by performing two-hours PET scans and inspecting a potential influence of vascularization discrepancies between the two models on the radioligand uptake. The dynamic PET scans (NanoScan® PET/MR, Mediso) were performed in nude rats bearing orthotopic U251-IDH1 (n=8) or U251-IDH1R132H (n=8) gliomas. The tumor perfusion was evaluated by dynamic contrast-enhanced MRI (Pharmascan 7T, Bruker) and immunofluorescent CD31 staining.

Results

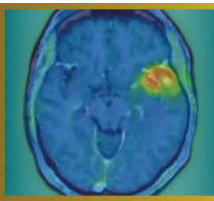
On the day of PET, the U251-IDH1 and U251-IDH1R132H tumors presented a volume of 20±7 mm³ and 15±5 mm³, respectively. Both tumor models exhibited similar TBR at the later time points (TBR[90-120min]: 1.1±0.2 vs. 1.3±0.3). The perfusion curves demonstrated similar features as well, with a mean-transit-time of 7.4±3.1 min vs. 6.4±2.3 min and an elimination constant of 0.16±0.06 min⁻¹ vs. 0.17±0.05 min⁻¹ respectively. Finally, the CD31 staining highlighted a lower vascularization pattern in both tumor models compared to the brain-adjacent-tumor tissue.

Conclusions

To conclude, the two tumor models present similar perfusion pattern, excluding perfusion as confounding factor in radioligand accumulation. Although the in vitro kinetics of [¹⁸F]AG-120 suggested that longer PET acquisition could lead to a clearer distinction between mutant- and wildtype-IDH1 tumors, this result was not reproducible in the more complex in vivo environment.

Acknowledgements: We thank Dr. Kessler and Prof. Vordermark, Department of Radiotherapy, Martin Luther University Halle-Wittenberg, for providing the cells.

Disclosure Information: This work was funded by the the European-Regional-Development-Fund and the Sächsische-Aufbaubank.



Abstract Number: 42

Abstract Title: Prognostic relevance of FET PET in patients with newly diagnosed glioblastoma

Authors:

Jan-Michael Werner¹, Katharina J. Müller², Maximilian J. Mair³, PD Dr. med. Michael Mütter⁴, Wolfgang Roll⁵, Jana-Marie Peplinski¹, Manuel Kraft¹, Julia Hilgers⁶, Keith G. Ciantar⁶, Christoph Kabbasch⁷, Anna S. Berghoff³, Gereon R. Fink^{1,6}, Roland Goldbrunner⁸, Nadim J. Shah⁶, Felix M. Mottaghy⁹, Karl-Josef Langen^{6,9}, Philipp Lohmann^{6,9}, Matthias Preusser³, Norbert Galldiks^{1,6}, Nathalie L. Albert¹⁰

¹Dept. of Neurology, Faculty of Medicine and University Hospital Cologne, Cologne, Germany, ²Dept. of Neurology, LMU University Hospital, LMU Munich, Munich, Germany, ³Division of Oncology, Department of Medicine I, Medical University of Vienna, Vienna, Austria, ⁴Department of Neurosurgery, University Hospital Münster, Münster, Germany, ⁵Department of Nuclear Medicine, University Hospital Münster, Münster, Germany, ⁶Inst. of Neuroscience and Medicine (INM-3, INM-4), Research Center Juelich, Juelich, Germany, ⁷Inst. of Radiology, Division of Neuroradiology, Faculty of Medicine and University Hospital Cologne, Germany, ⁸Dept. of Neurosurgery, Faculty of Medicine and University Hospital Cologne, Cologne, Germany, ⁹Dept. of Nuclear Medicine, University Hospital RWTH Aachen, Aachen, Germany, ¹⁰Dept. of Nuclear Medicine, LMU University Hospital, LMU Munich, Munich, Germany

Background

The present study investigates the prognostic relevance of O-(2-[¹⁸F]fluoroethyl)-L-tyrosine (FET) PET parameters in newly diagnosed glioblastoma.

Methods


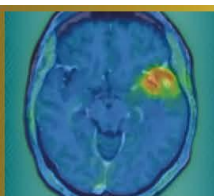
In this retrospective multicenter study, 125 patients with newly diagnosed glioblastoma according to the WHO 2021 classification were included. Patients received FET PET imaging before surgery or after biopsy prior to first-line treatment with radiotherapy alone (n=11), concomitant and adjuvant temozolomide (n=86), or temozolomide plus lomustine (n=28). FET PET-positive tumor volumes were segmented semi-automatically or using the nnUNet-based JuST_BrainPET based on a tumor-to-brain ratio (TBR) of ≥ 1.6 . All segmentations were visually checked. Quantitative PET parameters, i.e., maximum and mean TBR values, and PET-positive volumes (PET-Vol), were correlated with overall survival (OS) using Cox regression models. Additional clinical parameters included age (range, 21-86 years), MGMT promoter methylation status (hypermethylated in 60% of patients), extent of resection, and first-line treatment regimen. The Cutoff Finder web tool (maximally selected log-rank/Cox split) was used to derive an outcome-optimized threshold from continuous variables for OS stratification.

Results

In univariate Cox regression, PET-Vol (hazard ratio [HR], 1.02 per mL; 95% CI, 1.01-1.03; $p < 0.001$), radiotherapy alone (HR, 6.44; 95% CI, 2.00-17.73; $p = 0.003$), and unmethylated MGMT promoter (HR, 2.11; 95% CI, 1.26-3.49; $p = 0.005$) were significantly associated with shorter OS. In multivariable Cox regression, PET-Vol emerged as the strongest independent prognostic parameter, showing the largest contribution to model fit (HR=1.03 per mL, 95% CI, 1.01-1.04; $p < 0.001$), outperforming MGMT promoter methylation status ($p = 0.004$) and applied treatment ($p = 0.014$). At exploratory analysis, the optimal cutoff for risk stratification using PET-Vol was 39 mL (HR, 4.00; 95% CI, 2.17-7.37). PET-Vol > 39 mL was associated with a significantly shorter OS (8 vs. 27 months; $p < 0.001$).

Conclusion

These data support the integration of the FET PET tumor volume as a prognostic biomarker in glioblastoma risk stratification. Further studies with larger datasets are needed to substantiate our findings.



Abstract Number: 44

Abstract Title: Virtual postoperative 18F-FET-PET imaging as a surrogate imaging modality in recurrent glioblastoma assessment

Authors:

Jocelyn Castille¹, Dr. Wietse Geens¹, Dr. Iris Dirven², Dr. Cleo Bertels², Prof. dr. Michaël Bruneau¹, Anass Hamdi³, Prof. dr. ir. Jef Vandemeulebroecke⁴, Prof. dr. Bart Neyns², Ir. Laurens Raes³, Prof. dr. Hendrik Everaert³, Prof. dr. Johnny Duerinck¹

¹University Hospital Brussels, department of neurosurgery, Brussels, Belgium, ²University Hospital Brussels, department of oncology, Brussels, Belgium, ³University Hospital Brussels, department of nuclear medicine, Belgium, ⁴Free University of Brussels, department of electronics and informatics, Belgium

Background

The prognostic role of O-(2-[18F]fluoroethyl)-L-tyrosine PET-derived (18F-FET PET) imaging parameters in recurrent glioblastoma (rGBM) are increasingly being recognized, but often only preoperative FET-PET is available. We investigated whether virtual postoperative FET-PET parameters predict overall survival (OS) after re-operation and whether the virtual FET-PET signal predicts recurrence location.

Materials and Methods

We retrospectively analyzed 61 patients with rGBM who underwent re-operation followed by intracerebral immunotherapy within a single-center clinical trial. Pre- and postoperative-MRI and preoperative 18F-FET-PET data were available for 49 patients. Virtual postoperative FET MTV was generated by co-registering preoperative FET-PET to postoperative MRI, subtracting the resection cavity and non-tumoral postoperative changes, and quantifying the remaining metabolic tumor volume and static parameters. Univariate and multivariate Cox proportional hazards regression analyses were performed to assess associations with OS from the time of recurrence. Subsequently, a qualitative analysis examined the relationship between the virtual FET-PET signal and rGBM recurrence localization.

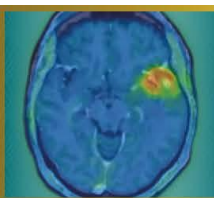
Results

On univariate analysis, virtual postoperative FET MTV was significantly associated with OS (HR 1.03, p=0.017), whereas residual CE volume was not (HR 1.07, p=0.090). In multivariate analysis adjusted for KPS and corticosteroid use, FET MTV showed a trend toward independent prognostic significance (HR 1.025, p=0.053), while residual CE volume did not (HR 1.041, p=0.385). The FET MTV-based model demonstrated superior fit compared with the CE volume-based model (AIC 289.9 vs 292.5).

The virtual FET-PET signal accurately predicted glioblastoma recurrence localization in exactly 80% of cases.

Conclusion

Virtual postoperative residual 18F-FET-PET metabolic tumor volume appears to be a stronger prognosticator of OS than conventional MRI-based residual CE volume in rGBM patients that received intracerebral immunotherapy. Spatial localization of residual FET-activity is often indicative of location of later recurrence. Validation in larger cohorts and comparison with actual postoperative FET-PET is warranted.



Abstract Number: 45

Abstract Title: Early-dominant TSR kinetics on dynamic F-DOPA PET: a radiotherapy-relevant biomarker for glioma recurrence

Authors:

Gabor Sipka¹, Kristof Apro¹, Zsofia Miko¹, Bernadett Bardoczi¹, Gyöngyi Kelemen², Katalin Hideghety², Zsuzsanna Besenyi¹

¹University Of Szeged, Department of Nuclear Medicine, Szeged, Hungary, ²University of Szeged, Department of Oncotherapy, Szeged, Hungary

Background

Dynamic 18F-FDOPA PET provides temporal information beyond static uptake metrics; however, clinically robust kinetic biomarkers applicable to radiotherapy planning remain insufficiently defined. We evaluated tumor-to-striatum ratio (TSR)-based dynamic parameters focusing on early kinetic behaviour, ROI-independent stability, and potential protocol simplification.

Material and Methods

In this retrospective study, dynamic FDOPA PET scans of 42 histologically confirmed glioma patients (57 PET-positive lesions) were analyzed in a lesion-based exploratory cohort. Tumor lesion delineation was performed based on MRI guidance. Recurrence versus treatment-related change was determined through multidisciplinary validation with ≥ 3 -year follow-up including MRI, histopathology when available, and clinical course. TSR time-activity curves were derived from 25-minute acquisitions. Early (5–10 min) and late (20–25 min) phase averages were calculated across SUVmax, SUVmean, and SUVpeak. Derived parameters included Early-to-Late Ratio (ELR), Washout Index (WI), Early Rise Index, and linear TSR slope. ROI robustness was assessed using coefficient-of-variation analysis.

Results

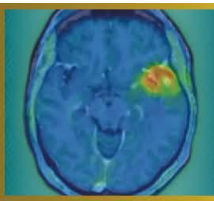
Recurrence lesions predominantly demonstrated early-dominant TSR kinetics, observed in 37/47 lesions (~79%), characterized by rapid tumor uptake preceding progressive striatal activity. ELR showed substantially higher ROI-independent stability than WI (median CV: 0.0468 vs. 0.263). Median ELR values were consistent across SUVmax (1.23), SUVmean (1.19), and SUVpeak (1.24), whereas WI demonstrated greater dispersion (35.6%, 23.2%, and 29.7%, respectively). Linear TSR slope and Early Rise Index reflected rapid uptake dynamics but were more sensitive to peak timing. TSR-derived parameters were reproducible from early and late phase averages.

Discussion

These findings indicate a reproducible early-dominant recurrence phenotype and suggest that clinically relevant kinetic information may be captured using simplified dual-time-window imaging.

Conclusion

Dynamic TSR analysis identifies ELR as a stable, ROI-robust FDOPA biomarker potentially highlighting biologically active recurrence regions relevant for radiotherapy boost delineation. Early-phase imaging combined with dual-time-point acquisition may support biologically guided radiotherapy workflows. Prospective validation is warranted.



Abstract Number: 46

Abstract Title: Multi-pinhole SPECT/CT for meningioma imaging: a novel diagnostic approach

Authors:

Kristóf Apró¹, László Pávics¹, Melinda Szolikova^{1,2}, Ágnes Dobi³, Katalin Hideghéty³, Márton Balázsfői⁴, Pál Barzó⁴, Gábor Sipka¹, Zsuzsanna Besenyi¹

¹Department of Nuclear Medicine and Theranostics, Albert Szent-Györgyi Medical School, University of Szeged, Hungary, Szeged, Hungary, ²Mediso Medical Imaging Systems Ltd, Budapest, Hungary, Budapest, Hungary, ³Department of Oncotherapy, Albert Szent-Györgyi Medical School, University of Szeged, Hungary, Szeged, Hungary, ⁴Department of Neurosurgery, Albert Szent-Györgyi Medical School, University of Szeged, Hungary, Szeged, Hungary

Background

Meningiomas are the most common primary brain tumors in adults and are associated with a substantial risk of recurrence despite typically slow growth. Overexpression of somatostatin receptor subtype 2 (SSTR2) enables targeted imaging using somatostatin analogues. This prospective study evaluates the diagnostic performance of SSTR SPECT/CT acquired with parallel-hole (PH) and multi-pinhole (MPH) collimators, using contrast-enhanced MRI as the reference standard in patients with clinically progressive, histologically confirmed World Health Organization (WHO) Grade I–III meningiomas.

Material and Methods

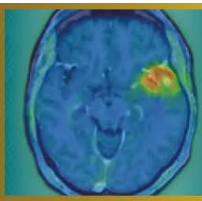
Nineteen patients underwent SSTR-targeted SPECT/CT imaging using [^{99m}Tc]Tc-EDDA-HYNIC-TOC (AnyScan TRIO SPECT/CT/PET imaging system, Mediso). Sequential acquisitions were performed with a multi-pinhole collimator followed by a parallel-hole collimator. SPECT/CT datasets were co-registered with contrast-enhanced T1-weighted MRI for tumor delineation. Lesion number, spatial extent, and osseous involvement were compared across modalities. Semi-quantitative analyses were conducted including SUVmax, SUVmean, and tumor-to-background ratio (TBR) in InterView FUSION software (Mediso).

Results

Multi-pinhole SPECT/CT detected 36 lesions, compared with 33 lesions on MRI (91.7%) and 26 lesions on parallel-hole SPECT/CT (72%). All lesions were confirmed during follow-up by MRI or histology. MPH-SPECT/CT identified additional multinodular disease and detected bone infiltration in ten lesions, compared with five identified by MRI. Semi-quantitative analysis demonstrated significantly higher tracer uptake and TBR values in MPH acquisitions than in parallel-hole studies (SUVmean, $p = 0.001$; SUVmax, $p = 0.001$; paired t-test).

Conclusion

Multi-pinhole SSTR SPECT/CT shows excellent diagnostic performance for meningioma detection and improves assessment of lesion multiplicity and osseous involvement compared with conventional approaches. Advanced SPECT methodology may help narrow the diagnostic gap between conventional SPECT and PET imaging and represents a practical alternative in selected clinical settings.



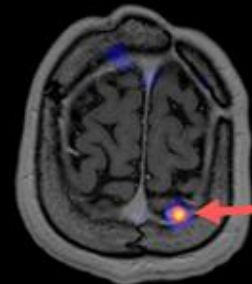
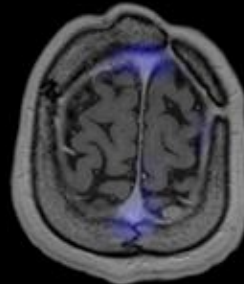
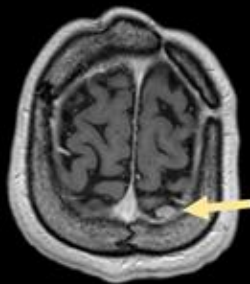
MRI

LEHR-SPECT

MPH-SPECT

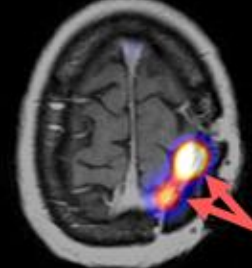
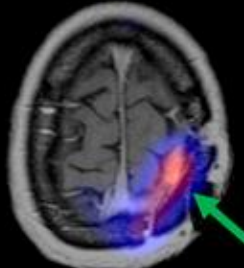
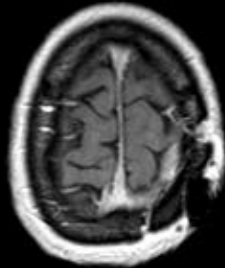
A)

MRI +
LEHR -
MPH +



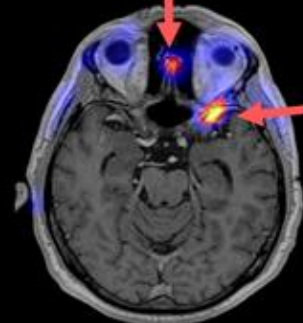
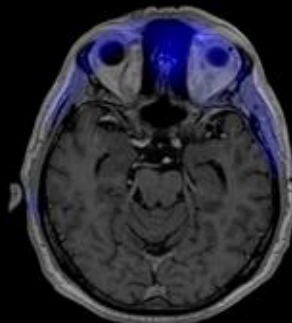
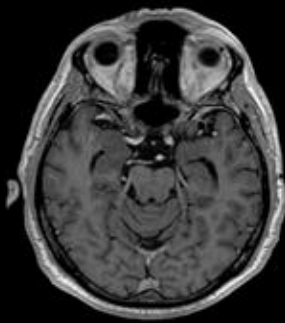
B)

MRI -
LEHR +
MPH +



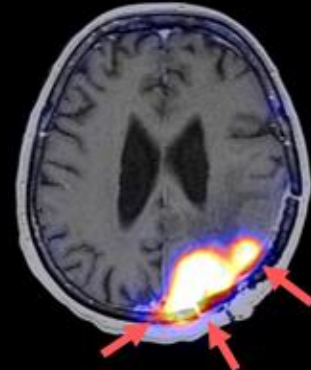
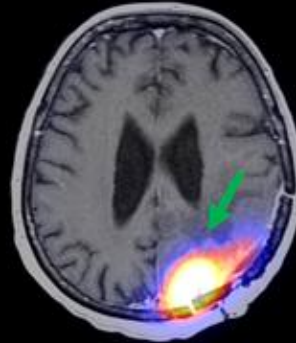
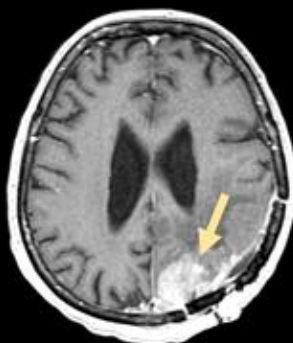
C)

MRI -
LEHR -
MPH +



D)

MRI +
LEHR +
MPH ++
**(additional
informations)*



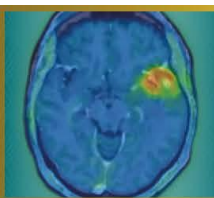
From left to right: contrast-enhanced T1-weighted MRI ; MRI-SPECT fusion with LEHR (low-energy,high-resolution) collimator, MRI-SPECT fusion with MPH (multi-pinhole) collimator.

Radiopharmaceutical: ^{99m}Tc -EDDA/HYNIC-TOC (Tektrotyd®)

'+' indicates detected meningioma, '-' indicates no detection.

Yellow arrow indicates meningioma detected by MRI; green arrow by LEHR-SPECT; red arrow by MPH-SPECT.

* midline crossing, bone infiltration, other meningeal involvement



Abstract Number: 47

Abstract Title: ReSPECT-LM: Pharmacokinetic and Pharmacodynamic assessment of Reyobiq in Leptomeningeal Metastases

Authors:

Andrew Brenner¹

¹University of Texas Health San Antonio, San Antonio, United States, ²Mays Cancer Center at UT Health San Antonio, SAN ANTONIO, United States

Background

Rhenium obisbameda (186RNL, REYOBIQ) is 186Re encapsulated in liposomal nanoparticles. We reported excellent safety and promising activity for 186RNL in leptomeningeal metastases (LM). The recommended phase-2 single dose was 44mCi with an MTD of 66mCi. We now report the pharmacokinetic and pharmacodynamic results.

Methods


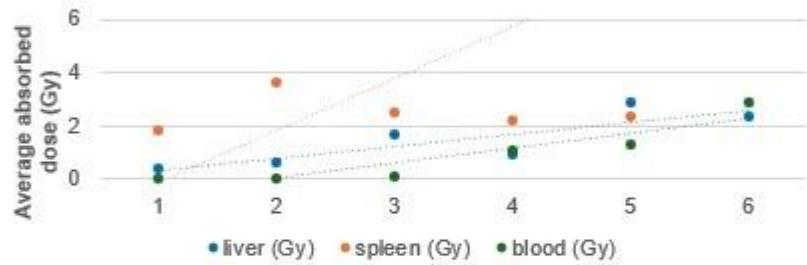
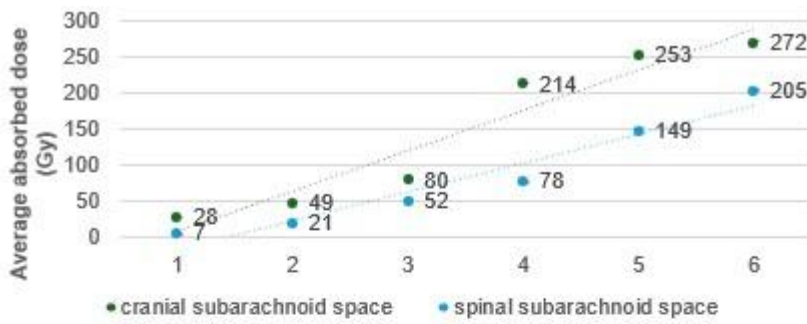
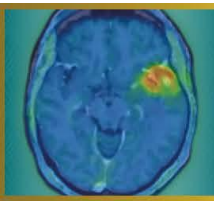
Planar imaging was performed postdose, and 24-168hrs. Computations of target and normal organ doses were performed using OLINDA/EXM. CSF was collected at baseline, 8, 24, 48hrs; days 14 and 28. Cells underwent immediate processing and batch RNA-sequencing. To further characterize immunologic changes, an ID8agg/C57BL6 model was used.

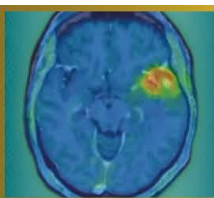
Results

A linear dose response was observed from average 28Gy-272Gy and 7-205Gy to the cranial and spinal subarachnoid spaces respectively. Organ absorbed doses were 1-3Gy average liver, 2-6Gy spleen, and 0-3Gy blood. RNAseq of CSF samples (n=60 from 11 patients) revealed two distinct temporal gene expression patterns: early inflammation/innate immune cluster and subsequent proliferation/DNA repair cluster. Immune deconvolution demonstrated a delayed adaptive immune response driven primarily by CD8 T-cells across multiple timepoints, suggesting immune remodeling rather than acute exhaustion following 186RNL. Characterization of biological response in ID8agg ascites demonstrated that combination therapy with 186RNL and anti-PD1 induced a CD8-dominant immune response with increased activated CD8+ T-cells (CD69+, CD25+), preferential expansion of CD4+ effector T-cells over regulatory T-cells, and enhanced NK-cell populations while reducing monocytes. Combination therapy resulted in superior tumor control (p=0.008) and evidence of reduced omental tumor burden.

Conclusions

186RNL safely achieves absorbed doses to LM over 8-fold conventional EBRT. In addition to tumor cells responses (apoptosis, G2M arrest), bulk RNAseq of CSF reveals temporal immune remodeling with delayed CD8 T-cell engagement following 186RNL, while flow cytometry of ovarian ascites confirms that this CD8-dominant adaptive response is functionally enhanced and therapeutically leveraged through anti-PD1 combination therapy. Further evaluation is ongoing in a repeated dosing trial (ReSPECT-LMM, NCT07098806).





Abstract Number: 48

Abstract Title: PET-Based Dosimetry of Intra-Arterial Y-90 Neurovascular Radiotherapy in Recurrent Glioblastoma: First-in-Human Feasibility

Authors:

Dr. Kazim Narsinh², Dr. Nicholas Butowski², Dr. Sam Mouli³, Dr. Sameer Ansari³, Dr. Matthew Tate³, Dr. Rimas Lukas³, Dr. Jonathan Weinstein⁴, Dr. Yafell Serulle⁴, Dr. John Boockvar⁴, Mr. Matthew Dreher¹, Amanda Eldridge¹, Mr. Paul Kennedy¹, Ms. Samantha Ryan¹, Mr. Franco Basarabescu¹, Mr. Mohammed Goryawala¹, Dr. Riad Salem³, Dr. Roger Stupp³

¹Boston Scientific, Maple Grove, United States, ²University of California San Francisco, San Francisco, United States, ³Northwestern Memorial Hospital, Chicago, United States, ⁴Lenox Hill Hospital Northwell Health, New York City, United States

Background

Treatment options for recurrent glioblastoma (rGBM) are limited. Neurovascular radiotherapy (NVRT) is a novel intra-arterial approach using glass yttrium-90 (Y-90) microspheres (TheraSphere™, Boston Scientific) to superselectively deliver high-dose radiation to malignancy. The FRONTIER trial is the first trial to adapt this technology to treat rGBM.

Methods

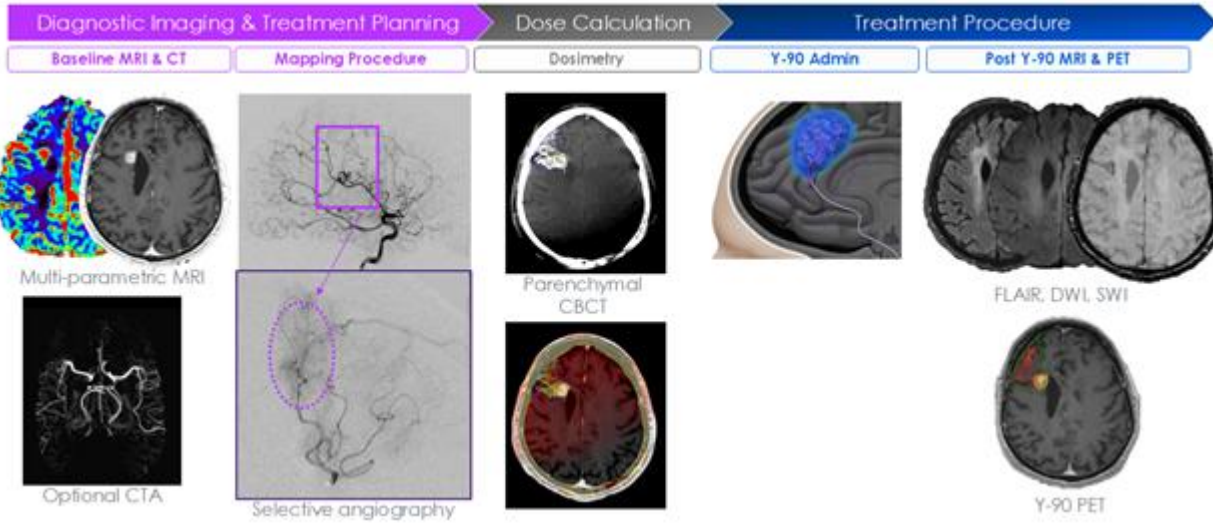
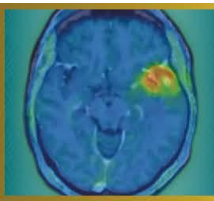
Multicenter, phase-1 study evaluating safety, feasibility, technical success, and quantitative dosimetry of NVRT in rGBM patients. Patients with 1-5cm diameter contrast-enhancing disease located in non-dominant, non-eloquent brain regions, who received ≤two prior lines of therapy underwent angiographic assessment. Patients were deemed eligible if perfused volume (PV) encompassed enhancing-disease without involving dominant/eloquent regions. Eligible patients underwent NVRT targeting 40Gy absorbed dose (AD) to the PV. Y-90-PET imaging performed within 36-hours post-treatment enabled quantification of AD distribution. Technical success was defined as achieving an AD within ±20% of the prescribed target. PET-based dosimetry and correlation with clinical outcomes were analyzed.

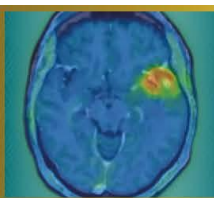
Results

Twenty patients underwent feasibility angiography, and 12 proceeded to NVRT. Technical success was achieved in all patients. Y-90-PET confirmed ≥96% of activity was confined to PV with a median AD of 41.5Gy. Dose to enhancing and non-enhancing volumes within PV was 124.2Gy (range 58.5-508.5Gy) and 36.3Gy, respectively, with a median tumor-normal-ratio of 3.8. No device-related adverse events (grade ≥3) or symptomatic radiation necrosis were reported throughout follow-up (median 12.1 months). Patients with tumor AD above the median (>124Gy) had improved OS (median 11.9 vs 5.7 months, Log-Rank p=0.0073).

Conclusions

Quantitative PET-based dosimetry confirmed delivery of Y-90 microspheres to the treatment volume with preferential deposition in rGBM, achieving tumor ADs greatly exceeding those feasible with EBRT while maintaining an acceptable safety profile. This imaging-guided workflow was successfully reproduced across 3 sites, demonstrating technical feasibility and establishing proof-of-concept for NVRT in rGBM. Future studies will refine dose planning and response modeling to optimize therapeutic efficacy.





Abstract Number: 49

Abstract Title: A Semi-Automated Approach to Glioblastoma Delineation on [18F]FET PET to Improve Automated Segmentation

Authors:

Anass Hamdi^{1,2}, Selene De Sutter¹, Ir. Laurens Raes³, Dr. Wietse Geens⁴, Prof. dr. Hendrik Everaert³, Sophie Bourgeois³, Pieter Boonen^{1,5}, Jef Vandemeulebroucke^{1,5,6}, Ine Dirks^{1,6}, Prof. dr. Johnny Duerinck⁴

¹Department of Electronics and Informatics (ETRO), Vrije Universiteit Brussel, Brussels, Belgium, ²Fonds Wetenschappelijk Onderzoek (FWO), Brussels, Belgium, ³Department of Nuclear Medicine, Vrije Universiteit Brussel, Universitair Ziekenhuis Brussel, Brussels, Belgium, ⁴Department of Neurosurgery, Vrije Universiteit Brussel, Universitair Ziekenhuis Brussel, Leuven, Belgium, ⁵Department of Radiology, Vrije Universiteit Brussel, Universitair Ziekenhuis Brussel, Brussels, Belgium, ⁶Imec, Leuven, Belgium

Background

Glioblastoma delineation guidelines on [18F]FET PET include background estimation through crescent VOI annotation and a spherical VOI enclosing the tumor. This approach shows high interobserver variability, causing diagnostic uncertainty and limiting performance of automated segmentation trained on such annotations.

Methods

We present a semi-automated method for background estimation based on the contralateral side of a brain mask relative to the midsagittal plane. Background activity was estimated through linear regression relating the median SUV of this ROI to crescent VOI measurements. We evaluated the method on an in-house UZ Brussel [18F]FET PET cohort of 174 patients (85 newly diagnosed, 89 recurrent) where the mean MTV was 32.1 ± 32.3 mL. Four experts (HE, SB, LR, WG) provided manual annotations according to PET RANO 1.0, leading to two annotations per image. We evaluated our method by comparing its performance to manual annotations in terms of interobserver variability and concordance of deep segmentation models when trained on the respective annotations. A 3D nnU-Net is used for segmentation.

Results

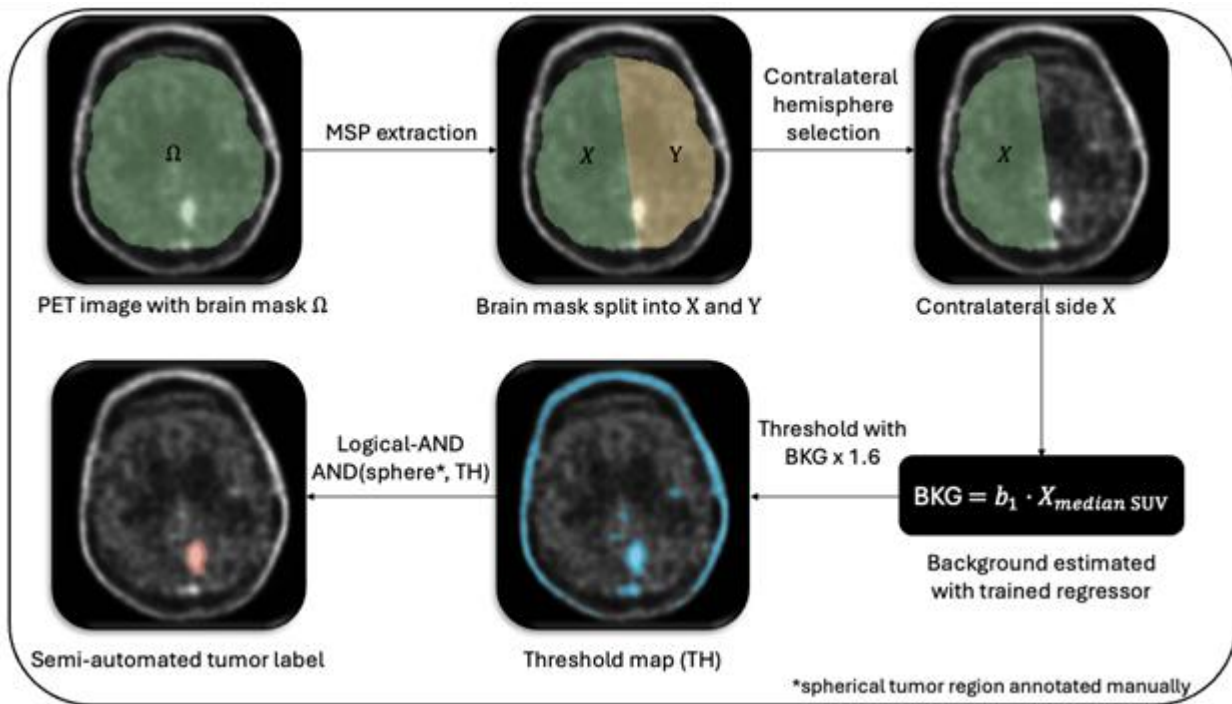
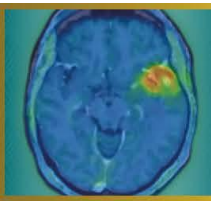
Results, reported as median (IQR), show manual and semi-automated delineations of the same annotator aligned closely with DSC 0.919 (0.162). However, interobserver variability showed DSC 0.882 (0.116) vs 0.787 (0.211) and AVE 2.899 (5.155) mL vs 4.270 (9.340) mL (semi-automated vs manual). Finally, nnU-Net trained on semi-automated annotations achieved DSC 0.871 (0.200) vs 0.772 (0.248) when trained on manual annotations.

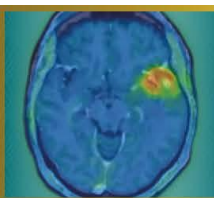
Discussion

Automated background estimation reduced interobserver variability of semi-automated delineations, highlighting the importance of this step in the delineation procedure. This translated into better nnU-Net segmentation performance (median DSC=0.88), exceeding the state-of-the-art [18F]FET PET automated segmentation (median DSC=0.83).

Conclusion

We propose a semi-automated approach to glioblastoma delineation on [18F]FET PET, which reduces interobserver variability and leads to more consistent automated segmentation. Future work should assess accuracy with respect to biological ground truth.





Abstract Number: 50

Abstract Title: Radiographic regression of parenchymal brain metastases after PRRT in metastatic well-differentiated neuroendocrine tumor: a case study

Authors:

Joshua Qian¹, Zoe Goldberg¹, Ross Weber¹, Kaitlyn Lapen¹, Alexander Terry¹, Daniel Gorovets¹, Lisa Bodei¹, Brandon Imber¹

¹Memorial Sloan Kettering Cancer Center, New York City, United States

Background

The suitability of radiopharmaceutical therapies, including peptide receptor radionuclide therapy (PRRT) for intracranial parenchymal metastases from well-differentiated (WD) neuroendocrine tumors (NETs) is poorly defined. While surgical resection and/or stereotactic radiosurgery (SRS) are standard of care, PRRT may be an option for addressing small, multiple asymptomatic intraparenchymal metastases. Despite precedents in meningioma, data on somatostatin receptor (SSTR)-directed radionuclide therapy in intraparenchymal metastases are essentially nonexistent, given their rarity. We describe the radiographic response of cerebellar metastases after ¹⁷⁷Lu-DOTATATE therapy in a patient with metastatic WD NET.

Material and Methods

A 68-year-old woman with metastatic WD ileal NET (diagnosed 2012, later metastatic to liver, peritoneum, adnexa, and bone) previously received somatostatin analogs and PRRT (4 cycles, 2022) with favorable systemic response. She experienced extreme fatigue on octreotide and had treatment break (Aug 2024-July 2025). After resuming lanreotide, ⁶⁸Ga-DOTATATE PET/CT demonstrated new intensely octreotide-avid punctate posterior fossa lesions (SUVmax 5.1-15.8) and extracranial disease (including bones, intraabdominal nodes, peritoneal implants; size range: 1.1-3.3cm; SUVmax 9.1-44.9; Figure 1a). MRI confirmed multiple sub-centimeter (range: 0.3-0.6cm) enhancing cerebellar lesions suspicious for metastases without edema. Given small asymptomatic lesions, strong DOTATATE avidity, and plan for additional PRRT, multidisciplinary consensus elected observation with short-interval MRI rather than upfront SRS. The patient proceeded with ¹⁷⁷Lu-DOTATATE.

Results

After 1 cycle of PRRT, MRI showed decrease in size of four cerebellar enhancing metastases (largest reduced from 0.6×0.6cm to 0.4×0.3cm; Figure 1b) with no new parenchymal or leptomeningeal enhancement and no suspicious perfusion increase. The patient remained neurologically asymptomatic; reported toxicity was limited to mild fatigue and alopecia. Repeat MRI after two additional cycles is planned.

Conclusion

Octreotide-avid cerebellar parenchymal metastases demonstrated early radiographic regression after PRRT. Given SSTR expression can occur in histologies beyond NETs, this observation highlights a potential role for SSTR-directed PRRT in select patients and warrants further study.

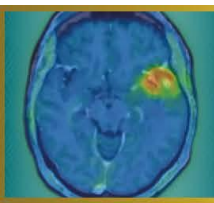
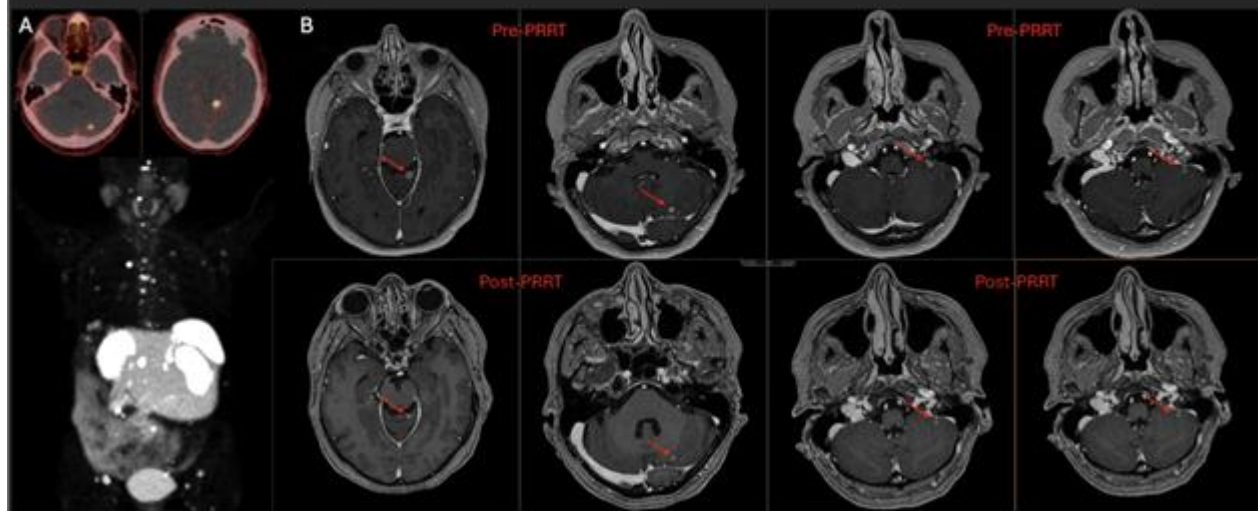
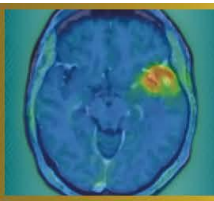


Figure 1. (A) Whole-body ^{68}Ga -DOTATATE PET/CT axial slices of two intraparenchymal brain metastases and maximum intensity projection showing somatostatin receptor-avid metastatic disease. (B) Representative axial post-contrast T1 MP-RAGE MRI demonstrating interval decrease in size of sub-centimeter cerebellar metastases pre-PRRT versus post-PRRT (^{177}Lu -DOTATATE).





Abstract Number: 51

Abstract Title: Multimodal Imaging: MRI and ⁶⁸Ga-DOTA-TATE PET/CT for Detection of Residual Meningioma with Transverse Sinus Invasion

Authors:

Elif Reyhan Aslan¹, Nazım Coşkun¹, Turan Kaya², Mehmet Burak Bölükbaşı³, Fevziye İlknur Kayalı³, Servet Güreşçi⁴, Elif Özdemir¹

¹Ankara Bilkent City Hospital Department of Nuclear Medicine, Ankara, Türkiye, ²Ankara Bilkent City Hospital Department of Radiology, Ankara, Türkiye, ³Ankara Bilkent City Hospital Department of Radiation Oncology, Ankara, Türkiye, ⁴Ankara Bilkent City Hospital Department of Pathology, Ankara, Türkiye

Background

Venous sinus invasion represents a critical prognostic and surgical challenge in meningiomas, as complete resection may be limited by the need to preserve venous outflow. Postoperative contrast-enhanced Magnetic Resonance Imaging (MRI) remains the standard imaging modality; however, postoperative enhancement along the sinus may be nonspecific and cannot reliably differentiate residual tumor from postoperative changes or sinus thrombosis. Molecular imaging targeting somatostatin receptor subtype 2 (SSTR2), which is commonly expressed in meningiomas, offers the potential to differentiate viable tumor tissue from non-neoplastic postoperative changes.

Case Presentation

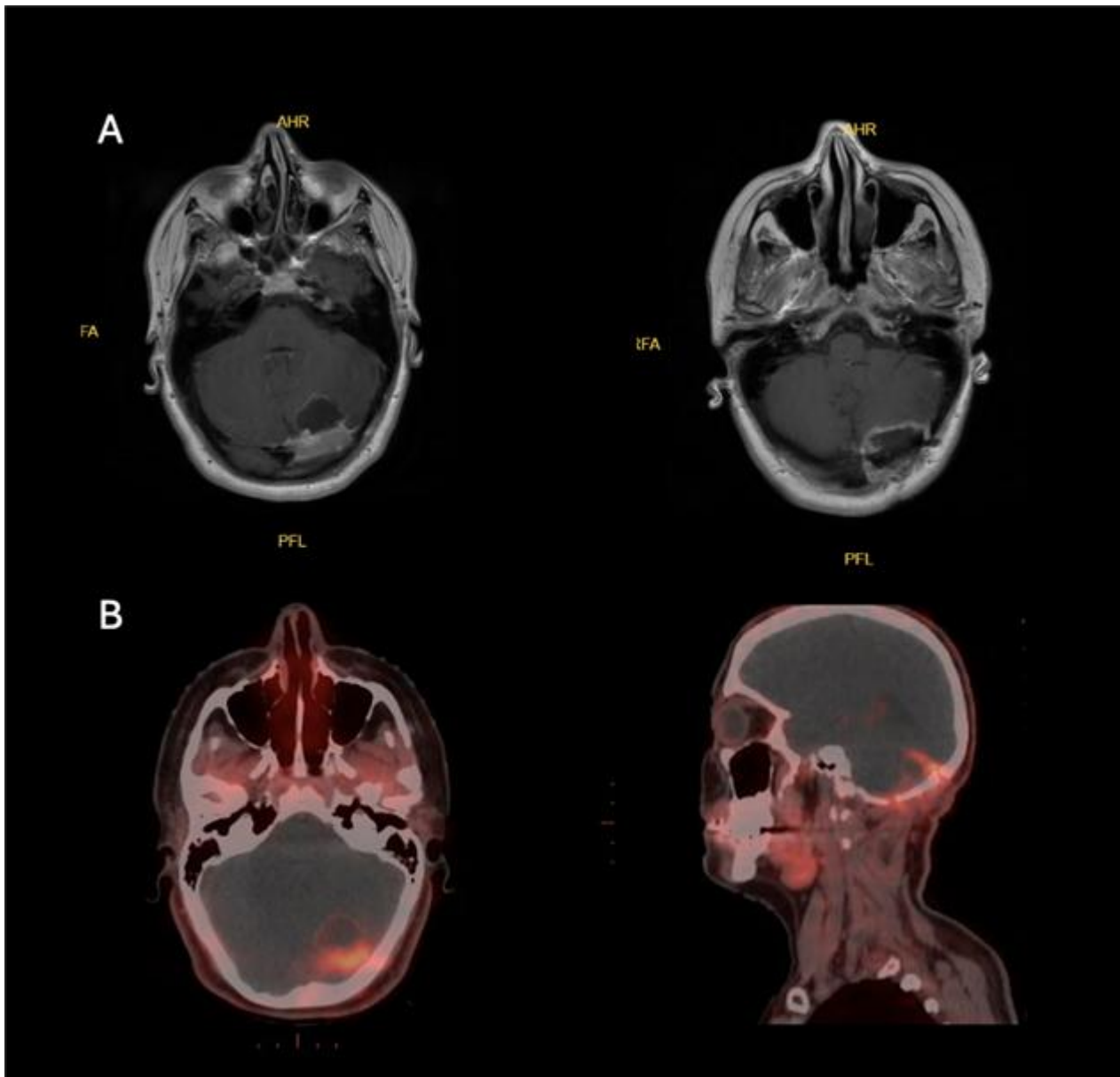
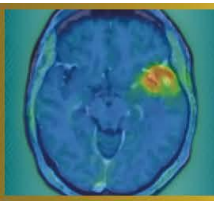
We report a 33-year-old woman who underwent surgical resection of an atypical meningioma (WHO grade II, Ki-67 proliferation index: %8-10). Postoperative MRI demonstrated indeterminate findings along the transverse sinus, precluding confident differentiation between residual tumor and thrombosis (Figure A). ⁶⁸Ga-DOTA-TATE PET/CT was performed before adjuvant treatment planning. The study demonstrated radiotracer uptake supporting the presence of residual SSTR2-expressing meningioma along the transverse sinus (Figure B).

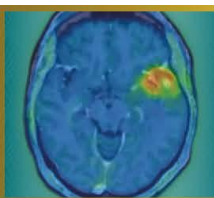
Discussion

Postoperative MRI alone often cannot reliably distinguish residual tumor from reactive changes or sinus thrombus, particularly along the venous sinus. Therefore, integration of PET/CT with MRI is important for accurate characterization and optimal treatment planning. This multimodal approach may guide adjuvant therapy and improve radiotherapy target delineation for meningiomas.

Conclusion

In meningiomas with venous sinus invasion, ⁶⁸Ga-DOTA-TATE PET/CT can offer important molecular confirmation of residual tumor when MRI findings are equivocal, potentially influencing postoperative management and improving precision in adjuvant therapy planning.





Abstract Number: 52

Abstract Title: Significant uptake of a copper-64 labelled non-specific isotype antibody by myeloid cells in the tumor microenvironment of murine glioblastoma

Authors:

Lena Wesser¹, Laura M. Bartos¹, Marlies Härtel¹, Lea H. Kunze¹, Dr. Felix Lindheimer¹, Prof. Dr. Rudolf A. Werner^{1,2}, Prof. Dr. Luisa von Baumgarten^{3,4}, Nathalie L. Albert^{1,4,5}, Dr.rer.nat. Simon Lindner^{1,6}, Matthias Brendel^{1,4,6,7}

¹Department of Nuclear Medicine, LMU University Hospital, LMU Munich, Munich, Germany, ²Russell H. Morgan Department of Radiology and Radiological Sciences, Johns Hopkins School of Medicine, Baltimore, United States of America, ³Department of Neurosurgery, University Hospital of Munich, LMU Munich, Munich, Germany, ⁴German Cancer Consortium (DKTK), Partner Site Munich, German Cancer Research Center (DKFZ), Heidelberg, Germany, ⁵Bavarian Cancer Research Center (BZKF), Erlangen, Germany, ⁶Munich Cluster of Systems Neurology (SyNergy), Munich, Germany, ⁷German Center for Neurodegenerative Diseases (DZNE), Munich, Germany

Background

Tumor-associated myeloid cells (TAMs) are pivotal components of the tumor microenvironment (TME) of glioblastoma as they display heterogenous and immunosuppressive phenotypes. This study investigates uptake of a non-specific isotype antibody in TAMs and its potential implications for cellular distribution of radiotracers.

Methods

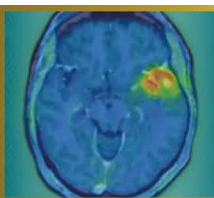
Twelve APPSAA x hTfR KI mice were inoculated with 1,000 SB28 tumor cells. Five mice received 57 ± 4 MBq of [⁶⁴Cu]Cu-NODAGA-ATV:4D9 (a brain shuttle-mediated tracer targeting myeloid cells), while seven were injected with 54 ± 1 MBq of the corresponding isotype. APPSAA mice, characterized by increased myeloid activation, were used for all conditions. The isotype antibody shares the same immunoglobulin class and subclass as the ATV:4D9, but lacks specificity for TREM2. Static PET imaging was performed 20 hours post-injection, followed by brain extraction for immunomagnetic cell sorting and gamma counting. Additionally, 16 mice without tumor inoculation received either ATV:4D9 (n=7) or the isotype (n=9) and underwent identical procedures.

Results

Tracer uptake was highest in TAMs from mice injected with ATV:4D9 ($1.05 \times 10^{-6} \pm 1.76 \times 10^{-7}$ %ID*BW per cell), but remained substantial in TAMs from mice receiving the non-specific isotype antibody ($7.38 \times 10^{-7} \pm 1.64 \times 10^{-7}$ %ID*BW per cell, i.e. 70% of the specific antibody). In mice without tumor, myeloid cell tracer uptake was significantly lower compared to glioblastoma mice (ATV:4D9: 9.9-fold lower, $p < 0.0004$; isotype: 150-fold lower, $p < 0.0001$). Myeloid cell tracer uptake strongly correlated with PET signal across all conditions ($p < 0.0001$).

Conclusion

The significant uptake of a non-specific isotype antibody in TAMs of mice with glioblastoma suggests an additional uptake mechanism, likely via phagocytosis. This effect appears specific to TAMs within the TME of glioblastoma and may generally contribute to radiotracer uptake in glioblastoma.



Abstract Number: 53

Abstract Title: Mapping of Myeloid Cells in the Tumor Microenvironment of Glioblastoma using Transport Vehicle Mediated TREM2 PET Imaging

Authors:

Laura Bartos¹, Ruoqing Feng², Katharina Müller¹, Anna Kössinger¹, Nina Teske¹, Tobias Greve¹, Jens Blobner¹, Rebecca Schaefer¹, Marlies Haertel¹, Lu Liu², Dario Dhoqina¹, Johannes Gnörich¹, Rudolf Werner¹, Veit Stoecklein¹, Florian Ringel¹, Ana-Claire Meyer³, Joseph Lewcock³, Kathryn Monroe³, Kai Schlepckow², Christian Haass², Jochen Herms¹, Nathalie Albert¹, Louisa von Baumgarten¹, Patrick Harter¹, Mikael Simons², Simon Lindner¹, Matthias Brendel¹

¹University Hospital of Munich (LMU), Munich, Germany, ²German Center for Neurodegenerative Diseases (DZNE), Munich, Germany, ³Denali Therapeutics, San Francisco, USA

Background

Glioblastoma combines a lack of immunogenicity with a highly immunosuppressive tumor microenvironment (TME), including both tumor cells and tumor-associated microglia/macrophages (TAMs). However, biomarkers that allow for specific detection, monitoring and therapy response assessment of the TAM phenotype in glioblastoma are still lacking.

Material and Methods

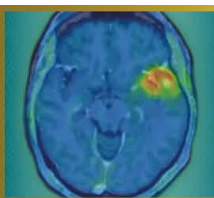
We analyzed the dynamics of TAM populations in the TME of experimental SB28 glioblastoma using single-cell RNA sequencing, immunofluorescence and molecular imaging, and identified Triggering Receptor Expressed on Myeloid Cells 2 (TREM2) as a TAM-specific target with dynamic expression across distinct tumor stages. We next evaluated a novel ⁶⁴Cu-labeled TREM2 PET tracer engineered with a blood–brain barrier transport vehicle for in vivo assessment of TAMs in the glioblastoma TME. The tracer was tested in different experimental settings, including myeloid cell depletion and TREM2 stimulation, and finally translated into a pilot cohort of patients with glioblastoma.

Results

We found strong and highly TAM-specific PET signals that followed the trajectory of TREM2 gene expression from early- towards late-stage tumors. Transient myeloid cell depletion via CSF1R inhibition showed a reduction of TREM2 PET signals compared to placebo and prolonged survival in SB28 glioblastoma mice, while TREM2 stimulation led to increased TREM2 PET signals. Translation into a pilot cohort of patients with glioblastoma revealed strong TREM2 PET signals predominantly at lesion edges, showing only partial overlap with the area of contrast enhancement in MRI or tumor volumes in amino acid PET. We observed high heterogeneity across patients, matching with the individual TREM2 immunohistochemistry.

Conclusion

TREM2 PET imaging enables specific, non-invasive assessment of TAMs in glioblastoma and is sensitive to immunomodulatory treatment effects. Thus, TREM2 PET holds promise as an immune cell-specific biomarker for personalized characterization of the glioblastoma tumor microenvironment.



Abstract Number: 54

Abstract Title: SSTR SPECT/CT volumetric changes during ^{177}Lu -DOTATATE therapy and their relation to progression and quality of life in recurrent meningioma.

Authors:

Stela Asadurova¹, Diego Gomez¹, David Sanchez¹, Cristina Auger¹, Fidel Nuñez¹, Fran Martinez¹, Esteban Cordero¹, Antonio Biroli¹, Xavier Maldonado¹, Josep Garré¹, Helena Ariño¹, Elena Martinez¹, Amparo García¹, Judith Suits¹, Carles Lorenzo¹, Cristina Gamez¹, Maria Vieito¹

¹University Hospital Vall d'Hebron, Barcelona, Spain

Background

Radioligand therapy (RLT) with ^{177}Lu -DOTATATE is currently used in recurrent meningioma, but somatostatin-receptor (SSTR) imaging dynamics data and patient-reported outcome are limited.

Material and Methods

Five patients with recurrent meningioma received four cycles RLT with ^{177}Lu -DOTATATE. Baseline ^{68}Ga -DOTATOC PET/CT was used to calculate MTV, TL-SSRE, SUVmax and Krenning score. Post-treatment SPECT/CT at each cycle (C1-C4) was performed on 360° CZT SPECT/CT gammacamera and used to calculate MTV, equivalent SUVmean and TL-SSRE. Per-patient change was assessed from first available cycle to C4. Quality of life was collected at each cycle using EORTC QLQ-BN20 and linearly transformed to 0-100 score (higher=worse). Imaging, outcome and QoL trends were explored descriptively.

Results


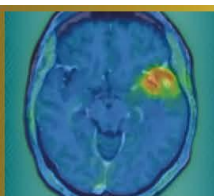
PFS-6 was 80% (4/5) with stable disease (SD) and 1 patient (20%) progressed early on treatment (PD; PFS 3.4 months). Among patients with 1-year follow-up, OS-1 was 100% (3/3). The PD case had markedly lower baseline receptor burden (PET MTV 2.44 and TL-SSRE 11.7 vs 23.3 - 107.9 and 157.7 - 782.9 in SD, respectively) and showed concordant SPECT declines to C4 (MTV -19.3%, SUVmean -14.6%, TL-SSRE -30.9%) with worsening score on BN20 (including neurological symptoms and bladder dysfunction). In SD patients, SPECT MTV and TL-SSRE increased on average (+26.6% and +28.3%; SUVmean +1.4%). BN20 total symptom burden remained low (mean 14.6 at baseline to 18.8 at C4): neurologic domains stayed low (mean 13-17) while toxicity emerged (hair loss and pruritus). One G2 patient with Krenning 4 had delayed progression (PFS 14.4 months).

Discussion

This very small cohort limits generalizability; larger prospective studies are needed to validate imaging and quality-of-life associations.

Conclusion

Very low baseline TL SSRE and falling on-treatment SPECT SSTR metrics aligned with early PD and neurologic deterioration, whereas SD (PFS-6 80%) was associated with preserved neurologic QoL despite frequent increases in SPECT-derived volumetrics and mild treatment-related symptoms.



Abstract Number: 55

Abstract Title: Targeting SSTR2 With [²¹²Pb]VMT-α-NET in meningioma patients: Design of the First in Human Phase I/IIa LEMONαDE Trial

Authors:

Nathalie Albert, Lucia Baratto, Alaa Hanna, Wenjing Yang, Steve Keefe, Markus Pulhman, Matthias Preusser¹

¹Division of Oncology, Department of Medicine I, Medical University of Vienna, Vienna, Austria

Background

[²¹²Pb]VMT-α-NET is a novel targeted alpha-particle radiopharmaceutical targeting somatostatin receptor type 2 (SSTR2)-expressing tumors. Safety and efficacy data from the dose-finding Phase 1/2a clinical trial in neuroendocrine tumors (NETs) (NCT05636618) demonstrated a favorable safety profile and signals of sustained antitumor activity at the 2.5 mCi and 5 mCi dose levels. Here, we describe the design of a first-in-human Phase I/IIa study evaluating [²¹²Pb]VMT-α-NET in patients with meningioma (LEMONαDE: [²¹²Pb]VMT-α-NET for Meningioma; NMN-03).

Materials and Methods

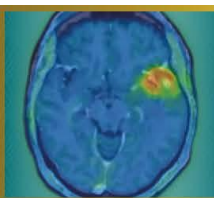
The LEMONαDE study will include up to 20 subjects with meningioma. The first 3 subjects will be enrolled in a short run-in period at a dose level of 185 MBq (5 mCi) of [²¹²Pb]VMT-α-NET for safety assessment; the remaining 17 subjects will be enrolled in a Simon's 2-stage design at a dose level deemed safe to evaluate treatment. Participants may receive up to four administrations of [²¹²Pb]VMT-α-NET at their assigned dose level, and they are monitored for dose limiting toxicities (DLTs) for 42 days and safety throughout the study. Subjects with meningioma will also participate in a dosimetry sub-study. The primary efficacy endpoint is response rate as evaluated by local investigators according to RANO meningioma criteria (null hypothesis: 5%, alternative hypothesis: 25%). Dosimetry is included as a supportive analysis.

Results

Eligible patients must have histologically confirmed meningioma of any grade, have undergone at least one prior surgical procedure (resection or biopsy), received no more than one prior line of external beam radiotherapy, and demonstrated radiographic disease progression as well as SSTR positivity on PET imaging prior to enrollment. Patients previously treated with systemic peptide receptor radionuclide therapy are excluded.

Conclusions

LEMONαDE is a first-in-human study designed to characterize safety, dosimetry, and preliminary efficacy of targeted alpha-therapy with [²¹²Pb]VMT-α-NET in meningioma. The study is not yet enrolling.



Abstract Number: 56

Abstract Title: Hijacking low-density lipoprotein receptors (LDLR) to target glioblastoma

Authors:

Izabela Tworowska¹, Leo Flores¹, Cedric Malicek², Rafal Zielinski³, Perry Davis¹, Pretty Joy¹, Pascaline Lecorche³, Jamal Temsamani³, Ebrahim Delpassand¹

¹Radiomedix, Houston, United States, ²Vect-Horus, Marseille, France, ³MDAnderson Cancer Center, Houston, United States

Background

Low-density lipoprotein-receptors (LDLR) are upregulated in glioblastoma (GBM), where they support tumor growth and altered-metabolic needs. LDLRs are also present at the blood–brain-barrier (BBB), creating an opportunity to leverage receptor-mediated-transport for the radiotheranostic applications. Here, we report results for the second-generation LDLR-targeting agent, RMX-VH-PKM, engineered to prolong blood-circulation-time and enhance tumor uptake.

Materials and Methods

The RMX-VH-PKM was labeled ²¹²Pb (4-8mCi, RAHA ²²⁴Ra/²¹²Pb generator, Radiomedix) in buffer pH=6.0/temp80°C in the presence of scavengers. Radiolabeling with ²⁰³Pb (4-5mCi, UA Cyclotron Facility) was conducted under similar conditions. SPECT/CT imaging of ²⁰³Pb/²¹²Pb-RMX-VH-PKM in U87MG- xenografts was performed at multiple time-points, followed by biodistribution studies. In parallel, pilot efficacy studies of ²¹²Pb-RMX-VH-PIB were evaluated in an orthotopic-U251 model. Mice (n = 5/group) received fractionated-dosing to achieve cumulative activities of 17.4±1uCi (cohort 1) or 33.3±2uCi (cohort 2), while control received no-treatment. Therapeutic response was assessed using PET/CT imaging with ¹⁸F-fluciclovine(Axumine), along with monitoring of body weight and clinical signs.

Results

Biodistribution studies of ²¹²Pb-RMX-VH-PKM in U87MG xenografts demonstrated sustained tumor retention, with uptake of 6.6±0.4%ID/g at 1h post-injection, decreasing to 4.8±0.6%ID/g at 3h and further to 2.7±0.6%ID/g at 24h post-injection. Administering a 40-fold excess of non-radiolabeled RMX-VH-PIB before ²⁰³Pb-RMX-VH-PKM minimally affected tumor uptake but reduced liver uptake by 42.2% at 1–3h compared to the ²⁰³Pb-analog alone. Biodistribution of ²²Pb-RMX-VH-PKM, showed a comparable distribution to the ²⁰³Pb-labeled-analogue, with the highest tumor-retention at 1-3h (13.4±5.2%ID/g and 12.4±1.6%ID/g, respectively, 6.2±2%ID/g at 24h). In pilot survival-studies using a fractionated-dosing of ²¹²Pb-RMX-VH-PIB in an orthotopic-U251-model, a statistically significant tumor growth inhibition was observed in both treatment cohorts for up-to-35days following therapy initiation.

Discussion

²⁰³Pb/²¹²Pb-RMX-VH-PIB consistently targets LDLR-expressing GBM. Adjusting specific-activity decreased uptake in liver without affecting tumor accumulation, and fractionated ²¹²Pb-RMX-VH-PKM doses produced encouraging results.

Conclusions

These results support further dosing optimization and clinical translation of the LDLR-targeted-radiotheranostics.

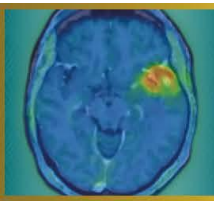


Figure 1.

a) SPECT/CT studies of ^{203}Pb -RMX-VH-PKM in U87MG xenografts acquired 3h post injection.

b) SPECT imaging of selected organs dissected during biodistribution studies done 3h post-injection

c) Blood circulation half life of ^{203}Pb -RMX-VH-PKM

