

**DIAGNOSTIC AND THERAPEUTIC INNOVATIONS  
IN THE ERA OF PRECISION MEDICINE –  
NUCLEAR MEDICINE MEETS NEURO-ONCOLOGY**

## ABSTRACTBOOK

### **NMN Symposium: Precision Medicine**

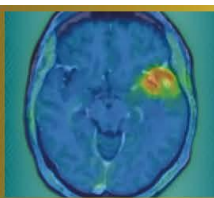
07.-08. May 2026 / Vienna, Austria  
Apothekertrakt, Schönbrunn

---

[www.nmn-society.org](http://www.nmn-society.org)

Nuclear Medicine and Neurooncology (NMN)

*Only the conflict of interests of individuals with a disclosure are included in the respective abstracts.*



**Abstract Number:2**

**Abstract Title: Features of PET/CT with FET interpretation after proton radiation therapy of patients with IDH wildtype glioblastoma**

**Authors:**

**Elena Gromova**<sup>1</sup>, Nikita Kataev<sup>1</sup>, Daniil Susin<sup>1</sup>

<sup>1</sup>Ldc Mibs, Saint-Petersburg, Russian Federation

**Background**

To identify the features of PET/CT with fluoroethyltyrosine in patients with IDH wildtype glioblastoma who received proton therapy as part of adjuvant chemoradiation treatment.

**Material/Methods**

We evaluated 17 PET/CT c FET studies in 13 patients 3-18 (median 5.5, SD 12) months after proton therapy. PET/CT was performed at the decision of the neuro-oncologist for differential diagnosis of radionecrosis and progression.

PET-CT was performed according to the standard protocol: scanning 20 min after RFP injection, scanning time 20 min. The evaluation was performed by semi-quantitative method, with TBTmax calculation, as well as with comparison with MRI data and irradiation plans.

Radiation therapy was delivered to all patients with a scanning pencil beam using 2 5/13 (38%) or 3 8/13 (62%) fields. In 10/13 (76.9%) cases, at least one of the fields was not coplanar. Two radiation therapy regimens were used: 45 Gray for 15 fractions and 60 Gray for 30 fractions (112.5-120.0 BED)

Cases of RFP hyperfixation foci outside the initial volume of high (D95%) dose were considered separately - the zones of their occurrence, correlations between the necrosis site and the direction of proton therapy fields were determined separately.


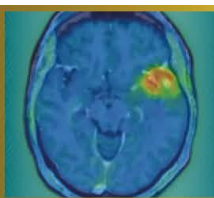
**Results**

In total, in 13 primary studies, 6 studies were interpreted as radionecrosis (TBRmax up to 2.4), 2 as disease progression (TBRmax 3.2) , 5 could not be interpreted unambiguously according to current guidelines and required dynamic follow-up.

In two cases, we encountered cases of necrosis outside the original high volume (D95%). In both cases two fields were used, in one case coplanar. In both cases, radionecrosis occurred in the paraventricular regions of the lobar lobes (TBRmax 2.3).

**Conclusion**

1. TBRmax in cases diagnosed as radionecrosis is higher than in guidelines
2. Comparison with the radiation plan is important.
3. PET/CT before treatment to assess tumor metabolic activity - highly desirable



**Abstract Number:** 3

**Abstract Title:** Prognostic significance of PET RANO 1.0 response in patients with newly diagnosed IDH wild-type glioblastoma and longitudinal FET PETs

**Authors:**

**Isabelle von Polenz**<sup>1</sup>, Katharina Müller<sup>2</sup>, Lilian Wiegand<sup>1</sup>, Maximilian Mair<sup>3</sup>, Jonas Reis<sup>4</sup>, Stephan Schönecker<sup>5</sup>, Robert Forbrig<sup>4</sup>, Florian Ringel<sup>6</sup>, Matthias Preusser<sup>3</sup>, Patrick Harter<sup>7</sup>, Louisa von Baumgarten<sup>6</sup>, Nathalie L. Albert<sup>1</sup>

<sup>1</sup>University Hospital of Munich, Department of Nuclear Medicine, Munich, <sup>2</sup>University Hospital of Munich, Department of Neurology, Munich, <sup>3</sup>Medical University of Vienna, Clinical Department of Oncology, Vienna, <sup>4</sup>University Hospital of Munich, Department of Neuroradiology, Munich, <sup>5</sup>University Hospital of Munich, Department of Radiation Oncology, Munich, <sup>6</sup>University Hospital of Munich, Department of Neurosurgery, Munich, <sup>7</sup>University Hospital of Munich, Department of Neuropathology, Munich

**Objective**

The PET RANO 1.0 criteria, introduced in 2024, enable standardized response classification of diffuse gliomas using [18F]FET PET imaging. However, their correlation with survival has not yet been sufficiently investigated. In this study, we therefore correlated the clinical course of glioblastoma patients with the PET RANO 1.0 response at defined timepoints.

**Methods**


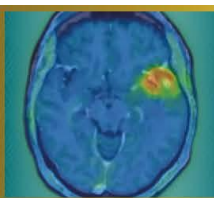
Patients with newly diagnosed IDH wild-type glioblastoma who underwent [18F]FET PET imaging before first-line radiotherapy (“baseline”) and three and/or six months after therapy initiation were included. We determined the response according to PET RANO 1.0 (progressive disease (PET-PD), stable disease (PET-SD), partial response (PET-PR), or complete response (PET-CR)) between all scans. Finally, we compared patients with PET-PD and PET-SD/PR/CR in terms of overall survival (OS), progression-free survival (PFS), and time to next intervention (TTNI). Kaplan-Meier and log-rank tests were used for statistical analyses.

**Results**

The PET intervals “baseline vs. 3 months” (n = 126), “baseline vs. 6 months” (n = 78), and “3 vs. 6 months” (n = 64) were examined in a cohort of 140 patients (median follow-up = 44.8 months). Across all three intervals, patients with PET-PD demonstrated a significantly shorter median OS compared with PET-SD/PR/CR (13.2 vs. 23.6 months, p = 0.003; 14.1 vs. 27.5 months, p < 0.001; and 14.3 vs. 36.4 months, p < 0.001, respectively). Similar significant differences were also observed for PFS and TTNI (all p < 0.001). Multivariate regression analyses at baseline revealed a prognostic relevance of MGMT methylation (HR = 0.55, p = 0.007, 59/135 patients).

**Conclusion**

Our results show a significant correlation between PET RANO 1.0 response and OS, PFS, and TTNI in patients with newly diagnosed glioblastoma. This suggests that standardized response classification according to PET RANO 1.0 and close follow-up using [18F]FET PET may support clinical management.



**Abstract Number:** 4

**Abstract Title:** [18F]FET PET enables histopathology-validated detection of non-contrast-enhancing glioblastoma

**Authors:**

**Roman Stürzl**<sup>1</sup>, Sabrina Kirchleitner<sup>2</sup>, Julia Lorenz<sup>3</sup>, Katharina Müller<sup>4</sup>, Veit Stöcklein<sup>2</sup>, Stephanie Quach<sup>5</sup>, Lena Kaiser<sup>1</sup>, Sophie Stöcklein<sup>6</sup>, Adrian Zounek<sup>1</sup>, Enio Barci<sup>1</sup>, Isabell von Polenz<sup>1</sup>, Jens Blobner<sup>2</sup>, Tobias Greve<sup>2</sup>, Matthias Brendel<sup>1,7,8</sup>, Patrick Harter<sup>9</sup>, Victoria Ruf<sup>9</sup>, Rainer Rupprecht<sup>10</sup>, Florian Ringel<sup>2</sup>, Darius Kalasauskas<sup>2</sup>, Markus Riemenschneider<sup>3</sup>, Niklas Thon<sup>11</sup>, Louisa von Baumgarten<sup>2,12</sup>, Jörg Christian Tonn<sup>2</sup>, Nathalie Albert<sup>2,12</sup>

<sup>1</sup>Department of Nuclear Medicine, University Hospital, LMU Munich, Munich, Germany, <sup>2</sup>Department of Neurosurgery, University Hospital, LMU Munich, Munich, Germany, <sup>3</sup>Department of Neuropathology, University Hospital Regensburg, Regensburg, Germany, <sup>4</sup>Department of Neurology, LMU University Hospital, LMU Munich, Munich, Germany, <sup>5</sup>Department of Neurosurgery, University Hospital OWL, Campus Bielefeld-Bethel, Bielefeld, Bielefeld, Germany, <sup>6</sup>Department of Radiology, University Hospital, LMU Munich, Munich, Germany, <sup>7</sup>German Center for Neurodegenerative Diseases (DZNE), Munich, Munich, Germany, <sup>8</sup>Munich Cluster for Systems Neurology (SyNergy), Munich, Munich, Germany, <sup>9</sup>Center for Neuropathology and Prion Research, Faculty of Medicine, LMU Munich, Munich, Germany, <sup>10</sup>Department of Psychiatry and Psychotherapy, University of Regensburg, Regensburg, Regensburg, Germany, <sup>11</sup>Department of Neurosurgery, Knappschaft Hospital, University Hospital Bochum, Bochum, Bochum, Germany, <sup>12</sup>German Cancer Consortium (DKTK), Partner Site Munich, German Cancer Research Center (DKFZ), Heidelberg, Heidelberg, Germany

**Background & aim**

Preoperative delineation of tumor tissue in glioblastoma is crucial for planning surgical intervention as well as radiotherapy. While contrast-enhanced MRI (CE-MRI) is standard in routine clinical practice, it has limitations in detecting metabolically active tumor tissue in the absence of blood–brain barrier disruption. This study aimed to determine whether amino acid PET using O-(2-[18F]fluoroethyl)-L-tyrosine (FET) can overcome these limitations and provide a more sensitive assessment of tumor extent.

**Patients & methods**

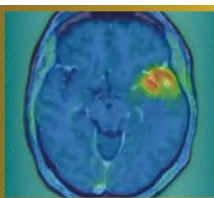
In this prospective, biopsy-validated single-center study, 472 spatially correlated biopsies from 61 patients with glioblastoma, IDH-wildtype (44 newly diagnosed, 17 recurrent) were histopathologically evaluated after preoperative FET PET and CE-MRI. Diagnostic metrics were calculated and compared between modalities using McNemar and Chi<sup>2</sup> tests (p = 0.05).

**Results**

FET PET achieved significantly higher sensitivity for tumor detection compared to CE-MRI (91.2% vs. 55.7%; p < 0.001). In comparison with T2/FLAIR, FET showed higher sensitivity (85.3%; p = 0.012) and markedly improved specificity (82.5% vs. 33.3%, p < 0.001). Importantly, FET reliably detected tumor tissue even in FET-positive but non-enhancing biopsies (positive predictive value/PPV 98.3%). Subgroup analyses confirmed the superiority of FET across all clinical and histological categories, including newly diagnosed and recurrent cases (p < 0.001), as well as in resection (p < 0.001; specificity p = 0.03) and biopsy subgroups (p < 0.001). FET was also significantly superior to CE-MRI in detecting tumor tissue irrespective of tumor cell density (“infiltration zone” vs. “solid tumor”; p < 0.001).

**Discussion & conclusion**

FET PET demonstrates significant, diagnostic superiority over CE-MRI for the visualization of glioblastoma tissue. Comparable PPVs in contrast-enhancing and non-enhancing regions indicate that FET PET detects tumor reliably, independent of the blood–brain barrier integrity. These findings support the integration of amino acid PET as a key component in surgical planning and target definition for glioblastoma.



**Abstract Number:**5

**Abstract Title:** Intra-arterial 4- [<sup>211</sup>At]astato-L-phenylalanine ([<sup>211</sup>At]APA) in [<sup>18</sup>F]fluoroethyl-L-tyrosine ([<sup>18</sup>F]FET) positive recurrent glioblastoma: study protocol for a phase 1 dose-escalation study (I-APACHE)

**Authors:**

**Anass El Ghalbouni**<sup>1,2</sup>, Dr. Tom Snijders<sup>2</sup>, Dr. Nelleke Tolboom<sup>1</sup>, Dr. Berend van der Wildt<sup>1</sup>, Dr. Morsal Samim<sup>1</sup>, Prof. Dr. Irene van der Schaaf<sup>1</sup>, Dr. Alex Poot<sup>1</sup>, Dr. Arthur Braat<sup>1,3</sup>

<sup>1</sup>Radiology and Nuclear Medicine, UMC Utrecht, Utrecht, Netherlands, <sup>2</sup>Neurology and Neurosurgery, Brain Center, UMC Utrecht, Utrecht, Netherlands, <sup>3</sup>Nuclear Medicine, Netherlands Cancer Institute, Amsterdam, Netherlands

**Background**

Glioblastoma is an invariably fatal primary brain tumor with limited treatment options. Therapeutic approaches are currently under investigation, with [<sup>131</sup>I]IPA entering phase III clinical trials. Building on this concept, we propose the use of 4- [<sup>211</sup>At]astato-L-phenylalanine ([<sup>211</sup>At]APA). Compared with <sup>131</sup>I, the α-emitter [<sup>211</sup>At] offers higher tumoricidal potential, while radiation exposure to family members and hospital personnel is minimal due to the absence of γ-emission. This enables outpatient-based treatment, thereby reducing patient burden. Based on prior experience, superselective intra-arterial administration is expected to improve intratumoral accumulation of [<sup>211</sup>At]APA. In this study, we will conduct a phase 1 dose-escalation study to assess the safety and preliminary efficacy of intra-arterial administered [<sup>211</sup>At]APA.

**Material and Methods**


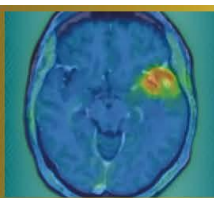
Patients are eligible if diagnosed with recurrent glioblastoma following standard-of-care temozolomide-chemoradiation and showing positivity on [<sup>18</sup>F]fluoroethyl-L-tyrosine ([<sup>18</sup>F]FET) PET. This 3+3 dose-escalation study will include four dose cohorts (starting at 50 MBq, up to 300 MBq). The dose-limiting toxicity period will be three weeks after the first cycle. Up to three cycles per participant are planned, administered at four-week intervals. Follow-up will continue for up to 42 weeks after completion of treatment. The primary endpoint is the maximum tolerated dose. Secondary outcomes include the maximum tolerated cumulative dose, preliminary efficacy, dosimetry and radiation safety.

**Results**

Currently, radiochemical production of [<sup>211</sup>At]APA is optimized and automated, as well as the logistical processes. Batch sizes are upscaled to >100 MBq, the minimally required patient dose. Preliminary production runs demonstrate high chemical yield, stability up to 24h and purity (>95%). Validation runs are scheduled for Q3 2026 for GMP production.

**Conclusion**

This is the first clinical trial to evaluate the safety and feasibility of [<sup>211</sup>At]APA in patients with recurrent glioblastoma. Investigating and confirming the feasibility of repeated superselective intra-arterial administrations will further contribute to maximizing the potential of this new radiopharmaceutical in neuro-oncology.



**Abstract Number:** 6

**Abstract Title:** Radionuclide Therapy with [<sup>177</sup>Lu]Lu-DOTATATE in Refractory Meningiomas: Results from the French Multicenter MELUTE Cohort

**Authors:**

Dr Nicolas Garabedian<sup>1</sup>, Dr Timothée Zaragori<sup>2</sup>, Pr Emeline Tabouret<sup>3</sup>, Dr Catherine Ansquer<sup>4</sup>, Dr Sarah Boughdad<sup>5</sup>, Dr Caroline Bund<sup>6</sup>, Pr Catherine Cheze-Le-Rest<sup>7</sup>, Pr Jacques Darcourt<sup>8</sup>, Dr Gauthier Delaby<sup>9</sup>, Dr Inna Dygai-Cochet<sup>10</sup>, Pr Emmanuel Deshayes<sup>11</sup>, Dr Agathe Edet-Sanson<sup>12</sup>, Dr Anthime Flaus<sup>13</sup>, Dr Thibault Fidani<sup>14</sup>, Dr Tatiana Horowitz<sup>15</sup>, Dr Vija Lavinia<sup>16</sup>, Dr Pierre Meneret<sup>17</sup>, Dr Elisabeth Quak<sup>18</sup>, Dr Solene Querellou<sup>19</sup>, Dr Ghoufrane Tlili<sup>20</sup>, Pr Matthieu Peyre<sup>21</sup>, Pr Thomas Gaillon<sup>22</sup>, Dr Caroline Boursier-Joppin<sup>23</sup>, **Antoine Verger**<sup>1</sup>

<sup>1</sup>CHRU Nancy, Nancy, France, <sup>2</sup>CHRU Nancy, Nancy, France, <sup>3</sup>APHM, Marseille, France, <sup>4</sup>CHU Nantes, Nantes, France, <sup>5</sup>APHP, Paris, France, <sup>6</sup>ICANS, Strasbourg, France, <sup>7</sup>CHU Poitiers, Poitiers, France, <sup>8</sup>Cote d'Azur University, Nice, France, <sup>9</sup>CHRU Lille, Lille, France, <sup>10</sup>CGFL Dijon - Centre Régional De Lutte Contre Le Cancer Georges-François Leclerc, Dijon, France, <sup>11</sup>Institut Régional du Cancer de Montpellier ICM, Montpellier, France, <sup>12</sup>Centre Henri Becquerel, Rouen, France, <sup>13</sup>CHU Lyon, Lyon, France, <sup>14</sup>CHU Nîmes, Nîmes, France, <sup>15</sup>APHM, Marseille, France, <sup>16</sup>IUCT Oncopole, Toulouse, France, <sup>17</sup>Centre Eugène Marquis, Rennes, France, <sup>18</sup>Centre François Baclesse, Caen, France, <sup>19</sup>CHU Brest, France, Brest, France, <sup>20</sup>CHU Bordeaux, Bordeaux, France, <sup>21</sup>APHP, Paris, France, <sup>22</sup>AP-HM, Marseille, France, <sup>23</sup>CHRU Nancy, Nancy, France

**Background**

Evidence supporting the efficacy and safety of [<sup>177</sup>Lu]Lu-DOTATATE in refractory meningiomas is mainly derived from small, single-center studies with heterogeneous protocols. The French national multicenter MELUTE study aimed to consolidate these findings using a standardized regimen within a compassionate use program approved by a national multidisciplinary tumor board.

**Methods**

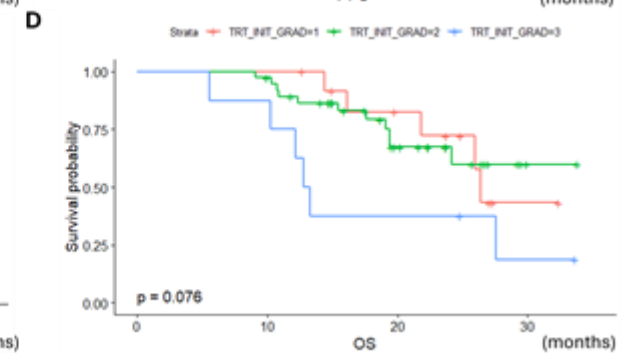
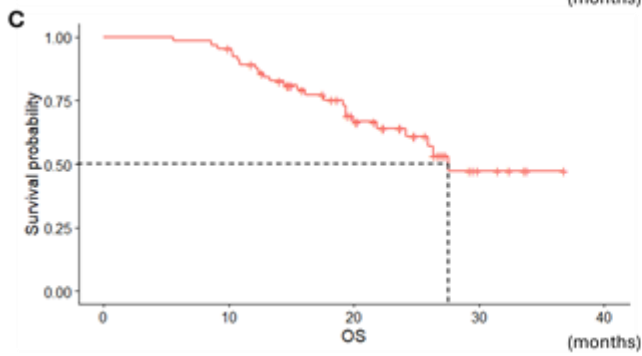
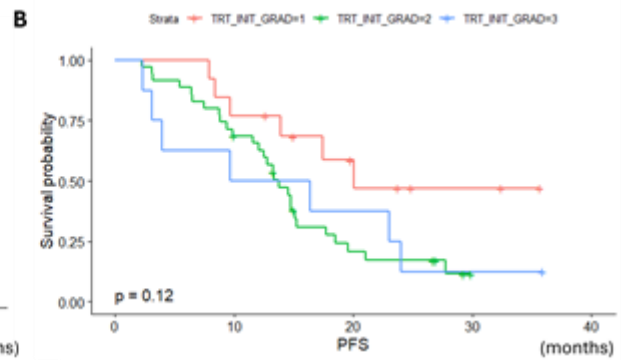
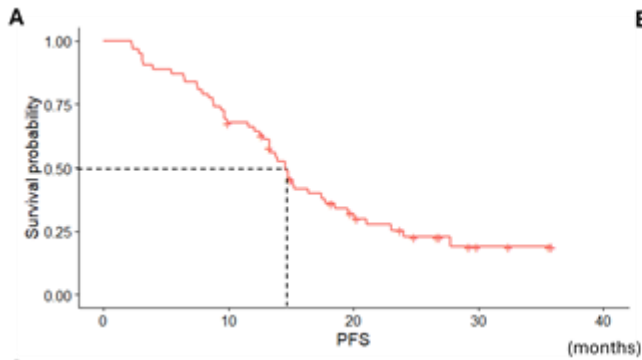
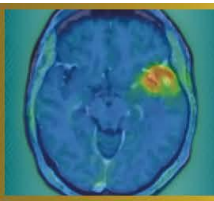
Patients with refractory meningiomas treated with [<sup>177</sup>Lu]Lu-DOTATATE in 18 French centers between July 2022 and December 2024 were retrospectively included. Treatment consisted of 7.4 GBq administered every 8 weeks for up to four cycles. Clinical data, including demographics, histological grade, prior treatments, number of cycles, toxicity, disease progression, and survival status (October 1, 2025), were collected using an electronic case report form. Baseline [<sup>68</sup>Ga]Ga-DOTATOC PET and pre- and post-treatment brain MRI scans were centrally reviewed. The primary endpoint was 6-month progression-free survival (PFS-6) assessed using volumetric RANO criteria. Secondary endpoints included progression-free survival (PFS), overall survival (OS), safety and tumor growth rates (TGRs) differences after treatment.

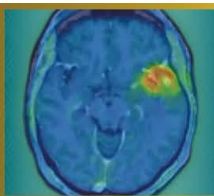
**Results**

Sixty-nine patients were included (mean age 65.1 ± 13.2 years; 52% female), including 13 grade 1, 42 grade 2, 8 grade 3, and 6 unclassified meningiomas. Most patients had undergone surgery (86%) and radiotherapy (93%), and 32% had received prior systemic therapy. Twelve patients (17%) did not complete all four cycles; only one discontinuation was related to toxicity. PFS-6 was 70%. Median PFS was 14.6 months and median OS was 27.6 months. Grade ≥3 adverse events occurred in 16% of patients, mainly lymphopenia. The difference in TGRs before versus after [<sup>177</sup>Lu]Lu-DOTATATE therapy was -16.6 [-47.4; -2.1]% per 6 months. Meningioma grade independently predicted PFS, while higher KPS and corticosteroid use were protective; worse OS was associated with higher baseline TGR and prior systemic therapy.

**Conclusion**

MELUTE demonstrates promising efficacy and a favorable safety profile of [<sup>177</sup>Lu]Lu-DOTATATE in refractory meningiomas with limited therapeutic options.





**Abstract Number:** 7

**Abstract Title:** Translational Potential of MAO-B PET Imaging as a Biomarker in Glioblastoma

**Authors:**

**Justus Thevis**<sup>1,11</sup>, Laura M Bartos<sup>1,2,3</sup>, Lea H Kunze<sup>1,4</sup>, Manvir Lalia<sup>1</sup>, Marlies Haertel<sup>1</sup>, Isabelle S Fuxjäger<sup>5</sup>, Ha Eun Park<sup>1</sup>, Karin Wind<sup>1</sup>, Giovanna Palumbo<sup>1</sup>, Rosel Oos<sup>1</sup>, Patrick N Harter<sup>7,11,12</sup>, Rudolf A Werner<sup>1,10</sup>, Nathalie L Albert<sup>1,11,12</sup>, Louisa von Baumgarten<sup>6,8,11,12</sup>, Matthias Brendel<sup>1,4,9,12</sup>

<sup>1</sup>Department of Nuclear Medicine, LMU University Hospital, LMU Munich, Munich, Germany, <sup>2</sup>Institute of Clinical Neuroimmunology, LMU University Hospital, LMU Munich, Munich, Germany, <sup>3</sup>Biomedical Center (BMC), Faculty of Medicine, LMU Munich, Munich, Germany, <sup>4</sup>German Center for Neurodegenerative Diseases (DZNE), Munich, Germany, <sup>5</sup>German Center for Vertigo and Balance Disorders (DSGZ), Munich, Germany, <sup>6</sup>Department of Neurology, LMU University Hospital, LMU Munich, Munich, Germany, <sup>7</sup>Center for Neuropathology and Prion Research, Faculty of Medicine, LMU Munich, Munich, Germany, <sup>8</sup>Department of Neurosurgery, LMU University Hospital, LMU Munich, Munich, Germany, <sup>9</sup>Munich Cluster of Systems Neurology, Munich, Germany, <sup>10</sup>Russell H. Morgan Department of Radiology and Radiological Sciences, Johns Hopkins School of Medicine, Baltimore, USA, <sup>11</sup>German Cancer Consortium (DKTK), Partner Site Munich, Munich, Germany, <sup>12</sup>Bavarian Cancer Research Center (BZKF), Partner Site Munich, Munich, Germany

**Background**

Astrogliosis is a key feature of numerous neurological disorders; however, its role in neuro-oncological diseases remains poorly understood. [<sup>18</sup>F]deuterium-L-deprenyl (F-DED) PET enables non-invasive in vivo assessment of astrocyte activity. In glioblastoma (GB) it is currently unclear whether the [<sup>18</sup>F]F-DED PET signal primarily reflects reactive astrogliosis or is confounded by increased MAO-B expression in tumor cells. This study investigated the potential of [<sup>18</sup>F]F-DED PET to characterize astrogliosis in glioblastoma mouse models and GB patients.

**Methods**


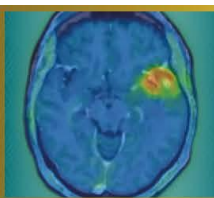
MAO-B expression in GB patients was analysed immunohistochemically in tumor tissue sections. In mice, tumors were induced by stereotactic inoculation of  $1 \times 10^3$  SB28,  $1 \times 10^3$  GL261 or  $1 \times 10^5$  U87 cells. Longitudinal 60-min dynamic [<sup>18</sup>F]F-DED PET scans were performed between days 4 and 31 after inoculation. In addition, mouse brains were analysed using ex vivo autoradiography (ARG) and immunohistochemistry (IHC). Tracer uptake was quantified using tumor-to-background ratios (TBR) and volume of distribution (VT).

**Results**

Analysis of human GB samples revealed increased MAO-B expression in both tumor cells and surrounding astrocytes. In contrast, [<sup>18</sup>F]F-DED PET in all mouse models showed no relevant contrast between tumor and contralateral brain tissue (TBR SB28: 1.10; GL261: 1.07; U87: 1.03). Low intratumoral MAO-B expression was confirmed by VT analysis and ex vivo ARG. IHC demonstrated pronounced peritumoral astrogliosis. This astrogliosis was not associated with increased MAO-B expression.

**Conclusions**

In commonly used preclinical GB models, neither tumor cells nor peritumoral astrogliosis are characterized by increased MAO-B expression. These findings highlight limitations of these models in recapitulating the situation observed in human glioblastoma patients and suggest that distinct forms of astrocyte activation differ in their associated MAO-B expression.



**Abstract Number:** 8

**Abstract Title:** Comparative response assessment using PET-RANO 1.0 and RANO 2.0 in vorasidenib-treated IDH-mutant gliomas: the VORAFET study

**Authors:**

**Prof. Diego Cecchin**<sup>1</sup>, Alberto Bosio<sup>2,3</sup>, Dr. Tamara Ius<sup>4</sup>, Dr. Giovanni Librizzi<sup>5,6</sup>, Dr. Mario Caccese<sup>3</sup>, Dr. Marta Padovan<sup>3</sup>, Francesco Cavallin<sup>7</sup>, Dr. Marta Maccari<sup>2,3</sup>, Dr. Rossella Simeone<sup>1</sup>, Dr. Francesca Serani<sup>1</sup>, Prof. Luca Denaro<sup>4</sup>, Dr. Sara Lonardi<sup>3</sup>, Prof. Matthias Preusser<sup>8</sup>, Prof. Nathalie Lisa Albert<sup>9</sup>, Dr. Giuseppe Lombardi<sup>3</sup>

<sup>1</sup>Unit of Nuclear Medicine, Department of Medicine -DIMED, University Hospital of Padua, Padova, Italy, <sup>2</sup>Department of Surgery, Oncology and Gastroenterology, University of Padova, Padova, Italy, <sup>3</sup>Medical Oncology 1, Veneto Institute of Oncology IOV - IRCCS, Padova, Italy, <sup>4</sup>Academic Neurosurgery, Department of Neurosciences, University of Padova, Padova, Italy, <sup>5</sup>Padova Neuroscience Center (PNC), University of Padova, Padova, Italy, <sup>6</sup>Neuroradiology Unit, Padova University Hospital, Padova, Italy, <sup>7</sup>Independent Statistician, Solagna, Italy, <sup>8</sup>Division of Oncology, Department of Medicine I, Medical University of Vienna, Vienna, Austria, <sup>9</sup>Department of Nuclear Medicine, LMU University Hospital, LMU Munich, Munich, Germany

**Background**

MRI-based response assessment may be suboptimal for capturing early treatment effects during isocitrate dehydrogenase (IDH) inhibition. We compared metabolic and morphological response classification using PET-RANO 1.0 and RANO 2.0 in vorasidenib-treated IDH-mutant gliomas and assessed treatment-related metabolic changes.

**Methods**

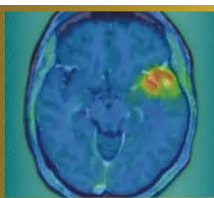
All consecutive patients treated at Veneto Institute of Oncology and at Padua University Hospital with vorasidenib (VOR) under a compassionate-use program (June 2024–March 2025) with baseline and follow-up [18F]FET PET/MR were retrospectively included. Response was assessed every 3 treatment cycles according to PET-RANO 1.0 and RANO 2.0. PET-positive tumor volumes and tumor-to-background ratios (TBR<sub>max</sub>, TBR<sub>mean</sub>) were analyzed. MRI response was evaluated using volumetric RANO 2.0 criteria.

**Results**

Twenty-six patients were included (10 astrocytomas, 16 oligodendrogliomas; 22 WHO grade 2, 4 non-enhancing WHO grade 3). Median follow-up from VOR initiation was 9 months (IQR 9–11). According to PET-RANO 1.0, partial metabolic responses (PET-PR) increased over time, from 20% at 3 months to 30.8% at 6 months and 63.6% at 9 months, while metabolic progression (PET-PD) was already detected in 18.2% at 9 months. Conversely, RANO 2.0 identified no partial responses at any timepoint, classifying most patients as stable disease (SD, 84.2%) or minor response (MR, 10.5%), with progression (PD) detected in only 5.3% at 9 months. Quantitative PET analysis showed an early and sustained reduction in metabolic activity. TBR<sub>mean</sub> decreased significantly at 3 months (mean difference [MD] -0.04; 95%CI -0.08 to -0.01) and continued to decline at 9 months (MD -0.07; 95%CI -0.11 to -0.02). Compared to baseline, at 9 months, TBR<sub>max</sub> decreased from 2.7 to 2.0 (MD -0.5; 95%CI -0.8 to -0.2) in all patients included. No significant changes were observed in PET volumes. Similarly, FLAIR-based tumor volume showed no significant variation (at 9 months: MD -2.2; 95%CI -5.1 to 0.7).

**Conclusions**

PET-RANO 1.0 enabled earlier detection of treatment response and progression compared with MRI-based RANO 2.0, highlighting clinically relevant limitations of morphology-driven MRI-based assessment. These findings support the clinical integration of amino acid PET into response monitoring strategies and warrant prospective validation of PET-derived biomarkers in IDH-mutant gliomas.



**Abstract Number:** 11

**Abstract Title:** Comparison of [ $^{18}\text{F}$ ] Fluciclovine PET, [ $^{18}\text{F}$ ] FDG PET, and Contrast-Enhanced MRI in the Preoperative Identification of High-Grade Glioma

**Authors:**

**Hiroto Koga**<sup>1,2</sup>, Shiro Watanabe<sup>1,2</sup>, Kenji Hirata<sup>1,2</sup>, Shigeru Yamaguchi<sup>3</sup>, Yukitomo Ishi<sup>3</sup>, Naoto Wakabayashi<sup>1,2</sup>, Kohsuke Kudo<sup>1</sup>

<sup>1</sup>Department of Diagnostic Imaging, Graduate School of Medicine, Hokkaido University, Sapporo, Hokkaido, Japan,

<sup>2</sup>Department of Nuclear Medicine, Hokkaido University Hospital, Sapporo, Hokkaido, Japan, <sup>3</sup>Department of Neurosurgery, Graduate School of Medicine, Hokkaido University, Sapporo, Hokkaido, Japan

### Background

Accurate preoperative identification of high-grade glioma (HGG) is essential for surgical planning and treatment decision-making. [ $^{18}\text{F}$ ] fluciclovine, a synthetic amino acid PET tracer originally developed for prostate cancer imaging, has been covered by the Japanese National Health Insurance System for imaging of high-grade glioma since June 2024. This study aimed to directly compare the diagnostic performance of [ $^{18}\text{F}$ ] fluciclovine PET, [ $^{18}\text{F}$ ] FDG PET, and contrast-enhanced MRI for identifying HGG in patients with clinically suspected brain tumors.

### Material and Methods

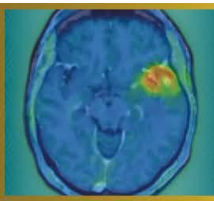
In this retrospective single-center study, patients who underwent preoperative [ $^{18}\text{F}$ ] fluciclovine PET, [ $^{18}\text{F}$ ] FDG PET, and contrast-enhanced MRI between July 2024 and December 2025 were analyzed. Histopathological diagnoses were established according to the 2021 WHO CNS classification. Tumor-to-background ratios (TBRs) were calculated using cortical (CX) and white matter reference regions (WM). Diagnostic performance metrics were assessed, optimal TBR cutoffs were determined using the Youden index. Receiver operating characteristic (ROC) analyses and DeLong tests were performed for modality comparison.

### Results

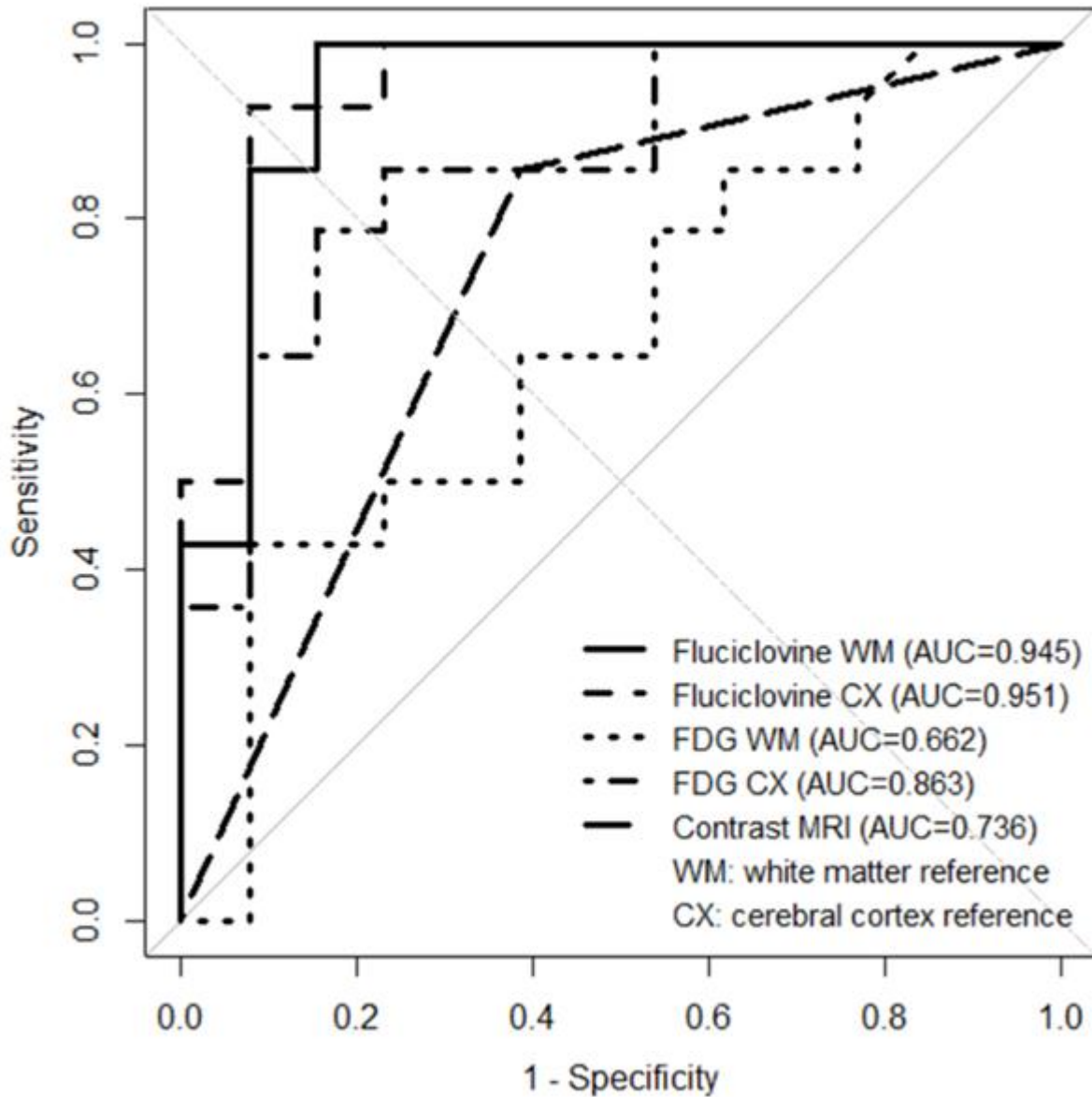
The study cohort consisted of 27 patients (14 high-grade gliomas [HGGs] and 13 non-HGGs). Using white matter as the reference region, [ $^{18}\text{F}$ ] fluciclovine PET achieved a sensitivity of 100%, specificity of 84.6%, positive predictive value of 87.5%, negative predictive value of 100%, and accuracy of 92.6%. Similar performance was observed with cortical reference (sensitivity 92.9%, specificity 92.3%, accuracy 92.6%). In comparison, [ $^{18}\text{F}$ ] FDG PET demonstrated lower diagnostic performance, with accuracies of 66.7–81.5%, and contrast-enhanced MRI showed an accuracy of 74.1%. Receiver operating characteristic analysis demonstrated the highest area under the curve for [ $^{18}\text{F}$ ] fluciclovine PET (Figure).

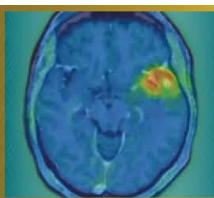
### Conclusion

[ $^{18}\text{F}$ ] fluciclovine PET demonstrated higher diagnostic performance for identifying high-grade glioma than [ $^{18}\text{F}$ ] FDG PET and contrast-enhanced MRI. These findings suggest that [ $^{18}\text{F}$ ] fluciclovine PET provides clinically relevant metabolic information and may have potential utility in the preoperative evaluation of suspected high-grade glioma.



## ROC curves for HGG vs non-HGG





**Abstract Number:** 12

**Abstract Title:** Background Activity Assessment in  $^{18}\text{F}$ -FET PET Imaging

**Authors:**

**Poh Hui Phang**<sup>1</sup>, Dr Sarah Beishan Tai<sup>2</sup>, Dr Wei Ming Chua<sup>2,3</sup>, Assistant Professor Xuling Lin<sup>4</sup>, Associate Professor Chee Kian Tham<sup>5</sup>, Assistant Professor Ding Fang Chuang<sup>4</sup>, Ms Jacqueline Su-Lin Teo<sup>6</sup>, Assistant Professor Kevin Lee Min Chua<sup>7</sup>, Associate Professor Winnie Wing Chuen Lam<sup>2</sup>

<sup>1</sup>Lee Kong Chian School of Medicine, Nanyang Technological University, Singapore, Singapore, <sup>2</sup>Department of Nuclear Medicine and Molecular Imaging, Singapore General Hospital, Singapore, Singapore, <sup>3</sup>Department of Neuroradiology, Singapore General Hospital, Singapore, Singapore, <sup>4</sup>Department of Neurology, National Neuroscience Institute, Singapore, Singapore, <sup>5</sup>Division of Medical Oncology, National Cancer Centre Singapore, Singapore, Singapore, <sup>6</sup>SingHealth Investigational Medicine Unit, Singapore Health Services, Singapore, Singapore, <sup>7</sup>Division of Radiation Oncology, National Cancer Centre Singapore, Singapore, Singapore (co-last author)

**Background**

Background activity measurements are key for calculation of various PET parameters for clinical interpretation of  $^{18}\text{F}$ -FET PET imaging in glioblastoma. Hence, careful choice of background reference methods is needed to accurately calculate these parameters. Guidelines recommend using crescent-shaped background volume-of-interest (VOI). However, this approach can be time-consuming and impractical in clinical workflows. We evaluate a simpler spherical background VOI as a feasible alternative for  $^{18}\text{F}$ -FET PET parameter calculations, while maintaining non-inferior accuracy in differentiating tumour recurrence from pseudoprogression.

**Methods**

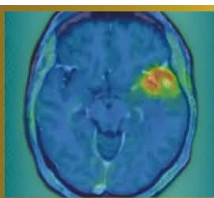
Two readers independently evaluated ten  $^{18}\text{F}$ -FET PET scans of high-grade glioma patients with MRI findings equivocal for tumour recurrence versus pseudoprogression (eventual diagnosis N=11 vs N=1 lesions respectively). Background activity assessment was performed using spherical VOIs of 30mm diameter and crescent-shaped VOIs. Key PET parameters such as mean standardised uptake value (SUV<sub>mean</sub>) and tumour-to-brain ratio (TBR) were compared using paired two-tailed t-tests. Inter-reader variability and agreement were assessed using coefficient of variation (CoV) and intraclass coefficient correlation (ICC) respectively.

**Results**

Background SUV<sub>mean</sub> from the spherical method was significantly lower than the crescent method (1.02 vs 1.07, p=0.022). TBR<sub>max</sub> from the spherical method was higher than that from the crescent method (5.70 vs 5.36, p<0.001). Nonetheless, the spherical method had comparable high sensitivity to the crescent method in distinguishing tumour recurrence from pseudoprogression (100% vs 100% respectively). However, due to the low number of pseudoprogression lesions, specificity could not be accurately assessed. CoV (5.13% vs 2.24%) and ICC (0.872 vs 0.983) metrics demonstrated good and excellent reliability for both the spherical and crescent method respectively.

**Conclusions**

Our preliminary results suggest that the spherical method holds promise as a viable, accurate and reliable alternative to the incumbent crescent method for background activity assessment in  $^{18}\text{F}$ -FET PET imaging. Further recruitment and analysis of pseudoprogression cases may allow accurate determination of specificity and accuracy to support these findings.



**Abstract Number:** 13

**Abstract Title:** FET PET reveals considerable volumetric and spatial differences in tumor burden compared to conventional MRI in recurrent glioblastoma

**Authors:**

**Norbert Galldiks**<sup>1,2</sup>, Julia Hilgers<sup>3</sup>, Keith George Ciantar<sup>3</sup>, Manuel Kraft<sup>1</sup>, Jana-Marie Peplinski<sup>1</sup>, Jan-Michael Werner<sup>1</sup>, Michael Wollring<sup>1</sup>, Isabelle Stetter<sup>1</sup>, Garry Ceccon<sup>1</sup>, Gereon Fink<sup>1,2</sup>, Roland Goldbrunner<sup>4</sup>, Maximilian Ruge<sup>5</sup>, Nadim Shah<sup>3</sup>, Felix Mottaghy<sup>6</sup>, Karl-Josef Langen<sup>3,6</sup>, Martin Kocher<sup>5</sup>, Philipp Lohmann<sup>3,6</sup>

<sup>1</sup>University Hospital Cologne, Dept. of Neurology, Cologne, Germany, <sup>2</sup>Inst. of Neuroscience and Medicine (INM-3), Research Center Juelich, Juelich, Germany, <sup>3</sup>Inst. of Neuroscience and Medicine (INM-4), Research Center Juelich, Juelich, Germany, <sup>4</sup>University Hospital Cologne, Dept. of Neurosurgery, Cologne, Germany, <sup>5</sup>University Hospital Cologne, Dept. of Stereotaxy and Functional Neurosurgery, Cologne, Germany, <sup>6</sup>Dept. of Nuclear Medicine, University Hospital RWTH Aachen, Aachen, Germany

**Background**

In recurrent glioblastomas, changes in areas of contrast enhancement and the T2/fluid-attenuated inversion recovery (FLAIR) signal on conventional MRI represent the mainstay for local therapy planning. Nevertheless, compared to conventional MRI, the information on the tumor burden obtained from amino acid PET may be considerably different in terms of volumetric assessment and spatial orientation.

**Methods**

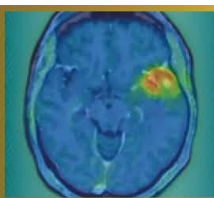
At suspected recurrence, 149 patients with histomolecularly characterized glioblastoma underwent O-(2-[<sup>18</sup>F]-fluoroethyl)-L-tyrosine (FET) PET and MR imaging including contrast-enhanced and FLAIR sequences. Contrast-enhancing and FLAIR volumes were automatically segmented using HD-GLIO, and FET PET tumor volumes were assessed using the nnUNet-based JuST\_BrainPET segmentation tool based on a tumor-to-brain ratio of  $\geq 1.6$ . All segmentations were visually checked. Subsequently, an in-house developed workflow was used for a fully automated assessment of maximum and mean tumor-to-brain ratios. To evaluate spatial differences between the modalities, percentage overlap, the Dice similarity coefficient (DSC), and the 95th-percentile Hausdorff distance (HD95) were calculated. Recurrent disease was confirmed either by neuropathological evaluation of tissue obtained from surgery or stereotactic biopsy or prompted a change in treatment.

**Results**

All patients had measurable disease according to the PET RANO 1.0 criteria (mean tumor-to-brain ratio,  $2.2 \pm 0.2$ ). In 52 patients (93%), the FET PET tumor volume was significantly larger than the contrast-enhancing volume ( $36.5 \pm 31.6$  mL vs.  $18.5 \pm 19.7$  mL;  $P < 0.001$ ). On average, FET PET tumor volumes extended by 30% beyond the combined contrast-enhancing and FLAIR volumes. The spatial similarity between FET uptake and contrast enhancement was limited (mean DSC,  $0.40 \pm 0.23$ ), with an HD95 of  $17.8 \pm 12.2$  mm. The comparison of FET uptake with the FLAIR hyperintensity revealed even lower spatial similarity (mean DSC,  $0.35 \pm 0.16$ ), and a higher boundary discrepancy (HD95,  $30.0 \pm 14.2$  mm).

**Conclusions**

Our results strongly support integrating both imaging modalities into treatment planning of patients with glioblastoma at recurrence.



**Abstract Number:** 14

**Abstract Title:** The added value of serial FET PET imaging to diagnose tumor progression in patients with glioblastoma

**Authors:**

**Norbert Galldiks**<sup>1,2</sup>, Keith George Ciantar<sup>3,4</sup>, Isabelle Stetter<sup>1</sup>, Julia Hilgers<sup>3</sup>, Jana-Marie Peplinski<sup>1</sup>, Manuel Kraft<sup>1,2</sup>, Christian Filss<sup>3,5</sup>, Gabriele Stoffels<sup>3</sup>, Karl-Josef Langen<sup>3,5</sup>, Jan-Michael Werner<sup>1</sup>, Philipp Lohmann<sup>3,5</sup>

<sup>1</sup>University Hospital Cologne, Dept. of Neurology, Cologne, Germany, <sup>2</sup>Inst. of Neuroscience and Medicine (INM-3), Research Center Juelich, Juelich, Germany, <sup>3</sup>Inst. of Neuroscience and Medicine (INM-4), Research Center Juelich, Juelich, Germany, <sup>4</sup>Inst. for Imaging and Computer Vision, RWTH Aachen University, Aachen, Germany, <sup>5</sup>Dept. of Nuclear Medicine, University Hospital RWTH Aachen, Aachen, Germany

### Background

The vast majority of existing studies evaluating the diagnostic performance of O-(2-[18F]-fluoroethyl)-L-tyrosine (FET) PET to diagnose glioblastoma progression have relied primarily on single-scan assessments. Although the observed diagnostic performances are relatively high, uncertainties remain, especially in cases with borderline uptake close to recommended thresholds. To this end, we assessed the evolution of metabolic activity by comparing serial FET PET scans during the transition of glioblastoma progression.

### Patients and methods

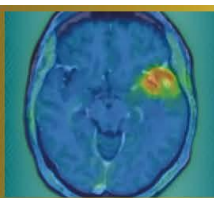
From 2019-2025, 131 patients with glioblastoma (CNS WHO 2021) who underwent 534 dynamic FET PET scans (median number, 3; range, 2-12) during the course of disease were retrospectively identified. Tumor-to-brain ratios (TBRmean, TBRmax), metabolic tumor volume (MTV), and time-to-peak (TTP) were obtained fully automated according to the current guidelines, at the time of suspected progression and in scans performed within a six-month window before glioblastoma progression. Progression was defined (clinico-)radiologically using the RANO criteria and subsequently prompted either neuropathological tissue confirmation following surgery, or initiation of new local or systemic treatment option, or combinations thereof.

### Results

Seventy-one cases with progression in 61 patients were confirmed (eight patients had one additional progression, and one patient had two additional progressions). The median time between the two FET PET scans was 2.7 months (range, 0.9-6.0 months). At progression, TBRmean, TBRmax, and MTV were significantly increased compared to the reference scan (all  $P \leq 0.002$ ). TTP values changed insignificantly ( $P > 0.05$ ). While median percentage changes in the uptake parameters TBRmean and TBRmax showed moderate increases of 4% and 16%, respectively, the MTV exhibited a much more pronounced increase of 182%.

### Conclusions

Our findings suggest that longitudinal volumetric assessment using serial FET PET is a critical marker for detecting the transition to glioblastoma progression. In clinical routine, the addition of information on MTV changes to the frequently used TBR may improve diagnostic certainty in identifying glioblastoma progression.



**Abstract Number:** 15

**Abstract Title:** Interim FDG-PET in primary central nervous system lymphoma

**Authors:**

**Laura Rozenblum**<sup>1</sup>, Barbara Sicsic<sup>1</sup>, Caroline Houillier<sup>2</sup>, Khê Hoang-Xuan<sup>2</sup>, Aurélie Kas<sup>1</sup>

<sup>1</sup>Nuclear Medicine Department, Pitie-Salpetriere Hospital, Paris, France, <sup>2</sup>Neuro-Oncology Department, Pitie-Salpetriere Hospital, Paris, France

### Background

Response assessment in primary central nervous system lymphoma (PCNSL) currently relies on International PCNSL Collaborative Group (IPCG) criteria, although MRI has shown limits to act as a surrogate marker of survival. Metabolic assessment using interim FDG-PET may provide earlier and more robust prognostic information. This study evaluated the prognostic value of interim brain FDG-PET using quantitative metrics and a dedicated interim response score.

### Methods

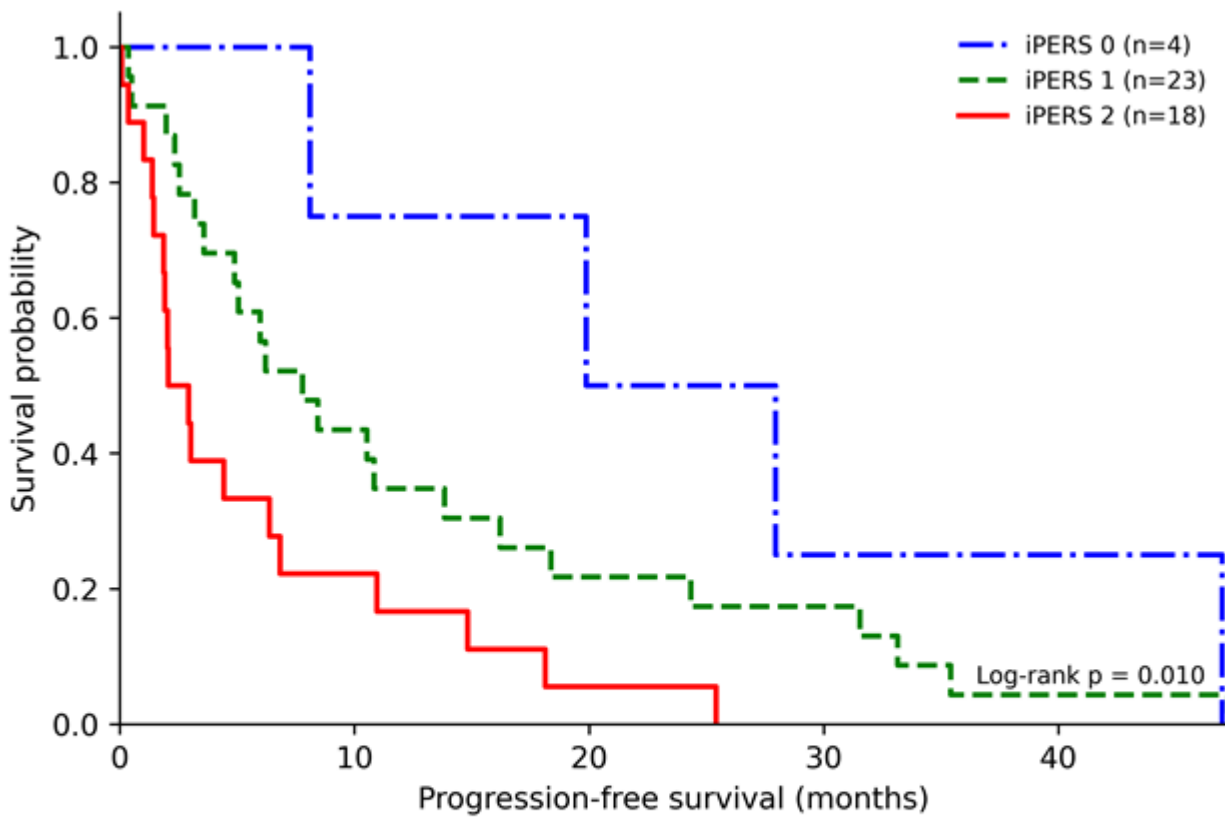
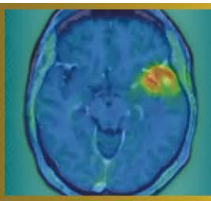
In this retrospective study, 113 immunocompetent patients with PCNSL treated with high-dose methotrexate-based chemotherapy were included. FDG-PET was performed at baseline and during interim assessment. Metabolic response was evaluated using the highest tumor-to-normal uptake ratio measured in a mirror area (hTNR\_max). In addition, we developed the Interim PCNSL PET Response Score (iPERS), a three-level response score based on residual tumor uptake relative to physiological uptake in normal white matter (WM) in the centrum semiovale and gray matter (GM) in the unaffected superior frontal gyrus. Progression-free survival (PFS) and overall survival (OS) were analyzed using Kaplan–Meier estimates and Cox proportional hazards models.

### Results

Elevated interim hTNR\_max was independently associated with poorer PFS (hazard ratio [HR]: 4.32; 95% CI: 2.23–8.85;  $P < 0.0001$ ) and OS (HR: 1.80; 95% CI: 1.24–2.53;  $P = 0.003$ ) in multivariate analysis. The iPERS stratified patients into three distinct metabolic response groups with significantly different PFS outcomes: iPERS 0 (uptake  $\leq$  WM; median PFS: 23.9 months), iPERS 1 (uptake between WM and GM; median PFS: 7.8 months), and iPERS 2 (uptake  $>$  GM; median PFS: 2.5 months). In contrast, interim MRI-based response categories (complete vs. partial response) did not significantly discriminate PFS.


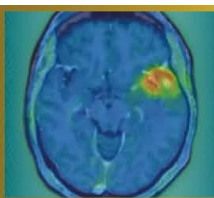
### Conclusion

Interim FDG-PET provides clinically relevant prognostic stratification in PCNSL. Quantitative hTNR\_max and the iPERS enable early identification of high-risk patients and may serve as candidate tools for response-adapted therapeutic strategies in future clinical trials.



Number at risk

Time (months)	0	6	12	18	24	30	35	41	47
iPERS 0	4	4	3	3	2	1	1	1	0
iPERS 1	23	14	8	6	5	4	2	1	1
iPERS 2	18	6	3	2	1	0	0	0	0



**Abstract Number:** 16

**Abstract Title:** Identification of prognostically relevant residual tumor burden in glioblastoma after surgery: A comparative analysis of MR-based RANO resect classes vs. [<sup>18</sup>F]FET PET

**Authors:**

**Jens Blobner**<sup>1</sup>, Katharina J. Mueller<sup>2</sup>, Michael Muether<sup>3</sup>, Wolfgang Roll<sup>4</sup>, Jonas Reis<sup>7</sup>, Maximilian J. Mair<sup>5,6</sup>, Niklas Thon<sup>1,8</sup>, Stephan Schoenecker<sup>9</sup>, Patrick N. Harter<sup>10</sup>, Louisa von Baumgarten<sup>1,2</sup>, Florian Ringel<sup>1</sup>, Joerg-Christian Tonn<sup>1</sup>, Philipp Karschnia<sup>11</sup>, Nathalie L. Albert<sup>6</sup>

<sup>1</sup>Department of Neurosurgery, LMU University Hospital Munich, Munich, Germany, <sup>2</sup>Department of Neurology, LMU University Hospital, Munich, Germany, <sup>3</sup>Department of Neurosurgery, University Hospital Münster, Münster, Germany, <sup>4</sup>Department of Nuclear Medicine, University Hospital Münster, Münster, Germany, <sup>5</sup>Division of Oncology, Department of Medicine I, Medical University of Vienna, Vienna, Austria, <sup>6</sup>Department of Nuclear Medicine, LMU University, Munich, Germany, <sup>7</sup>Institute for Neuroradiology, LMU University Hospital, Munich, Germany, <sup>8</sup>Department of Neurosurgery, Knappschaft University Hospital Bochum, Bochum, Germany, <sup>9</sup>Department of Radiation Oncology, LMU University Hospital, Munich, Germany, <sup>10</sup>Center for Neuropathology and Prion Research, Medical Faculty, Ludwig-Maximilians-University Munich, Munich, Germany, <sup>11</sup>Department of Neurosurgery, FAU University Hospital of the Friedrich-Alexander-University, Erlangen, Germany

**Background**

Accurate assessment of postoperative tumor burden is essential in glioblastoma. The RANO resect classification offers a stratification system based upon residual tumor volume determined by post-operative MRI. [<sup>18</sup>F]FET PET can detect metabolically active residual tumor invisible on MRI. The additional prognostic implications of postoperative PET to MRI remain ill-defined.

**Methods**

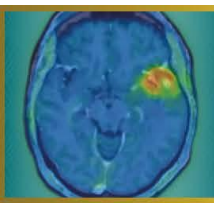
In this retrospective bicentric study, 140 patients with glioblastoma with evaluable postoperative MRI and [<sup>18</sup>F]FET PET were analyzed. Residual tumor volumes were delineated on postoperative MRI, and patients were classified according to the MRI-based RANO resect system. PET-derived residual tumor volumes were defined according to PET RANO 1.0 criteria. Spatial concordance was quantified using Dice coefficients. Prognostic associations were assessed with Cox regression. Incremental prognostic value of PET was examined using a two-stage approach with an imaging-only model (T1CE vs. T1CE+PET volume) and a fully adjusted model including clinical parameters.

**Results**

Postoperative PET-defined tumor volumes were substantially larger than MRI-defined volumes and showed minimal spatial overlap with a heterogeneous distribution across all RANO classes. PET-, contrast-enhanced T1 and T2/FLAIR-based tumor volumes were each independently associated with OS. The hazard of death increased continuously with increasing PET-derived residual tumor burden. In multivariable Cox regression, PET-positive residual tumor volume remained significantly associated with OS (adjusted HR 1.021 per cm<sup>3</sup>, 95% CI 1.008–1.033; \*\*p = 0.0024). In the imaging-only model, the addition of PET increased the time-dependent area-under-the-curve (AUC(t)) across all evaluated time points between 6 and 24 months (ΔAUC 0.03–0.07) and improved Harrell's C (ΔC ≈ 0.03). In the fully adjusted model, PET provided significant non-redundant prognostic information (likelihood ratio test, \*p = 0.0049).

**Conclusion**

Postoperative [<sup>18</sup>F]FET PET visualized metabolically active residual tumor not reliably identified by MRI and provides additional prognostic value in glioblastoma patients. Integrating PET into postoperative assessment may refine risk stratification beyond current MRI-based frameworks.



**Abstract Number:** 17

**Abstract Title:** Impact of FET PET on Proton Radiotherapy Target Delineation

**Authors:**

**Daniil Susin**<sup>1</sup>, Elena Gromova<sup>1</sup>, Marina Linnik<sup>1</sup>

<sup>1</sup>LDC MIBS, Saint-Petersburg, Russian Federation

### Background

MRI-based proton radiotherapy planning may underestimate the extent of metabolically active tumour tissue in primary brain tumours. FET-PET provides complementary biological information and is increasingly used in clinical practice, yet its real-world impact on radiotherapy target delineation remains insufficiently quantified.

### Methods

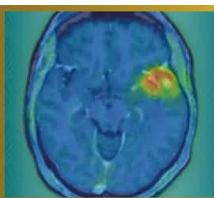
We retrospectively analysed patients with primary brain tumours (predominantly gliomas) who underwent FET-PET prior to proton radiotherapy planning at our centre. MRI-based gross tumour volumes (GTVs) were compared with FET-based metabolic tumour volumes (MTVs). Changes in target volume size and spatial configuration were assessed, and the clinical impact on proton radiotherapy planning was categorised in interdisciplinary consensus.

### Results

In 25 patients, incorporation of FET-PET resulted in clinically relevant target volume modification in 36% of cases, predominantly through expansion of treatment volumes and inclusion of infiltrative tumour margins. In 12% of patients, FET-PET revealed spatially distinct intratumoral hotspots not apparent on MRI, supporting additional refinement of target delineation.

### Conclusion

FET-PET frequently impacts target delineation for proton radiotherapy in routine care of patients with primary brain tumours, supporting its integration into proton radiotherapy planning workflows.



**Abstract Number:** 18

**Abstract Title:** Benefit of [177Lu]Lu-HA-DOTATATE in bone metastases in relapsed medulloblastoma, a case report

**Authors:**

**Sabine L.A. Plasschaert**<sup>1</sup>, Leonor Teles<sup>1</sup>, Dr. Nelleke Tolboom<sup>1,2</sup>, Arthur J.A.T. Braat<sup>1,2</sup>

<sup>1</sup>Princess Máxima Center for Pediatric Oncology, Utrecht, Netherlands, <sup>2</sup>University Medical Center Utrecht, Utrecht, Netherlands

### Background

Relapsed medulloblastoma with extensive skeletal metastases is rare and carries a dismal prognosis, with limited therapeutic options. Expression of somatostatin receptor subtype 2 (SSTR2) enables molecular imaging and targeted radionuclide therapy.

### Methods

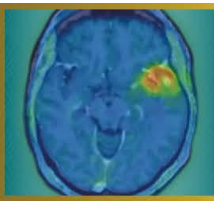
We report the case of a 14-year old boy with relapsed medulloblastoma with extensive bone metastases. Initially diagnosed with a medulloblastoma, group 3, at age 8 years old, without any evidence of leptomeningeal metastases. He was treated according to standard risk medulloblastoma protocol including craniospinal irradiation and maintenance chemotherapy. A local relapse occurred twice, which was treated with local re-irradiation, the first time combined with bevacizumab, irinotecan and temozolomide. Subsequently, a regular MRI was performed, while he had diffuse pain in his back and neck. The MRI showed extensive bone metastases in the spine, legs, arms, ribs and skull, without any evidence of CNS recurrence. A biopsy of the 4th lumbar vertebrae confirmed relapse medulloblastoma, with clear SSTR2A positivity on the tumor cells at immunohistochemistry.

### Results

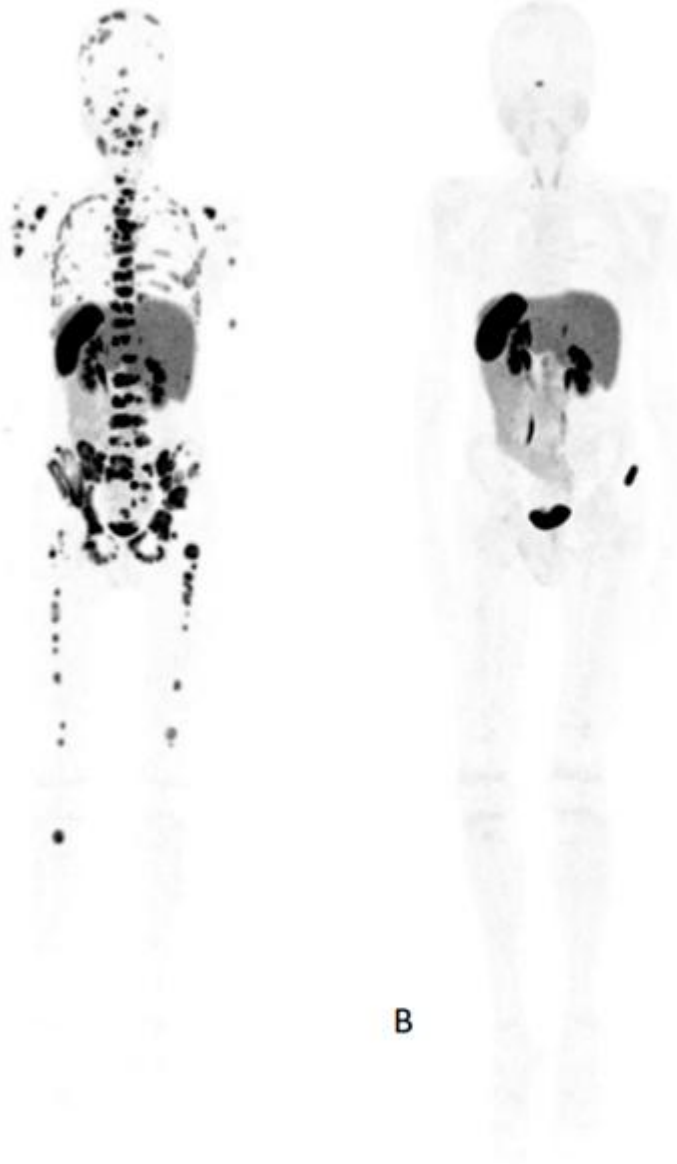
A [68Ga]Ga-DOTATOC PET/CT was performed with very extensive SSTR2-positive skeletal lesions in all his bones. Whilst waiting for initiation of [177Lu]Lu-HA-DOTATATE therapy initiation, he rapidly developed a hypercalcemia and was mildly dehydrated with calciuria, considered to be a paraneoplastic syndrome, treated with pain killers and hyperhydration. He started [177Lu]Lu-HA-DOTATATE therapy, two cycles of 7.4 GBq with an interval of 4 weeks. Following his first [177Lu]Lu-HA-DOTATATE treatment, his hypercalcemia resolved in 1-2 weeks. At the same time, pain complaints subsided and his lab results normalized. After 2 cycles of [177Lu]Lu-HA-DOTATATE, he had a very good clinical response and the [68Ga]Ga-DOTATOC PET/CT showed a remarkable radiological response, with hardly any tumor activity visible. (Figure 1 (A) before start and (B) 4 weeks after [177Lu]Lu-HA-DOTATATE therapy).

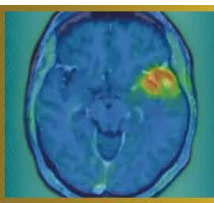
### Conclusion

This case shows the potential benefit from [177Lu]Lu-HA-DOTATATE therapy in bone metastases in relapsed medulloblastoma.



**Figure 1** [68Ga]Ga-DOTATOC PET/CT scan (A) before start and (B) 4 weeks after [177Lu]Lu-HA-DOTATATE therapy)





**Abstract Number:** 19

**Abstract Title:** Subventricular zone involvement and metabolic phenotype: a combined MRI and  $^{18}\text{F}$ -FET PET/CT biomarker for glioma prognosis

**Authors:**

**Nina Vikhrova**<sup>1</sup>, Diana Kalaeva<sup>1</sup>, Ivan Chekhonin<sup>1</sup>, Galina Pavlova<sup>1</sup>, Igor Pronin<sup>1</sup>

<sup>1</sup>N.N. Burdenko National Medical Research Center of Neurosurgery, Moscow, Russian Federation

### Background

The subventricular zone (SVZ) is the largest neural stem cell adult brain reservoir and is considered a potential reservoir for glioma stem cells. While MRI-defined SVZ-contact is a known glioma negative prognostic factor, contrast-enhanced (CE) MRI lacks sensitivity for tumor infiltration.  $^{18}\text{F}$ -FET PET/CT can detect metabolically active tumor cells. This study evaluated the combined prognostic value of anatomical SVZ involvement on MRI and metabolic activity on PET/CT

### Methods

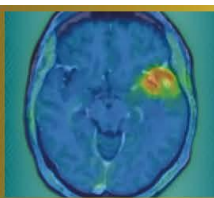
66 glioma patients (51 glioblastoma, 7 oligodendroglioma, 8 astrocytoma) were underwent 3.0T MRI and static  $^{18}\text{F}$ -FET PET/CT. Tumors were stratified into two SVZ-groups on MRI: contact SVZ(+) and no contact SVZ(-). Metabolic tumor activity (TBR) were analyzed in each group. Progression-free survival(PFS) was assessed in SVZ(+) group. Non-parametric statistical tests and Kaplan-Meier method for assessing PFS were used.

### Results

SVZ(+) was present in 90% patients. Conversely, SVZ(-) was identified in all histological subtypes, with the highest frequency observed in astrocytomas (n=5), followed by single cases in both glioblastoma and oligodendroglioma. All MRI CE+ lesions (n=56) were SVZ(+), while among CE- (n=10) this sign was observed in 50% of cases (p<0.001). TBR was significantly (p<0.001) higher in the SVZ(+) group compared to SVZ(-), cut off TBR=2,32 (SE95%, SP100%, AUC=0.98). Within SVZ(+) cohort, a high metabolic subgroup (defined by TBR>3.47) exhibited the worst prognosis, with median PFS 7.6months (95%CI: 6–12.2) compared to 19.4months (95%CI: 9–NA) in the low metabolic subgroup (p=0.049).

### Conclusions

The results confirm that SVZ contact is a common marker of an aggressive glioma phenotype, characterized by contrast enhancement and high metabolic activity. The integration of MRI-based SVZ status and PET/CT-derived TBR enables effective risk stratification. Specifically, TBR>3.47 within SVZ(+) tumors is an independent predictor of short PFS. The assessment of SVZ involvement on MRI combined with amino acid PET/CT for metabolic evaluation provides a crucial integrated biomarker for prognostic stratification and treatment guidance.



**Abstract Number:** 20

**Abstract Title:** Validation of an optimized 18F-FET PET/CT quantification protocol : single-slice background SUV and tumor SUVpeak enhance reproducibility and prognostic accuracy in glioma management

**Authors:**

**Nina Vikhrova**<sup>1</sup>, Diana Kalaeva<sup>1</sup>, Anastasia Kopaneva<sup>1</sup>, Igor Pronin<sup>1</sup>

<sup>1</sup>N.N. Burdenko National Medical Research Center of Neurosurgery, Moscow, Russian Federation

### Background

Current guidelines endorse TBR based on SUVmax/mean and 6-slice SUVnorm but skip SUVpeak. Recent evidence highlights TBRpeak prognostic superiority over TBRmax. This study aimed to validate optimized protocol by defining simplest SUVnorm calculation and comparing diagnostic/prognostic value of TBRpeak versus conventional TBRmax.

### Methods

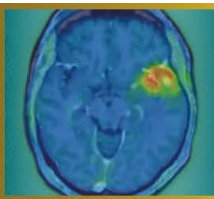
102 primary supratentorial glioma patients were underwent static 18F-FET PET/CT. SUVnorm was measured 'banana-shaped' VOI/ROI (mean values) in four ways: 1) 6-slice VOI - reference; 2) 2-slice bottom VOI at the level of lateral ventricles; 3) 2-slice top VOI at the centrum semiovale level; 4) single-slice ROI in the middle. Tumor activity was quantified using round-shaped VOI SUVmax and SUVpeak, enabling calculation of corresponding TBRmax and TBRpeak. Analytical methods included repeated-measures ANOVA, Bland-Altman analysis for agreement assessment, ROC analysis for diagnostic performance, Cox proportional hazards modeling for survival endpoints.

### Results

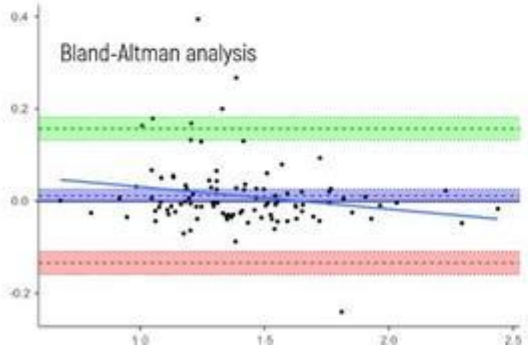
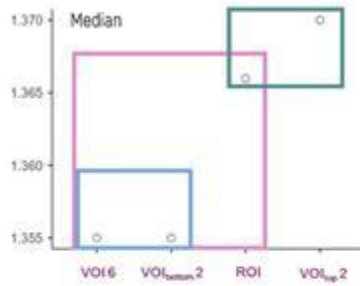
All SUVnorm calculations yielded highly similar median values(1.35-1.37). The simplest single-slice ROI was statistically comparable to the reference 6-slice VOI (p=0.19). Bland-Altman analysis confirmed their interchangeability. As hypothesized, SUVpeak was systematically and significantly lower than SUVmax (mean bias: 0.53 SUV, p<0.001), resulting in a concomitant mean reduction of 0.38 units in TBRpeak compared to TBRmax. However, for IDH status prediction, TBRpeak (AUC=0.749) demonstrated comparable diagnostic accuracy to TBRmax (AUC=0.738), the optimal cut-off for TBRpeak(2,20) was 15% lower than for TBRmax(2,53). In survival analysis, each unit increase in TBRpeak was associated with a higher risk of progression (HR 45% vs. 36% for TBRmax) and death (HR 47% vs. 35%).

### Conclusions

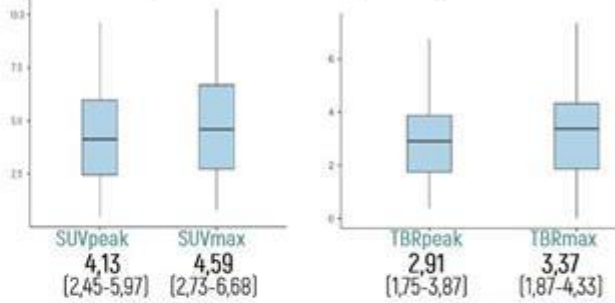
Our results confirms single-slice ROI provides valid, workflow-efficient background measurement. TBRpeak demonstrates prognostic superiority, serving as more robust biomarker of global tumor aggressiveness. TBRpeak prognostic superiority aligns with recent literature, confirming it as more robust global tumor aggressiveness biomarker, less susceptible to noise than TBRmax. Protocol maintains diagnostic performance, enhances practical feasibility, provides prognostically superior information compared to guideline-conventional TBRmax



### Background SUVmean (SUVnorm)




### Tumor SUVpeak vs SUVmax / TBRpeak vs TBRmax

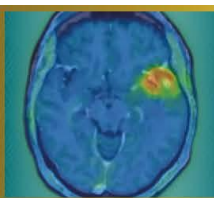


### Progression Free Survival (PSF)

Hazard Ratio **TBRpeak** Cut-off 2,15  
1,45 (1,09-1,93) p=0,01



Hazard Ratio **TBRmax** Cut-off 2,36  
1,36 (1,07-1,73) p=0,012



**Abstract Number:** 21

**Abstract Title:** Impact of postoperative somatostatin-receptor-targeted PET imaging on residual tumor detection and surgical assessment of re-resection in meningioma

**Authors:**

**Nina C. Teske**<sup>1</sup>, Nico Teske<sup>2</sup>, Thomas Schabhüttl<sup>3</sup>, Moritz Ueberschaer<sup>4</sup>, Sebastian N Marschner<sup>5,6</sup>, Christian Schichor<sup>1</sup>, Florian Ringel<sup>1</sup>, Nathalie L. Albert<sup>3,6</sup>, Tobias Greve<sup>1,7</sup>

<sup>1</sup>Department Of Neurosurgery, LMU University Hospital, LMU Munich, Munich, Germany, <sup>2</sup>Department of Neurosurgery, FAU University Hospital of the Friedrich-Alexander-University, Erlangen, Germany, <sup>3</sup>Department of Nuclear Medicine, LMU Hospital, LMU Munich, Munich, Germany, <sup>4</sup>Department of Neurosurgery, University Hospital Salzburg, Paracelsus Medical University, Salzburg, Austria, Salzburg, Austria, <sup>5</sup>Department of Radiation Oncology, LMU University Hospital, LMU Munich, , Munich, Germany, <sup>6</sup>German Cancer Consortium, Partner Site Munich, Munich, Germany, <sup>7</sup>Bavarian Cancer Research Center, Partner Site Munich, Munich, Germany

**Objective**

Residual tumor after meningioma surgery increases recurrence risk, yet postoperative assessment relies mainly on MRI with limited sensitivity. Somatostatin receptor (SSTR)-targeted PET may improve residual tumor detection, but its impact on postoperative surgical decision-making remains unclear. We evaluated whether postoperative SSTR-PET detects residual tumor beyond MRI and identifies potentially resectable disease, and exploratorily assessed progression in conservatively managed patients with retrospectively resectable residual tumor.

**Methods**

We retrospectively analyzed patients with intracranial meningioma who underwent surgical resection followed by postoperative MRI and SSTR-targeted PET. MRI was reviewed by a board-certified neurosurgeon to assess residual tumor, technical resectability, and potential clinical benefit of re-resection, including possible Simpson grade reduction. Assessments were repeated after inclusion of SSTR-PET.

**Results**

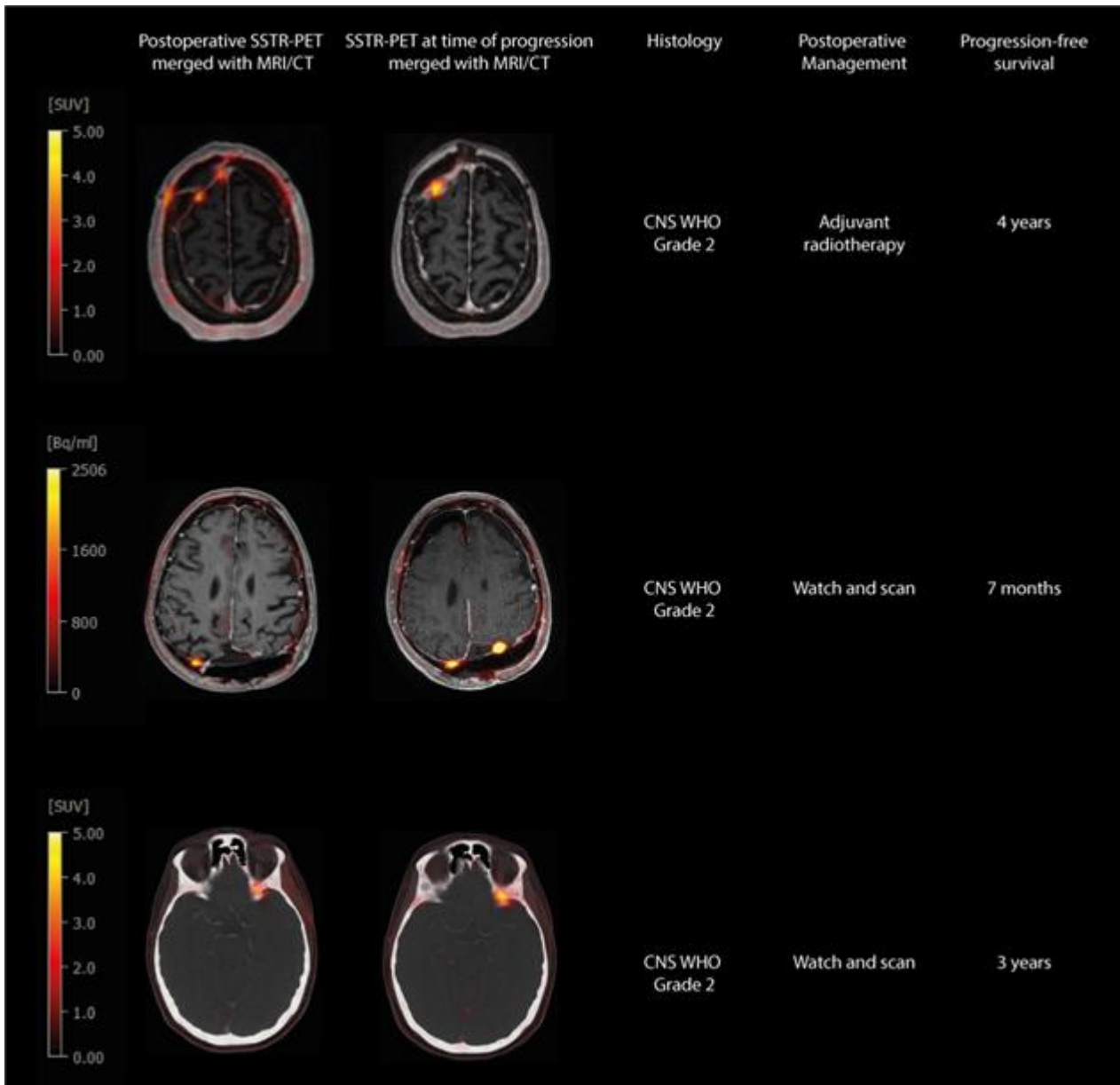
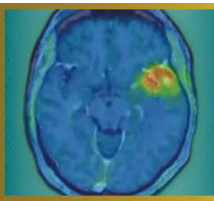
Forty patients were included (27 skull base, 4 convexity, 9 parafalcine meningiomas). Postoperative MRI detected residual tumor in 24/40 patients (60%), whereas SSTR-PET identified residual disease in 32/40 patients (80%), resulting in a significantly higher detection rate ( $p = 0.0078$ ).

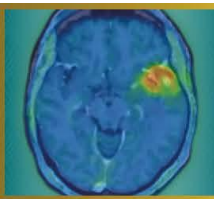
Based on MRI, complete and partial re-resection was considered feasible in 3/40 (7.5%) and 16/40 patients (40%), respectively; after inclusion of SSTR-PET, feasibility increased to 7/40 (17.5%) and 19/40 patients (47.5%). A clinically meaningful, potentially Simpson grade-reducing re-resection was identified in 4/40 patients (10%) based on MRI alone and in 8/40 patients (20%) after inclusion of SSTR-PET ( $p = 0.219$ ), including 4 patients classified as completely resected on MRI alone.

During follow-up 12/40 patients (30%) experienced disease progression. Of those, 10/12 patients (83%) had detected residual tumor on postoperative SSTR-PET, including 3 patients classified as completely resected on MRI but retrospectively considered amenable to clinically meaningful re-resection based on PET (Fig. 1).

**Conclusion**

Postoperative SSTR-PET improves residual tumor detection compared with MRI and identifies additional potentially resectable disease. PET-guided assessment provides clinically relevant information for postoperative decision-making and may support re-resection in selected patients.





**Abstract Number:** 23

**Abstract Title:** 68Ga/177Lu-PSMA theranostics in recurrent high-grade glioma

**Authors:**

**Anna Maria Karlberg**<sup>1,2</sup>, Benedikte Emilie Vindstad<sup>1,3</sup>, Hanne Tøndel<sup>1</sup>, Håkon Johansen<sup>1,2</sup>, Thomas Morten Keil<sup>1</sup>, Erik Magnus Berntsen<sup>1,2</sup>, Ole Solheim<sup>1,2</sup>, Silje Kjærnes Øen<sup>1</sup>, Tora Skeidsvoll Solheim<sup>1,2</sup>, Live Eikenes<sup>1,2</sup>

<sup>1</sup>St. Olavs Hospital, Trondheim University Hospital, Trondheim, Norway, <sup>2</sup>Norwegian University of Science and Technology, Trondheim, Norway, <sup>3</sup>LMU University Hospital, LMU Munich, Munich, Germany

### Background

This study evaluated 68Ga/177Lu-PSMA theranostics as a treatment alternative for patients with recurrent high-grade glioma, aiming to improve diagnostic and therapeutic strategies and potentially enhance overall survival and quality of life.

### Material and Methods

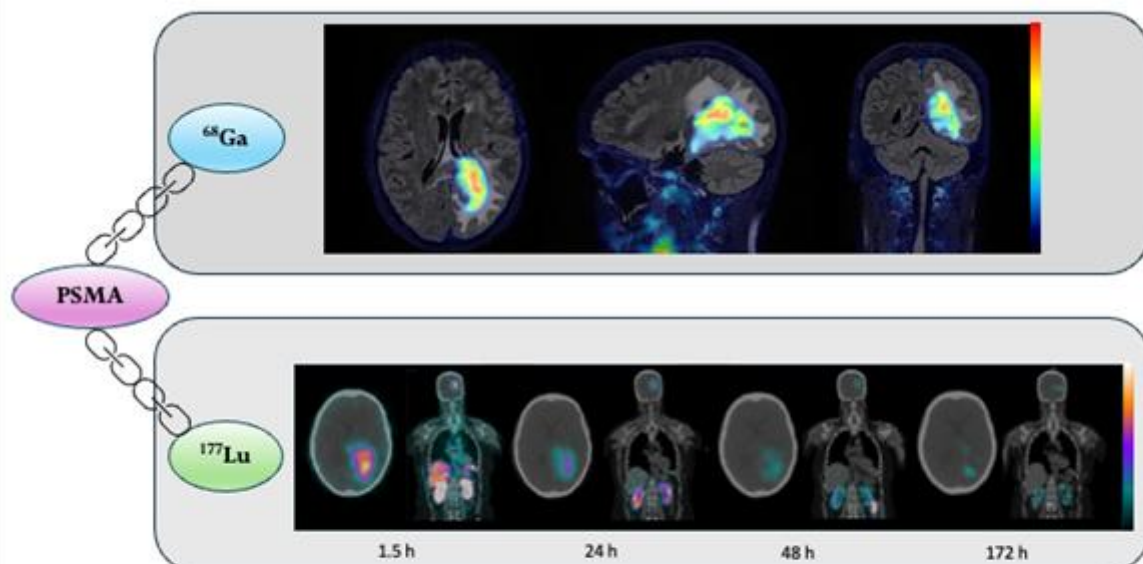
All patients received standard treatment with surgery, radiotherapy and chemotherapy prior to inclusion, and were left with no other treatment options at recurrence/progression. Eligible patients were selected for treatment based on a positive 68Ga-PSMA-PET examination. 177Lu-PSMA (7.4 GBq) was administered with 6-8 weeks intervals and continued as long as the patient tolerated the treatment well. The safety, tolerability and efficacy of 177Lu-PSMA were assessed during study visits in each treatment cycle using PET/MR, SPECT/CT, neurological tests, quality of life questionnaires and blood tests.

### Results

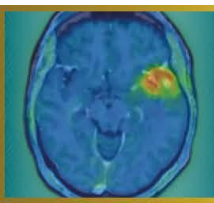
Ten patients were enrolled (grade 4 glioblastoma: n=6; grade 4 astrocytoma: n=1; grade 3 astrocytoma: n=3). 68Ga-PSMA-PET prior to treatment demonstrated tumor uptake in nine patients (median SUVmax: 6.4, range: 2.0-10.3), while uptake in normal brain was low (median SUVmean: 0.09, range: 0.02-0.11). Six patients met the eligibility criteria and have completed treatment. A total of 20 treatments have been administered (1-7 per patient). Median absorbed doses per treatment ranged from 2.6 Gy (range: 0.8-9.3 Gy) for tumors, 2.9 Gy (range: 1.2-4.4 Gy) for kidneys and 2.3 Gy (range: 0.5-3.4 Gy) for parotid glands. No grade 3 or grade 4 toxicities were observed. The most commonly patient reported symptoms were fatigue, transient xerostomia, and nausea. Radiological evaluation (MRI, RANO) demonstrated stable disease in half of the patients during the treatment cycles and progression in the other half. Figure 1 shows PET/MR and SPECT/CT images from one of the patients.

### Conclusion

Despite low tumor doses, the radiological stability of disease observed in half of the patients is promising. However, higher tumor doses may be required to achieve improved therapeutic efficacy.



A patient with a grade 4 glioblastoma treated with the radiotracer <sup>177</sup>Lu-PSMA at St. Olavs hospital (ClinicalTrials.gov.ID: NCT05644080). Top row: PET/MR images of the tumor uptake of <sup>68</sup>Ga-PSMA for diagnosis (SUV scale: 0-9). Bottom row: SPECT/CT images over the uptake of the therapeutic radiotracer <sup>177</sup>Lu-PSMA. Images at 1.5 h, 24 h, 48 h and 172 h post treatment show tumor accumulation of <sup>177</sup>Lu-PSMA up to 7 days post therapy. (SPECT scale: 0-200 counts for 1.5 h, 24 h and 48 h, and 0-50 counts for 172 h).



**Abstract Number:** 24

**Abstract Title:** IPAX BRiGHT: Pivotal study of iodofalan ( $^{131}\text{I}$ ) with or without lomustine vs lomustine alone for the treatment of patients with radiographically confirmed recurrent glioblastoma at first recurrence

**Authors:**

Arthur J A T Braat<sup>1,2</sup>, Dr. Nelleke Tolboom<sup>1</sup>, Andrew Scott<sup>3</sup>, Hui Gan<sup>3</sup>, **Daniela Divlianska**<sup>4</sup>, David Cade<sup>4</sup>, John de Groot<sup>5</sup>

<sup>1</sup>University Medical Centre Utrecht <sup>2</sup>Netherlands Cancer Institute <sup>3</sup>Austin Health <sup>4</sup>Telix Pharmaceuticals <sup>5</sup>University of California San Francisco

**Background**

With limited treatment options for glioblastoma, theranostic radiopharmaceuticals may address this unmet need. Glioblastomas overexpress LAT1, the target for 4-L- $^{131}\text{I}$ -iodophenylalanine (iodofalan [ $^{131}\text{I}$ ]). In IPAX-1 (Phase 1 study), iodofalan ( $^{131}\text{I}$ ) plus external beam radiation therapy in patients with recurrent glioblastoma demonstrated acceptable tolerability and specific tumor targeting. IPAX BRiGHT (NCT07100730) will evaluate iodofalan ( $^{131}\text{I}$ ) ± lomustine versus lomustine alone in patients with recurrent glioblastoma at first recurrence.

**Materials and Methods**

This multicenter, open-label study will include two parts: 1) safety and dosimetry lead-in, and 2) randomized treatment expansion. Eligibility criteria include age ≥18-years; previously confirmed glioblastoma (IDH-wildtype) diagnosis; and radiographic evidence of first recurrence or progressive glioblastoma after first-line treatment. Patients will be followed by conventional MRI and [ $^{18}\text{F}$ ]FET PET every 8 weeks. Safety, including clinical laboratory assessments and adverse events, will be continuously monitored throughout study. Part 1 will utilize a Bayesian Optimal Interval (BOIN) design to determine iodofalan ( $^{131}\text{I}$ ) maximum tolerated dose with lomustine, with a deescalation design (Figure). Arm A and B will receive three 42-day cycles of lomustine (Arm A: 90mg/m<sup>2</sup>; Arm B: 70mg/m<sup>2</sup>) plus iodofalan ( $^{131}\text{I}$ ). If both Arm A and B close due to reaching elimination boundary for lowest dose level, Arm C will open. Arm C will receive three 28-day cycles of iodofalan ( $^{131}\text{I}$ ) monotherapy. Iodofalan ( $^{131}\text{I}$ ) will be administered in all arms starting at 12 GBq total activity in 3x4 GBq fractions. Part 1 co-primary endpoints are safety and tolerability. In Part 2, patients will be randomized 1:1 to receive iodofalan ( $^{131}\text{I}$ ) ± lomustine at dose confirmed in Part 1 or lomustine 110 mg/m<sup>2</sup> alone. Part 2 primary endpoint is OS.

**Results**

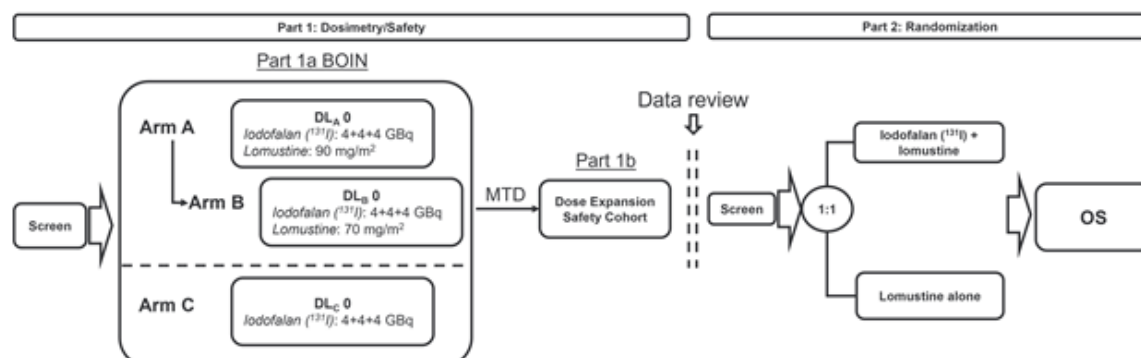
IPAX-BRiGHT is ongoing; no results are available.

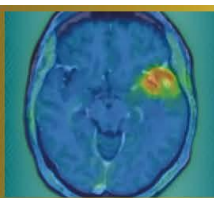
**Conclusion**

Iodofalan ( $^{131}\text{I}$ ) ± lomustine is expected to improve clinical outcomes in patients with recurrent glioblastoma.

This study is sponsored by Telix Pharmaceuticals.

Figure. Study design.





**Abstract Number:** 25

**Abstract Title:** IPAX-2: Phase 1 safety and dose finding study of iodofalan ( $^{131}\text{I}$ ) plus standard of care in patients with newly diagnosed glioblastoma

**Authors:**

Josef Pichler<sup>1</sup>, Nimit Singhal<sup>2</sup>, Hui Gan<sup>3</sup>, Arthur J A T Braat<sup>4</sup>, Wade Pullin<sup>5</sup>, Daniela Divlianksa<sup>6</sup>, David Cade<sup>6</sup>

<sup>1</sup>Department of Internal Medicine and Neuro-oncology, Kepler University Hospital, Johannes Kepler University

<sup>2</sup>Royal Adelaide <sup>3</sup>Austin Health <sup>4</sup>University Medical Centre Utrecht <sup>5</sup>Gold Coast University Hospital <sup>6</sup>Telix Pharmaceuticals

**Background**

Glioblastoma overexpresses LAT1, the target of 4-L- $^{131}\text{I}$  iodo-phenylalanine (iodofalan [ $^{131}\text{I}$ ]). In the Phase 1 IPAX-1 study,  $^{131}\text{I}$ -iodofalan plus external beam radiation therapy in patients with recurrent glioblastoma demonstrated acceptable tolerability and specific tumor targeting. IPAX-2 (NCT05450744) will evaluate iodofalan ( $^{131}\text{I}$ ) plus standard of care (SoC) in patients with newly diagnosed glioblastoma.

**Materials and Methods**

This Phase 1, multicentre, open-label, single-arm, parallel-group, dose-finding study will evaluate safety of ascending radioactive dose levels of iodofalan ( $^{131}\text{I}$ ) plus SoC in patients with newly diagnosed glioblastoma. Eligibility criteria include age  $\geq 18$  years; histologically-confirmed intracranial glioblastoma following surgical resection; no prior systemic therapy or radiation for glioblastoma; a Karnofsky Performance Status  $\geq 70$ ; plan to begin chemoradiation 3-6 weeks after surgical resection with Stupp regimen; adequate organ function; and adequate tissue samples previously archived.

Four cohorts (n=3/cohort) will encompass 3+3 dose escalation, beginning with iodofalan ( $^{131}\text{I}$ ) intravenously administered as 2 doses of 3 GBq each (dose escalation schedule: 2x3 GBq, 2x4 GBq, 2x5 GBq, 2x6 GBq). Dose 1 will be 7 days prior to chemoradiation, and dose 2 will be after last chemoradiation session. Chemoradiation will consist of 6 weeks of external beam radiation therapy (60 Gy/30 fractions) plus temozolomide 75 mg/m<sup>2</sup> daily. Following dose 2, patients will receive a 4-week treatment break before starting 6 maintenance cycles of temozolomide 150-200 mg/m<sup>2</sup> on days 1-5 every 28 days. [ $^{18}\text{F}$ ]FET PET will be used for metabolic tumor response assessment and excluding pseudoprogression. The co-primary objectives are 1) determine dose-limiting toxicity, maximum tolerated dose, and recommended Phase 2 dose, and 2) determine the incidence of treatment-emergent adverse events.

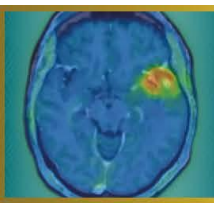
**Results**

IPAX-2 is ongoing; no results are available.

**Conclusion**

Iodofalan ( $^{131}\text{I}$ ) plus SoC has potential to improve clinical outcomes in patients with newly diagnosed glioblastoma.

This study is sponsored by Telix Pharmaceuticals.



**Abstract Number:** 26

**Abstract Title:** Study protocol for PRECISE, a pilot clinical trial of transarterial radioembolisation in patients with recurrent glioblastoma

**Authors:**

**Gaia Ninatti**<sup>1,2</sup>, Hamed Asadi<sup>1</sup>, Andrew Owen<sup>1</sup>, Lawrence Cher<sup>1</sup>, Sweet Ping Ng<sup>1</sup>, Mark Brooks<sup>1</sup>, Kylie Wilkie<sup>2</sup>, Arthur Braat<sup>3</sup>, Andrew M Scott<sup>1,2</sup>, Hui Gan<sup>1,2</sup>

<sup>1</sup>Austin Health, Melbourne, Australia, <sup>2</sup>Olivia Newton-John Cancer Research Institute, Melbourne, Australia, <sup>3</sup>UMC Utrecht, Utrecht, the Netherlands

**Background**

Despite maximal multimodal treatment, patients with glioblastoma (GBM) inevitably experience disease recurrence, and prognosis in the recurrent setting remains poor, with limited therapeutic options and modest survival benefit. The absence of treatments that meaningfully prolong survival highlights the need for new therapeutic approaches. Transarterial radioembolization (TARE) is an established locoregional treatment modality in liver malignancies, based on selective intra-arterial delivery of high-dose internal radiation to tumour vasculature. Although experience in brain tumours is limited, early data suggest that TARE is technically feasible and well tolerated. The PRECISE study will evaluate the safety and tolerability of TARE using 90Y-labelled resin microspheres (SIR-Spheres®) in patients with recurrent GBM.

**Material and Methods**

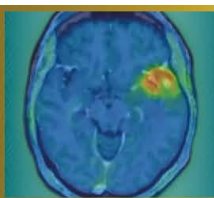
PRECISE is a prospective, single-centre pilot study planned to enrol 12 adults (≥18 years) with recurrent GBM. Key eligibility criteria include histologically confirmed IDH-wildtype GBM (WHO CNS 2021), radiological evidence of progression according to RANO criteria, and suitability for TARE. Screening assessment will include brain MRI, [18F]FET PET, and a planning angiographic procedure with intra-arterial administration of 99mTc-MAA. 99mTc-MAA SPECT will be used to assess tumour targeting, exclude relevant non-target activity, and perform voxel-based dosimetry for treatment planning. Eligible patients will undergo TARE with SIR-Spheres®. Activity will be prescribed to achieve complete tumour coverage, targeting a tumour V100 ≥90%. Treatment will consist of a single administration, with optional one-time re-treatment if appropriate. Primary endpoints are treatment-related adverse events within 30 days following TARE, graded according to CTCAEv5.0. Secondary endpoints include technical success rate, objective response rate and disease control rate according to RANO and PET RANO criteria, progression-free survival, and overall survival.

**Results**

Study commencement is anticipated in Q3 2026.

**Conclusion**

PRECISE is a pilot clinical trial evaluating the safety and tolerability of TARE using SIR-Spheres® in recurrent GBM, and will generate early clinical and dosimetric data to inform the design of future studies.



**Abstract Number:** 27

**Abstract Title:** Impact of Reconstruction Methods on Quantitative [18F]FET PET/CT Parameters in Pediatric Brain Tumor Imaging

**Authors:**

**Tamara Antonevskaya**<sup>1</sup>, Mikhail Yadgarov<sup>1</sup>, Yury Likar<sup>1</sup>

<sup>1</sup>Dmitry Rogachev National Medical Research Center Of Pediatric Hematology, Oncology And Immunology, Moscow, Russian Federation

### Background

Accurate and reproducible quantification of metabolic parameters from [18F]FET PET/CT is essential in neuro-oncology. Reconstruction methods may influence measurement consistency, affecting clinical interpretation.

### Material and Methods

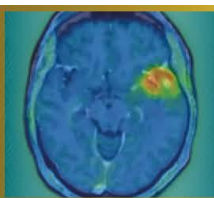
This retrospective study analyzed 15 pediatric patients with median age of 11 years (range: 1-16 years) with primary brain tumors. PET/CT datasets from one digital scanner (Discovery MI Gen 2, GE HealthCare) were processed using various reconstruction algorithms (OSEM+PSF, OSEM+PSF+TOF) and reconstruction parameters (iterations, subsets and Gaussian filter). Quantitative parameters such as SUVmax, SUVmean, tumor-to-background ratios (TBR), and volumetric measurements (MTV) were extracted and compared across reconstruction methods. Bland-Altman Method was used to assess reproducibility and agreement.

### Results

The analysis revealed that the reconstruction algorithm introduces a positive bias in SUVmax and TBRmax (biases +0.387 and +1.753, respectively), indicating higher values in most cases. The use of larger window size of Gaussian filter generally decreases SUVmax, and related parameters, as well as MTV (biases of -0.853 and -0.765, respectively). Variability in number of iterations strongly impacts SUVmax, TBRmax and MTV, with biases up to +0.807, +2.133 and +1.257, respectively. Variations in the number of subsets show the most variability overall, with biases reaching +3.275 for MTV and +2.133 for SUVmax. The least impacted parameter overall was background SUVmean, showing minimal bias under different reconstruction methods. In comparison, TBRmean and SUVmean were more sensitive to parameter changes, but still exhibited no substantial variation.

### Conclusions

Reconstruction methods substantially influence quantitative [18F]FET PET/CT parameters in brain tumor imaging. Standardized reconstruction protocols are vital for ensuring measurement reliability, supporting consistent interpretation in clinical and research contexts. Protocol harmonization remains critical for optimizing the utility of [18F]FET PET/CT in pediatric neuro-oncology.



**Abstract Number:** 28

**Abstract Title:** Functional connectivity decline in glioma patients is associated with metabolic tumor progression according to the PET RANO 1.0 criteria

**Authors:**

**Manuel Kraft**<sup>1,2</sup>, Julia Hilgers<sup>2</sup>, Jana-Marie Peplinski<sup>1</sup>, Jan-Michael Werner<sup>1</sup>, Garry Ceccon<sup>1</sup>, Michael Wollring<sup>1</sup>, Isabelle Stetter<sup>1</sup>, Gereon R. Fink<sup>1,2</sup>, Karl-Josef Langen<sup>2,3</sup>, Felix M. Mottaghy<sup>3</sup>, Keith George Ciantar<sup>2,4</sup>, Nadim J. Shah<sup>2</sup>, Philipp Lohmann<sup>2,3</sup>, Martin Kocher<sup>2,5</sup>, Norbert Galldiks<sup>1,2</sup>

<sup>1</sup>Dept. of Neurology, University Hospital Cologne, Cologne, Germany, <sup>2</sup>Inst. of Neuroscience and Medicine (INM-3, INM-4), Research Center Juelich, Juelich, Germany, <sup>3</sup>Dept. of Nuclear Medicine, RWTH Aachen University Hospital Aachen, Aachen, Germany, <sup>4</sup>Inst. for Imaging and Computer Vision, RWTH Aachen University, Aachen, Germany, <sup>5</sup>Dept. of Stereotactic and Functional Neurosurgery, University Hospital Cologne, Cologne, Germany

**Background**

The emerging field of cancer neuroscience suggests intense structural and functional connections between gliomas and the CNS, leading to large-scale network alterations. These could be reflected in functional connectivity (FC), measured using resting-state fMRI (rs-fMRI). Functional network connectivity data obtained from single scans has been associated with tumor grade and overall survival. Using repeated scans, we examined changes in FC in patients with gliomas and their association with metabolic changes in amino acid PET using the tracer O-(2-[<sup>18</sup>F]-fluoroethyl)-L-tyrosine (FET).

**Materials and methods**

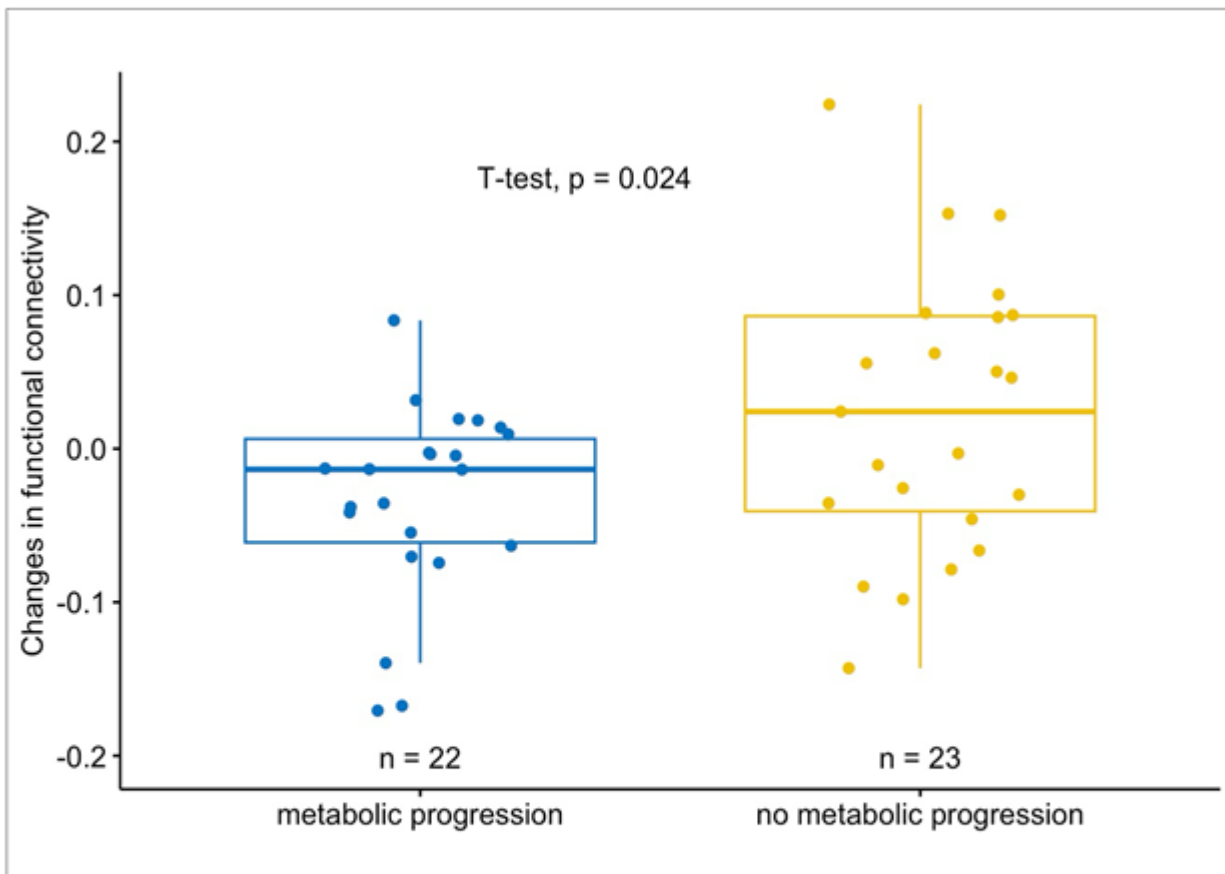
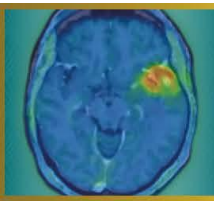
In a retrospective study, 45 patients with gliomas (WHO CNS 2021: glioblastoma, n=27; astrocytoma, n=8; oligodendroglioma, n=10), who underwent both rs-fMRI and FET PET before and after (mean time interval, 6 months) chemoradiation (n=27), surgery (n=9), or no treatment (n=9) were evaluated. Metabolic changes in FET PET were assessed using the PET-RANO 1.0 criteria, dividing into patients with metabolic progression (n=22, comprising Progressive Disease) and those without metabolic progression (n=23, comprising Complete Response, Partial Response, and Stable Disease). FC was assessed by examining the BOLD-activity time course correlations in rs-fMRI. Out of seven canonical resting-state networks, the individual network at risk for each patient was identified through maximum proportional tumor overlap with the network. Finally, changes in FC within the networks at risk were analyzed.

**Results**

Within individual networks at risk, there was a significant difference in FC changes between the two groups (p=0.024). Patients with metabolic tumor progression in FET PET showed a decrease in FC over time, whereas patients without metabolic tumor progression showed an increase in FC.

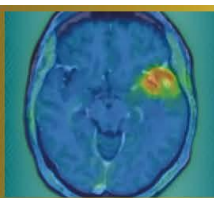
**Discussion and conclusion**

Our data suggest that FC declines throughout the course of metabolic tumor progression and increases following effective treatment in patients with gliomas. This highlights a possible role for rs-fMRI in predicting tumor progression and treatment response.



**Figure 1.** FC Changes Within the Network at Risk by Metabolic Changes

Boxplots depicting significant differences in changes in functional connectivity within the *network at risk* between patients with and without metabolic tumor progression in FET PET



**Abstract Number:** 29

**Abstract Title:** The NMN-BBB score as a prognostic marker in newly diagnosed glioblastoma: a single-center, retrospective study

**Authors:**

**Roman Stürzl**<sup>1</sup>, Katharina J Müller<sup>2</sup>, Jonas Reis<sup>3</sup>, Thomas Schabhüttl<sup>1,4</sup>, Isabelle von Polenz<sup>1</sup>, Lena Kaiser<sup>1</sup>, Maximilian J Mair<sup>1,4</sup>, Louisa von Baumgarten<sup>2,5,6,7</sup>, Patrick Harter<sup>6,7,8</sup>, Stephan Schönecker<sup>9</sup>, Darius Kalasauskas<sup>5</sup>, Florian Ringel<sup>5</sup>, Prof. Matthias Preusser<sup>4</sup>, Nathalie L Albert<sup>1,6,7</sup>

<sup>1</sup>Department of Nuclear Medicine, LMU University Hospital, LMU Munich, Munich, Germany, <sup>2</sup>Department of Neurology, LMU University Hospital, LMU Munich, Munich, Germany, <sup>3</sup>Institute of Neuroradiology, LMU University Hospital, LMU Munich, Munich, Deutschland, <sup>4</sup>Division of Oncology, Department of Medicine I, Medical University of Vienna, Vienna, Austria, <sup>5</sup>Department of Neurosurgery, LMU University Hospital, LMU Munich, Munich, Deutschland, <sup>6</sup>Bavarian Cancer Research Center (BZKF), Partner Site Munich, Munich, Deutschland, <sup>7</sup>German Cancer Consortium (DKTK), Partner Site Munich, Munich, Germany, Munich, Deutschland, <sup>8</sup>Center for Neuropathology and Prion Research, Faculty of Medicine, LMU Munich, Munich, Deutschland, <sup>9</sup>Department of Radiation Oncology, LMU University Hospital, LMU Munich, Munich, Deutschland

**Background**

The NMN-BBB score integrates contrast-enhanced MRI and [18F]FET PET to semi-quantitatively grade blood-brain barrier (BBB) disruption within metabolically active glioblastoma tissue and has been proposed as a pragmatic tool to facilitate patient selection for clinical trials. In this retrospective single-center study we investigated the prognostic value of the NMN-BBB score.

**Methods**

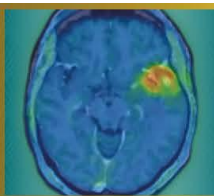
141 patients with newly diagnosed glioblastoma, IDH-wildtype were included. We analyzed progression-free survival (PFS), overall survival (OS) and time-to-next-intervention (TTNI) using Kaplan-Meier estimates, uni- and multivariate Cox regression. For exploratory purposes NMN-BBB scores X, 1 and 2 (n=56) as well as score 3-5 (n=85) were grouped.

**Results**

PFS differed significantly between NMN-BBB score groups. Median PFS was 19.2 months in patients with a score of X, 1 or 2 and 12.5 months in those with score 3-5 (p<0.001). A higher score was associated with shorter PFS in univariable Cox regression (p=0.005) and remained significant after multivariable adjustment (p=0.002). OS also differed significantly with a median of 45.8 months for score X-2 and 18.0 months for score 3-5 (p=0.006). These findings were persistent in both univariate (p=0.007) and multivariate models (p<0.001). TTNI was also significantly shorter in the higher-score group. Median TTNI was 10.7 months for score 3-5 and 15.4 months for score X-2 (p=0.046) with the association remaining significant in both uni- and multivariable analyses.

**Conclusion**

The NMN-BBB score showed an inverse association with patient outcome parameters including PFS, OS and TTNI. Further studies are needed to validate our findings. The NMN-BBB score may support baseline risk stratification and patient selection for clinical trials in newly diagnosed glioblastoma.



**Abstract Number:** 30

**Abstract Title:** SSTR PET Characteristics of Newly Diagnosed Meningiomas: Correlation with Neuropathological Diagnosis and Molecular Profile

**Authors:**

**Thomas Schabhüttl**<sup>1,2</sup>, Maximilian J. Mair<sup>1,2</sup>, Thomas Eska<sup>3,4</sup>, Enio Barci<sup>1</sup>, Ergi Istrefi<sup>1</sup>, Tobias Greve<sup>5,8</sup>, Christian Schichor<sup>5</sup>, Annamaria Biczok<sup>6</sup>, Matthias Philipp Fabritius<sup>7</sup>, Prof. Matthias Preusser<sup>2</sup>, Patrick Harter<sup>3,4,8</sup>, Nathalie L. Albert<sup>1,4,8</sup>

<sup>1</sup>Department of Nuclear Medicine, LMU University Hospital, LMU Munich, Munich, Germany, <sup>2</sup>Division of Oncology, Department of Medicine I, Medical University of Vienna, Vienna, Austria, <sup>3</sup>Center for Neuropathology and Prion Research, Institute of Neuropathology, Medical Faculty LMU University Hospital, LMU Munich, Munich, Germany, <sup>4</sup>German Cancer Consortium (DKTK) partner site Munich, Germany and German Cancer Research Center (DKFZ), Heidelberg, Germany, <sup>5</sup>Department of Neurosurgery, LMU University Hospital, LMU Munich, Munich, Germany, <sup>6</sup>Department of Neurosurgery, University Hospital Heidelberg, Heidelberg University, Heidelberg, Germany, <sup>7</sup>Department of Radiology, LMU University Hospital, LMU Munich, Munich, Germany, <sup>8</sup>Bavarian Cancer Research Center (BZKF), Munich, Germany

**Background**

This study investigates the association between somatostatin receptor (SSTR) PET imaging features and histological as well as molecular characteristics of newly diagnosed meningiomas.

**Methods**

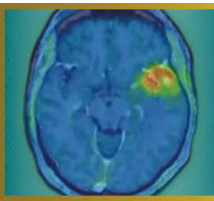
Patients with newly diagnosed, histologically confirmed meningioma who underwent preoperative SSTR PET/CT (<sup>68</sup>Ga]Ga-DOTATATE/-DOTATOC or [<sup>18</sup>F]F-SiTATE) were retrospectively analyzed. Clinical, demographic, histological (WHO grade, histological subtype), and molecular data (copy number variations (CNV), DNA methylation profile) were collected. PET/CT parameters included SUVmax, SUVmean, PET volume (using a fixed SUV threshold of  $\geq 4.0$ ), lesion size on CT (maximum perpendicular diameter), as well as the presence of multifocality, osseous involvement, and intralesional heterogeneity.

**Results**

A total of 121 patients with newly diagnosed meningioma (108 WHO grade 1, 13 WHO grade 2) were evaluated. Median SUVmax was 17.4 in WHO grade 1 and 23.4 in WHO grade 2 meningiomas ( $p = 0.68$ ), with a corresponding SUVmean of 8.4 and 8.3, respectively. PET volume was significantly larger in WHO grade 2 compared with WHO grade 1 meningiomas (41.9 mL vs. 18.1 mL;  $p < 0.001$ ), in line with results previously described in the literature. Multifocality, osseous involvement, and intralesional heterogeneity did not differ between WHO grades. In subgroup analyses, secretory meningiomas demonstrated a significantly higher SUVmax compared with other histological subtypes (62.2 vs. 16.2 (meningothelial) vs. 16.1 (transitional) vs. 21.5 (atypical);  $p < 0.001$  for pairwise comparisons). Molecular pathological analyses are currently ongoing and will be supplemented.

**Conclusions**

While WHO grade 1 and WHO grade 2 meningiomas do not show significant differences in uptake intensity or uptake patterns, WHO grade 2 meningiomas exhibit significantly larger PET volumes. Among histological subgroups, secretory meningiomas demonstrate more than a threefold higher uptake intensity compared with other subtypes. Ongoing molecular pathological correlations will clarify whether PET differences are also observed among molecular subtypes.



**Abstract Number:** 31

**Abstract Title:** Noninvasive discrimination of CDKN2A/B status and WHO grading using [18F]FET-PET imaging in IDH-mutant astrocytoma

**Authors:**

**Katharina J. Müller**<sup>1</sup>, Maximilian Mair<sup>2</sup>, Jan-Michael Werner<sup>3</sup>, PD Dr. med. Michael Müther<sup>4</sup>, Wolfgang Roll<sup>5</sup>, Artem Chaban<sup>6</sup>, Jonas Reis<sup>7</sup>, Thomas Schabhüttl<sup>2,8</sup>, Julia Hilgers<sup>9</sup>, Keith George Ciantar<sup>9,10</sup>, Philipp Lohmann<sup>9,11</sup>, Patrick Harter<sup>12</sup>, Louisa von Baumgarten<sup>1,13</sup>, Claira Delbridge<sup>14</sup>, Igor Yakushev<sup>6</sup>, Johannes Hainfellner<sup>15</sup>, Georg Widhalm<sup>16</sup>, Markus Hacker<sup>17</sup>, Norbert Galldiks<sup>3,9</sup>, Matthias Preusser<sup>2</sup>, Nathalie L. Albert<sup>8</sup>

<sup>1</sup>Department of Neurology, LMU University Hospital, LMU Munich, Munich, Germany, <sup>2</sup>Division of Oncology, Department of Medicine I, Medical University of Vienna, Vienna, Austria, <sup>3</sup>Department Neurology, Faculty of Medicine and University Hospital Cologne, , Cologne, Germany, <sup>4</sup>Department of Neurosurgery, University Hospital Münster, Münster, Germany, <sup>5</sup>Department of Nuclear Medicine, University Hospital Münster, Münster, Germany, <sup>6</sup>Department of Nuclear Medicine, Technical University Hospital of Munich, Munich, Germany, <sup>7</sup>Department of Neuroradiology, LMU University Hospital, LMU Munich, Munich, Germany, <sup>8</sup>Department of Nuclear Medicine, LMU University Hospital, Munich, Germany, <sup>9</sup>Institute of Neuroscience and Medicine (INM-3, INM-4), Research Center Juelich (FZJ), Juelich, Germany, <sup>10</sup>Institute for Imaging and Computer Vision, RWTH Aachen University, Aachen, Germany, <sup>11</sup>Department for Nuclear Medicine, RWTH Aachen University Hospital, , Germany, <sup>12</sup>Center for Neuropathology and Prion Research, LMU University Hospital, Munich, Germany, <sup>13</sup>Department of Neurosurgery, LMU University Hospital, , Munich, Germany, <sup>14</sup>Institute of Pathology, Department of Neuropathology, Technical University Hospital of Munich, Munich, Germany, <sup>15</sup>Department of Neurology, Medical University of Vienna, Vienna, Germany, <sup>16</sup>Department of Neurosurgery, Medical University of Vienna, Vienna, Germany, <sup>17</sup>Division of Nuclear Medicine, Medical University of Vienna, Vienna, Germany

**Background**

With the introduction of the 2021 WHO classification, molecular profiling has become central to glioma diagnosis. Homozygous CDKN2A/B deletion defines WHO grade 4 in IDH-mutant astrocytoma, independent of histologic features. However, molecular diagnostics are time-consuming, underscoring the clinical need for surrogate biomarkers that enable early identification of aggressive tumor biology. The aim of this study was to investigate the value of [18F]FET-PET imaging for prediction of molecular tumor biology in IDH-mutant astrocytoma.

**Methods**


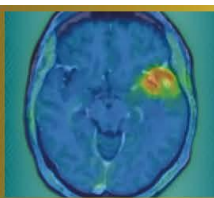
In this multicentric, retrospective study we correlated [18F]FET-PET metrics DNA-methylation-based molecular diagnosis. The discovery cohort (University Hospital of Munich) included 89 patients with IDH-mutant astrocytoma, all with known CDKN2A/B status and available [18F]FET-PET (imaging performed 3 months before/after NGS). Quantitative PET parameters (SUVmax, SUVmean, TBRmax, TBRmean, PET-positive volume) were analyzed. Findings were validated in an external cohort of 119 patients with IDH-mutant astrocytoma from four independent neuro-oncological centers.

**Results**

In the discovery cohort (n=89, median age 41 years, IQR 18-64), tumors with homozygous CDKN2A/B loss demonstrated a median TBRmax of 2.6 (IQR, 2.5–3.7), which was significantly higher than in WHO grade 2 and 3 astrocytoma (median TBRmax in WHO grade 2: 1.5; IQR 1-2.2; median TBRmax in WHO grade 3: 1.8; IQR 1-2.2; p=0.003). ROC analysis demonstrated that TBRmax (at a cutoff of 2.4) identified astrocytomas with molecular and/or histologic WHO grade 4 with a sensitivity of 0.93 and specificity of 0.82 (AUC=0.89, p<0.001). These results were reproducible in the external validation cohort, yielding a sensitivity of 0.81 and specificity of 0.83 (AUC=0.87, p<0.001).

**Conclusion**

[18F]FET-PET-derived TBRmax is significantly increased in cases with homozygous CDKN2A/B loss and/or histologic WHO grade 4 and may serve as a noninvasive surrogate for high-grade astrocytoma. Integration of PET imaging with genomic profiling has the potential to support treatment planning, however further investigation for optimized thresholding is warranted.



**Abstract Number:** 32

**Abstract Title:** The prognostic significance of TSPO-PET imaging in IDH-mutant glioma: a single-center, retrospective study

**Authors:**

**Katharina J. Müller**<sup>1</sup>, Roman Stürzl<sup>2</sup>, Sabrina Kirchleitner<sup>3</sup>, Isabelle von Polenz<sup>2</sup>, Viktoria Ruf<sup>4</sup>, Veit M. Stoecklein<sup>3,5</sup>, Jonas Reis<sup>6</sup>, Stefanie Quach<sup>3,7</sup>, Lena Kaiser<sup>2</sup>, Julia Lorenz<sup>8</sup>, Adrian Zounek<sup>2</sup>, Patrick N. Harter<sup>4,5,9</sup>, Rainer Rupprecht<sup>10</sup>, Markus J. Riemenschneider<sup>8</sup>, Matthias Brendel<sup>2,11,12</sup>, Niklas Thon<sup>3</sup>, Joerg-Christian Tonn<sup>3</sup>, Louisa von Baumgarten<sup>1,3,5,9</sup>, Nathalie L. Albert<sup>2</sup>

<sup>1</sup>Department of Neurology, LMU University Hospital, LMU Munich, Germany, Munich, <sup>2</sup>Department of Nuclear Medicine, LMU University Hospital, LMU Munich, Germany, <sup>3</sup>Department of Neurosurgery, LMU University Hospital, LMU Munich, Germany, <sup>4</sup>Center for Neuropathology and Prion Research, Faculty of Medicine, LMU Munich, Germany, <sup>5</sup>German Cancer Consortium (DKTK), Partner Site Munich, a Partnership Between DKFZ and LMU University Hospital, Munich, Germany, <sup>6</sup>Institute of Neuroradiology, LMU University Hospital, LMU Munich, Germany, <sup>7</sup>Department of Neurosurgery (Evangelisches Klinikum Bethel), Medical School, Bielefeld University, Bielefeld, Germany, <sup>8</sup>Department of Neuropathology, Regensburg University Hospital, Regensburg, Germany, <sup>9</sup>Bavarian Cancer Research Center (BZKF), Munich, Germany, <sup>10</sup>Department of Psychiatry and Psychotherapy, Molecular Neurosciences, University of Regensburg, Regensburg, Germany, <sup>11</sup>German Center for Neurodegenerative Diseases (DZNE) Munich, Munich, Germany, <sup>12</sup>Munich Cluster for Systems Neurology (SyNergy), Munich, Germany

**Purpose**

Clinical prognostication and decision-making in IDH-mutant glioma is increasingly complex, especially with new targeted treatment options like IDH-inhibitors. Individual patient risk stratification for better treatment planning is needed; however, standard prognostic models rely on clinical and histologic parameters as well as MRI, which may not fully reflect the tumor's biological behavior. Positron emission tomography (PET) imaging of the 18 kDa translocator protein (TSPO) is known as surrogate marker of activated microglia and macrophages and enables non-invasive assessment of the tumor microenvironment and peri-/intratumoral inflammation as well as TSPO-positive tumor cells. The aim of this study was to investigate TSPO-PET imaging in IDH-mutant glioma and its association with outcome.

**Methods**

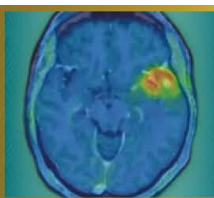
In this monocentric, retrospective study, 46 patients with newly diagnosed IDH-mutant glioma who had undergone TSPO-PET imaging with [<sup>18</sup>F]GE180 prior to any therapeutic intervention were included. Quantitative PET parameters including mean and maximum standardized uptake values (SUVmax, SUVmean) and the respective PET-positive tumor volumes were evaluated for their association with clinical data and time to next intervention (TTNI), and overall survival (OS).

**Results**

The cohort consisted of 27 patients (58.7%) with astrocytoma, IDH-mutant (median age 36 years (30-51)) and 19 patients (41.3%) with oligodendroglioma, IDH-mutant and 1p/19q-codeleted (median age 41 years (36-48)). High SUVmax on TSPO-PET imaging was associated with shorter TTNI, and OS (p=0.0118 and p=0.0459, respectively). In multivariate analyses adjusting for age, KPS, WHO grade, FET-PET-positive volume, and tumor area on contrast-enhanced MRI, the TSPO-PET-positive signal (SUVmax) remained independently associated with TTNI (hazard ratio (HR)=4.342, 95% CI: 1.222 to 15.47, p=0.0238).

**Conclusions**

This study highlights the potential prognostic utility of TSPO-PET imaging in newly diagnosed IDH-mutant glioma. Our findings support the inclusion of PET imaging in future clinical trials to develop imaging-based risk models for better prognostication and individualized treatment guidance.



**Abstract Number:** 33

**Abstract Title:** [18F]FET PET characteristics in recurrent oligodendroglioma – considerations for clinical trials

**Authors:**

**Maximilian Mair**<sup>1,2</sup>, Jera Isakaj<sup>1</sup>, Jonas Reis<sup>3</sup>, Enio Barci<sup>1</sup>, Jonathan Weller<sup>4</sup>, Sophie Katzendobler<sup>4</sup>, Matthias Preusser<sup>2</sup>, Patrick N. Harter<sup>5,6,7</sup>, Louisa von Baumgarten<sup>4,6,7,8</sup>, Niklas Thon<sup>4,9</sup>, Nathalie L. Albert<sup>1,6,7</sup>

<sup>1</sup>Department of Nuclear Medicine, LMU University Hospital, LMU Munich, Munich, Germany, <sup>2</sup>Division of Oncology, Department of Medicine I, Medical University of Vienna, Vienna, Austria, <sup>3</sup>Institute of Neuroradiology, LMU University Hospital, LMU Munich, Munich, Germany, <sup>4</sup>Department of Neurosurgery, LMU University Hospital, LMU Munich, Munich, Germany, <sup>5</sup>Center of Neuropathology and Prion Research, LMU University Hospital, LMU Munich, Munich, Germany, <sup>6</sup>Bavarian Cancer Research Center (BZKF), Partner Site Munich, Munich, Germany, <sup>7</sup>German Cancer Consortium (DKTK), Partner Site Munich, Munich, Germany, <sup>8</sup>Department of Neurology, LMU University Hospital, LMU Munich, Munich, Germany, <sup>9</sup>Department of Neurosurgery, Knappschaft University Hospital Bochum, Bochum, Germany

**Background**

Oligodendroglioma (IDH-mutant, 1p/19q-codeleted) has a comparably favorable prognosis among diffuse gliomas, but recurrences are frequent and challenging to treat after previous therapy. While measurable disease according to MRI is frequently used as an inclusion criterion for clinical trials in glioma, uptake in amino acid PET might represent a rational eligibility criterion in this setting. However, such parameters are poorly characterized.

**Material and Methods**



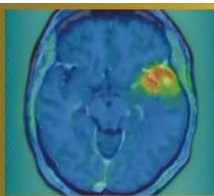
In this retrospective cohort study, patients with oligodendroglioma (IDH-mutant, 1p/19q-codeleted) and O-(2-[18F]-fluoroethyl)-L-tyrosine ([18F]FET) PET at recurrence (histologically verified and/or high clinical/radiological suspicion) were included. PET imaging was evaluated according to PET RANO 1.0 criteria, and uptake (maximum/mean tumor-to-background ratios; TBRmax, TBRmean) as well as PET-positive volume (PET volume) were measured.

**Results**

In total, 146 patients with overall 148 recurrences of oligodendroglioma (IDH-mutant, 1p/19q-codeleted) were included, of whom 80 (54.8%) were male. Median age at PET at recurrence was 49 years (range: 21-77), and median time from first documented surgery to PET at recurrence was 5.6 years (range: 0.2-18.3). According to PET RANO 1.0 criteria, PET measurable disease was observed in 132/148 (89.2%), followed by non-measurable in 14/148 (9.5%) and no measurable disease in 2/148 (1.4%) at recurrence. Median TBRmax was 2.91 (range: 1.48-9.39), median TBRmean was 1.97 (range: 1.65-3.00), and median PET volume was 15.2 mL (range: 0.16-199.64). In 29 patients, data from previous PET at initial diagnosis were available. In these cases, there was no difference in TBRmax ( $p = 0.214$ ) or TBRmean ( $p = 0.702$ ) between initial diagnosis and recurrence.

**Conclusion**

The majority of oligodendrogliomas at recurrence shows high uptake in amino acid PET and measurable disease according to PET RANO 1.0 criteria. These findings could inform the design of clinical trials investigating novel therapeutic agents including radiolabeled amino acid analogues in this patient population.



**Abstract Number:** 34

**Abstract Title:** Validation of PET RANO 1.0 criteria in a retrospective, single-center cohort of patients with IDH-mutant glioma

**Authors:**

**Maximilian Mair**<sup>1,2</sup>, Theodora Aras-Brendler<sup>1</sup>, Jonas Reis<sup>3</sup>, Isabelle von Polenz<sup>1</sup>, Lilian Wiegand<sup>1</sup>, Roman Stürzl<sup>1</sup>, Enio Barci<sup>1</sup>, Katharina J. Müller<sup>4</sup>, Jonathan Weller<sup>5</sup>, Sophie Katzendobler<sup>5</sup>, Matthias Preusser<sup>2</sup>, Stephan Schönecker<sup>6</sup>, Patrick N. Harter<sup>7,8,9</sup>, Niklas Thon<sup>5,10</sup>, Louisa von Baumgarten<sup>4,5,8,9</sup>, Nathalie L. Albert<sup>1,8,9</sup>

<sup>1</sup>Department of Nuclear Medicine, LMU University Hospital, LMU Munich, Munich, Germany, <sup>2</sup>Division of Oncology, Department of Medicine I, Medical University of Vienna, Vienna, Austria, <sup>3</sup>Institute of Neuroradiology, LMU University Hospital, LMU Munich, Munich, Germany, <sup>4</sup>Department of Neurology, LMU University Hospital, LMU Munich, , Germany, <sup>5</sup>Department of Neurosurgery, LMU University Hospital, LMU Munich, Munich, Munich, Germany, <sup>6</sup>Department of Radiation Oncology, LMU University Hospital, LMU Munich, Munich, Germany, <sup>7</sup>Center of Neuropathology and Prion Research, Faculty of Medicine, LMU Munich, Munich, Germany, <sup>8</sup>Bavarian Cancer Research Center (BZKF), Partner Site Munich, Munich, Germany, <sup>9</sup>German Cancer Consortium (DKTK), Partner Site Munich, Munich, Germany, <sup>10</sup>Department of Neurosurgery, Knappschaft University Hospital Bochum, Bochum, Germany

**Background**

PET RANO 1.0 criteria were designed as a consensus-based, standardized framework for response assessment in glioma. However, validation in well-annotated cohorts as well as correlative analyses with outcome are urgently needed.

**Material and Methods**


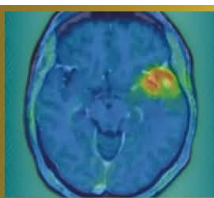
Patients with IDH-mutant glioma and at least two O-(2-[<sup>18</sup>F]-fluoroethyl)-L-tyrosine ([<sup>18</sup>F]FET) PET scans during one treatment line in 02/2013 - 08/2025 were eligible for this retrospective study. PET-based response assessment was performed applying PET RANO 1.0 criteria based on maximum and mean tumor-to-background ratios (TBR<sub>max</sub>/TBR<sub>mean</sub>) and PET volume. Intervention-free survival (IFS) was used as survival endpoint.

**Results**

219 patients (106 [48.4%] astrocytoma, 110 [50.2%] oligodendroglioma, 3 with inconclusive 1p/19q testing) with 251 lesions were included. Of these, 117 (53.4%) were male, and responses in 220 treatment lines (173 [78.6%] first line treatment; 47 [21.4%] recurrence/progression) were analyzed. Time between PET scans was 6.7 months in median (range: 2.4-11.8). During first-line treatment, PET-based complete remission (PET-CR) was seen in 7/173 (4.0%), partial remission (PET-PR) in 32/173 (18.5%), stable disease (PET-SD) in 74/173 (42.8%), and progressive disease (PET-PD) in 60/173 (34.7%) patients. PET-PD was primarily based on PET volume increase alone (27/60, 45.0%) or combined with an increase in maximum/mean tumor-to-background ratios (TBR<sub>max</sub>/TBR<sub>mean</sub>; 19/60, 31.7%), followed by new measurable disease in 14/60 (23.3%) patients. IFS was longer in patients with PET-SD/-PR/-CR (33.6 months; 95%CI: 27.1-48.3) compared to PET-PD (13.3 months; 95%CI: 9.5-27.6; p = 0.005). At recurrence, PET-CR was observed in 3/47 (6.4%), PET-PR in 16/47 (34.0%), PET-SD in 24/47 (51.1%) and PET-PD in 4/47 (8.5%) patients, with numerical IFS differences (p = 0.16) according to PET response.

**Conclusion**

PET RANO 1.0 responses are prognostically relevant in IDH-mutant glioma. Further analyses integrating MRI-based response assessment are ongoing to inform the development of rational clinical trial endpoints in this population.



**Abstract Number:** 35

**Abstract Title:** A Phase 1 trial to determine the maximum tolerated dose and patient-specific dosimetry of fractionated intracavitary radioimmunotherapy with Lutetium-177 labeled 6A10 Fab fragments in patients with glioblastoma – an updated interim report

**Authors:**

**Wolfgang Roll**<sup>1</sup>, PD Dr. med. Michael Mütter<sup>1</sup>, Guido Böning<sup>2</sup>, Franz-Josef Gildehaus<sup>2</sup>, Claire Delbridge<sup>3</sup>, Nathalie L. Albert<sup>2</sup>, Michael Schäfers<sup>1</sup>, Astrid Delker<sup>2</sup>, Lars Stegger<sup>1</sup>, Reinhard Zeidler<sup>4</sup>, Hans-Jürgen Reulen<sup>2</sup>, Prof. Walter Stummer<sup>1</sup>

<sup>1</sup>University Hospital Münster, Münster, Germany, <sup>2</sup>LMU University Hospital, Ludwig-Maximilians-University, Munich, Germany, <sup>3</sup>Technical University of Munich, Munich, Germany, <sup>4</sup>Helmholtz Center Munich, Munich, Germany

**Background**

Following maximal safe resection and standard adjuvant radio- and chemotherapy, approved maintenance therapies for glioblastoma are lacking. Intracavitary radioimmunotherapy (iRIT) injected into the resection cavity offers a promising strategy for improving local tumor control. This is an updated interim report of the NOA-22 study (NCT05533242).

**Material and Methods**

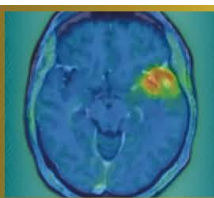
This prospective single-armed, multicenter phase 1 study, following a modified 3+3-design, investigates the use of 6A10-Fab fragments targeting carbonic anhydrase XII, labeled with lutetium-177 ([<sup>177</sup>Lu]Lu-6A10- Fab). Patients with glioblastoma after concomitant radio-chemotherapy and adjuvant standard chemotherapy with no or small residual disease are included. The injected activity is adapted to the volume of the resection cavity, resulting in a dose of 44Gy (cohort 1), 48Gy (cohort 2) and 52Gy (cohort 3). Primary study objective is to determine the maximum tolerated dose and safety of adjuvant radio-immunotherapy with [<sup>177</sup>Lu]Lu-6A10-Fab.

**Results**

Following the completion of cohorts 1 and 2, which comprised three patients each, two patients have entered cohort 3. Two patients from cohort 1 presented with reversible adverse events of grades 2 and 3 (CTCAE 5.0). One patient presented with perifocal brain edema that decreased after a course of steroid treatment. A second patient experienced a single seizure that responded to steroids and antiepileptic medication, accompanied by increasing perifocal edema on MRI. No hematological adverse events of grades 3 or higher occurred. Dosimetry did not reveal absorbed doses above the upper dose limits for organs at risk. So far, no patient experienced progressive disease after accrual start in January 2024 (follow-up range: 5-24 months).

**Conclusion**

Intracavitary administration of [<sup>177</sup>Lu]Lu-6A10-Fab appears feasible and safe. The study is currently enrolling its final patients in cohort 3, and we expect complete 6-month follow-up for the full cohort by the end of 2026 to initiate per-protocol analyses.



**Abstract Number:** 36

**Abstract Title:** Assessment of 18F-FET PET-based response to contemporary CNS-active systemic agents in patients with brain metastases using the PET RANO BM 1.0 criteria

**Authors:**

**Jana-Marie Peplinski**<sup>1</sup>, Julia Hilgers<sup>2</sup>, Keith George Ciantar<sup>2,3</sup>, Manuel Kraft<sup>1,2</sup>, Jan-Michael Werner<sup>1</sup>, Garry Ceccon<sup>1</sup>, Michael Wollring<sup>1</sup>, Isabelle Stetter<sup>1</sup>, Gabriele Stoffels<sup>2</sup>, Gereon R. Fink<sup>1,2</sup>, Karl-Josef Langen<sup>2,4</sup>, Philipp Lohmann<sup>2,4</sup>, Norbert Galldiks<sup>1,2</sup>

<sup>1</sup>Dept. of Neurology, Faculty of Medicine and University Hospital Cologne, Cologne, Germany, <sup>2</sup>Inst. of Neuroscience and Medicine (INM-3, INM-4), Research Center Juelich, Juelich, Germany, <sup>3</sup>Inst. for Imaging and Computer Vision, RWTH Aachen University, Aachen, Germany, <sup>4</sup>Dept. of Nuclear Medicine, RWTH Aachen University Hospital, Aachen, Germany, Germany

**Background**

Following multimodal brain metastases treatment, amino acid PET may improve diagnostic certainty when MRI findings remain equivocal. We evaluated the recently defined amino acid PET-based response assessment criteria (PET RANO BM 1.0) for their ability to predict longer progression-free survival (PFS) in patients with brain metastases treated with contemporary CNS-active systemic agents.

**Patients and Methods**

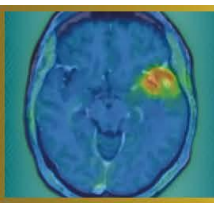
From 2015-2025, 242 patients with brain metastases who underwent 556 O-(2-[<sup>18</sup>F]-fluoroethyl)-L-tyrosine (FET) PET scans (median number, 4; range, 1-8) during the course of disease were retrospectively identified. Search criteria for data evaluation were (i) patients with brain metastases secondary to melanoma, non-small cell lung cancer, or breast cancer, (ii) treatment involving targeted therapies or immune checkpoint inhibitors (with or without concurrent radiosurgery), and (iii) presence of both a baseline FET PET scan before treatment initiation and at follow-up. Tumor-to-brain ratios (TBR<sub>mean</sub>, TBR<sub>max</sub>) and metabolic tumor volumes were obtained fully automated according to the current guidelines. Univariate survival estimates were performed to evaluate the value of the PET RANO BM 1.0 criteria to predict a significantly longer PFS.

**Results**

Twenty-three patients with 50 brain metastases secondary to melanoma (n=14 patients), non-small cell lung cancer (n=7 patients), or breast cancer (n=2 patients) fulfilled the search criteria. The median time between the two FET PET scans was 4.0 months (range, 2.0-24.0 months). According to the PET RANO BM 1.0 criteria applied to each brain metastasis, patients fulfilling the criterion PET-based Stable Disease (n=0), Partial Response (n=8), or Complete Response (n=1) had a significantly longer PFS than patients with PET-based Progressive Disease (n=14) (18.0 vs. 6.0 months; P=0.036).

**Conclusion**

Our data suggest that the PET RANO BM 1.0 criteria are helpful to predict significantly longer PFS in patients with brain metastases undergoing contemporary CNS-active systemic agents. Prospective validation of these amino acid PET response criteria is warranted.



**Abstract Number:** 37

**Abstract Title:** Evaluation of glioblastoma-brain assembloids as an advanced in vitro model for preclinical targeted radionuclide testing

**Authors:**

**Sarah Waelkens**<sup>1,2</sup>, Charlotte Segers<sup>1</sup>, Veronique Bogaerts<sup>1</sup>, Tomas Opsomer<sup>1</sup>, Frederik De Smet<sup>2</sup>, Roel Quintens<sup>1</sup>

<sup>1</sup>Radiobiology Unit, Institute for Nuclear Medical Applications, Belgian Nuclear Research Centre, SCK CEN, Mol, Belgium, <sup>2</sup>Laboratory of Precision Cancer Medicine, Translational Cell and Tissue Research Unit, Department of Imaging and Pathology, KU Leuven, Leuven, Belgium

### Background

In vitro models constitute the first step in preclinical targeted radionuclide therapy (TRT) evaluation, but traditionally rely on 2D-cultures that poorly capture tumor heterogeneity, spatial target expression, and tumor-microenvironment interactions, critical factors in glioblastoma (GBM). This limits prediction of radioligand uptake and TRT-specific effects, such as crossfire- and bystander-signaling. While advanced 3D co-culture systems better preserve architectural and microenvironmental features, they remain underexplored for TRT research. GBM-brain assembloids, combining patient-derived tumor spheroids with stem cell-derived cortical organoids, represent a promising model.

### Material and Methods

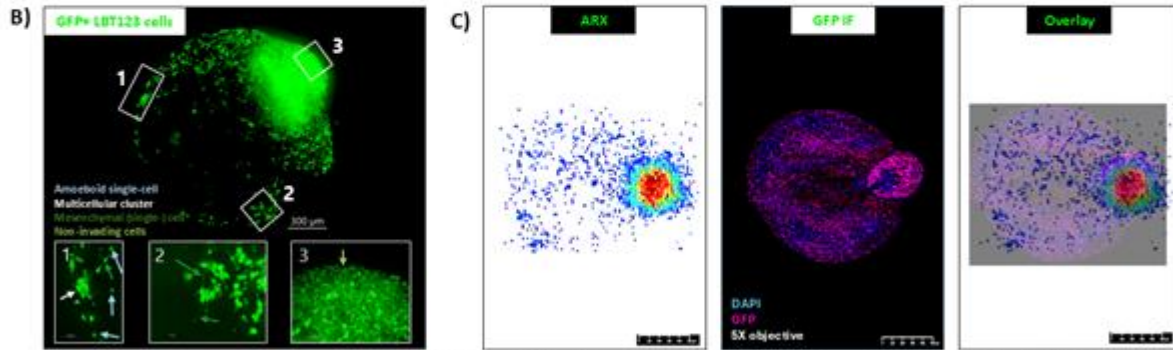
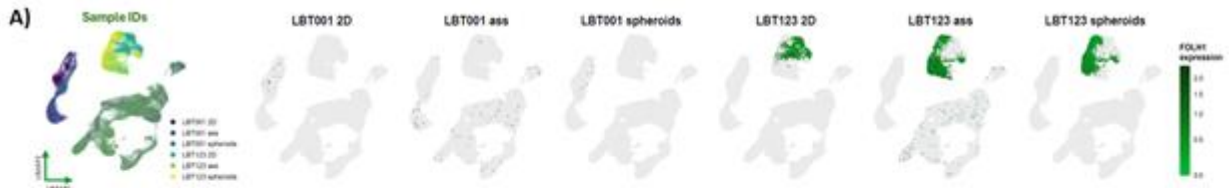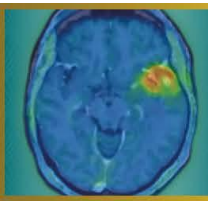
A panel of patient-derived GBM cell lines (PDGCLs) was screened for clinically relevant TRT targets, identifying prostate-specific membrane antigen (PSMA) as highly expressed in a subset of tumors. GBM-brain assembloids from two PDGCLs were generated by co-culturing GBM spheroids with cortical brain organoids. PSMA expression was evaluated using western blotting, immunofluorescence (IF), and single-cell RNA sequencing (scRNAseq) on spheroids and assembloids. Spatial distribution and specific binding of [<sup>177</sup>Lu]Lu-PSMA-I&T (10nM, 40MBq/nmol) were assessed by in vitro autoradiography on cryosectioned spheroids and assembloids in the presence or absence of a structurally unrelated blocking agent 2-PMPA, and later combined with IF.

### Results


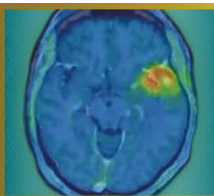
Two PDGCLs were selected: PSMA-negative LBT001 and PSMA-positive LBT123. Both successfully formed assembloids with invading GFP-positive tumor cells. scRNAseq demonstrated PSMA expression exclusively in tumor cells of LBT123-derived assembloids, with no expression in healthy organoid cells nor LBT001 cells. LBT123-specific target expression was further corroborated by western blotting and IF. In vitro autoradiography combined with PSMA/GFP IF confirmed highly selective [<sup>177</sup>Lu]Lu-PSMA-I&T binding in PSMA/GFP-positive tumor regions, with no binding in surrounding healthy organoid cells.

### Conclusion

GBM-brain assembloids demonstrate spatially resolved, tumor-specific TRT binding within a physiologically relevant microenvironment. This finding provides a foundation for further studies, and we propose assembloids represent a promising model for evaluating radioligand affinity and specificity, therapeutic efficacy, and radiobiological effects, including potential bystander- and crossfire-interactions.



**A)** Single-cell RNA sequencing analysis of two patient-derived glioblastoma (GBM) cell lines cultured under 2D, spheroid, and assembloid conditions. Uniform Manifold Approximation and Projection (UMAP) of batch-corrected single-cell transcriptomes across all culture systems, colored by cell line and model (left) and FOLH2 expression levels per model (remaining).  
**B)** GFP-positive LBT123 glioblastoma cells exhibit distinct invasion patterns within cortical brain organoids. Representative confocal image of a cleared assembloid. Scale bar = 300 µm.  
**C)** Immunofluorescence staining for GFP on LBT123 glioblastoma-brain assembloid cryosections [blue = DAPI, purple = GFP] compared with autoradiography (ARX) of  $[^{127}\text{Lu}]\text{u-PSMA-i\&T}$  (10 nM, 40 MBq/nmol) on an adjacent section, with merged overlay. Cryosections thickness = 12 µm.



**Abstract Number:** 38

**Abstract Title:** FET-PET in Glioblastoma (FIG) Study (TROG 18.06): Towards FET-PET-Guided Radiotherapy Target Volume Delineation in Glioblastoma

**Authors:**

**Eng-Siew Koh**<sup>1</sup>, Professor Roslyn J. Francis<sup>2,3</sup>, Professor Sze Ting Lee<sup>4,5</sup>, Associate Professor Eddie Lau<sup>5,6</sup>, Assoc. Professor Elizabeth Thomas<sup>2</sup>, Professor Hui K. Gan<sup>4,7</sup>, Angela Whitehead<sup>8</sup>, Alisha Moore<sup>8</sup>, Rachael Dykj<sup>8</sup>, Olivia Cook<sup>8</sup>, Alana Rossi<sup>8</sup>, Dr Nathaniel Barry<sup>9</sup>, Professor Martin Ebert<sup>9,10</sup>, Associate Professor Sweet Ping Ng<sup>11</sup>, Associate Professor Mark B. Pinkham<sup>12,13</sup>, Michael Back<sup>14</sup>, Dr Nicholas Bucknell<sup>10</sup>, Professor Dale L. Bailey<sup>15,16</sup>, Assoc. Professor Bradford A. Moffat<sup>17</sup>, Assoc. Professor Greg Fitt<sup>6,18</sup>, Dr Isidoro Ruisi Ruisi<sup>1</sup>, Prof Andrew Scott<sup>4,5</sup>

<sup>1</sup>Liverpool Hospital, University Of New South Wales, Sydney, Australia, <sup>2</sup>Department of Nuclear Medicine, Sir Charles Gairdner Hospital, Nedlands, Perth, Australia, <sup>3</sup>Medical School, The University of Western Australia, Crawley, Australia, <sup>4</sup>Tumour Targeting Program, Olivia Newton-John Cancer Research Institute, Heidelberg, Australia, <sup>5</sup>Department of Molecular Imaging and Therapy, Austin Health, Heidelberg, Australia, <sup>6</sup>Department of Radiology, Austin Health, Heidelberg, Australia, <sup>7</sup>Austin Health, Department of Medical Oncology, Melbourne, Australia, <sup>8</sup>TROG Cancer Research, Newcastle, Australia, <sup>9</sup>School of Physics, Mathematics and Computing, University of Western Australia, Crawley, Australia, <sup>10</sup>Department of Radiation Oncology, Sir Charles Gairdner Hospital, Perth, Nedlands, Australia, <sup>11</sup>Austin Health, Department of Radiation Oncology, Heidelberg, Australia, <sup>12</sup>Department of Radiation Oncology, Princess Alexandra Hospital, Brisbane, Australia, <sup>13</sup>Icon Cancer Centre North Lakes and Greenslopes Private Hospital, Brisbane, Australia, <sup>14</sup>Department of Radiation Oncology, Royal North Shore Hospital, St Leonards, Sydney, Australia, <sup>15</sup>Faculty of Medicine & Health, University of Sydney, Camperdown, Australia, <sup>16</sup>Department of Nuclear Medicine, Royal North Shore Hospital, Sydney, Australia, <sup>17</sup>Melbourne Brain Centre Imaging Unit, Department of Radiology, University of Melbourne, Melbourne, Australia, <sup>18</sup>Department of Radiology, University of Melbourne, Melbourne, Australia

**Background**

The FET-PET in Glioblastoma (FIG) study (TROG 18.06) is a prospective, multi-site phase 2 trial evaluating the impact of O-(2-[<sup>18</sup>F]-fluoroethyl)-L-tyrosine positron emission tomography (FET-PET) on radiation target (RT) volume definition and treatment response assessment (pseudo versus true progression) in glioblastoma.

**Materials and Methods**

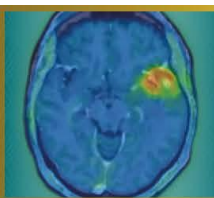
Eligible patients with Glioblastoma from 11 credentialled Australian centres are enrolled into Group 1 (FET-PET1 at pre-chemoradiation) or Group 2 (FET-PET2 post-chemoradiation). The Timepoint 1 workflow involves: (1) standard adjuvant radiation planning with delineation of RT target volumes based on MRI, and (2) generation of hybrid volumes incorporating centrally reviewed nuclear medicine physician (NMP)-derived biological tumour volumes (BTVs) from FET-PET1, using MiM software (v7.0). All submitted NMP BTVs and radiation oncology (RO) contours undergo protocolised central review, with resubmission required for non-compliance.

**Results**

As at February 2026, 284 participants have enrolled (Group 1: 161; Group 2: 123), with n=139 evaluable Glioblastoma FET-PET1 cases and n=5 Grade 4 IDHmutant cases acquired. Pre-trial credentialling identified interobserver BTV variation in 25/72 (34.7%) submissions including 12 major deviations. Of the 144 prospective FET-PET1 BTVs, 20 (13.9%) required resubmission, most due to static GTV over-contouring (n=12), MiM workflow errors (n=3), misinterpretation of static FET signal (n=3) and dynamic changes in volume of interest (n=1). To date, full central RO review of clinical and hybrid RT volumes has demonstrated a 9/54 (16%) resubmission rate, with 10/54 (19%) deemed a conditional pass and 35/54 (65%) cases passed outright. A dedicated MiM trial workflow will support radiation dosimetric and volumetric comparison of MRI-only versus FET-PET-informed RT target volumes in the evaluable cohort.

**Conclusions**

Robust credentialling and centralised quality assurance programmes should be embedded within multi-centre molecular imaging-integrated neuro-oncology trials. The FIG trial remains the largest prospective study of its kind and will inform integration of FET-PET-guided approaches to adjuvant radiation planning in Glioblastoma.



**Abstract Number:** 39

**Abstract Title:** Diagnostic accuracy of long-axial-field-of-view [18F]FET PET/CT in high-grade glioma - semi-quantitative cutoff values for tumour detection

**Authors:**

**Michelle Amon**<sup>1</sup>, Dr. med. Alexandra Lazar<sup>2</sup>, Dr. med Piotr Radojewski<sup>3</sup>, Prof. Dr. med. Axel Rominger<sup>1</sup>, Dr. Hasan Sari<sup>4</sup>, Dr. med. Clemens Mingels<sup>1</sup>

<sup>1</sup>Department of Nuclear Medicine, Inselspital, Bern University Hospital, Bern, Switzerland, <sup>2</sup>Vita-Salute San Raffaele University, Milan, Italy, <sup>3</sup>University Institute of Diagnostic and Interventional Neuroradiology, Inselspital Bern University Hospital and University of Bern, Bern, Switzerland, <sup>4</sup>Siemens Healthineers International AG, Zurich, Switzerland

### Background

Long-axial field-of-view (LAFOV) PET/CT has shown improved image quality due to its higher sensitivity. In this work, we aimed to explore potential new cutoff values for LAFOV [18F]FET PET/CT in high-grade glioma for early differentiation between tumour recurrence and radiation necrosis.

### Material and Methods

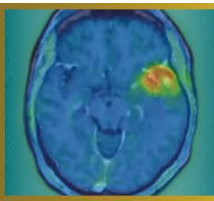
In this ongoing retrospective evaluation, 28 patients with high-grade glioma who underwent LAFOV [18F]FET PET/CT (Biograph Vision Quadra, Siemens Healthineers) for the assessment of tumour recurrence after surgery and radiotherapy. Dynamic scans were acquired for 40 minutes upon injection of  $191 \pm 10$  MBq [18F]FET. Last 20 minutes of data were reconstructed into static PET images. Lesions were manually delineated; parameters of interest were the maximum standardized uptake value (SUV<sub>max</sub>), tumour-to-background ratios (TBR) from static images and visual analysis of the time-activity curves (TAC). Background uptake was assessed at the semioval centre of the contralateral hemisphere. For diagnostic accuracy a composite reference standard (histopathology, imaging and follow-up up to 24 months) was used. Receiver operating characteristic (ROC) curve analysis was performed to determine optimal TBR cutoff values.

### Results

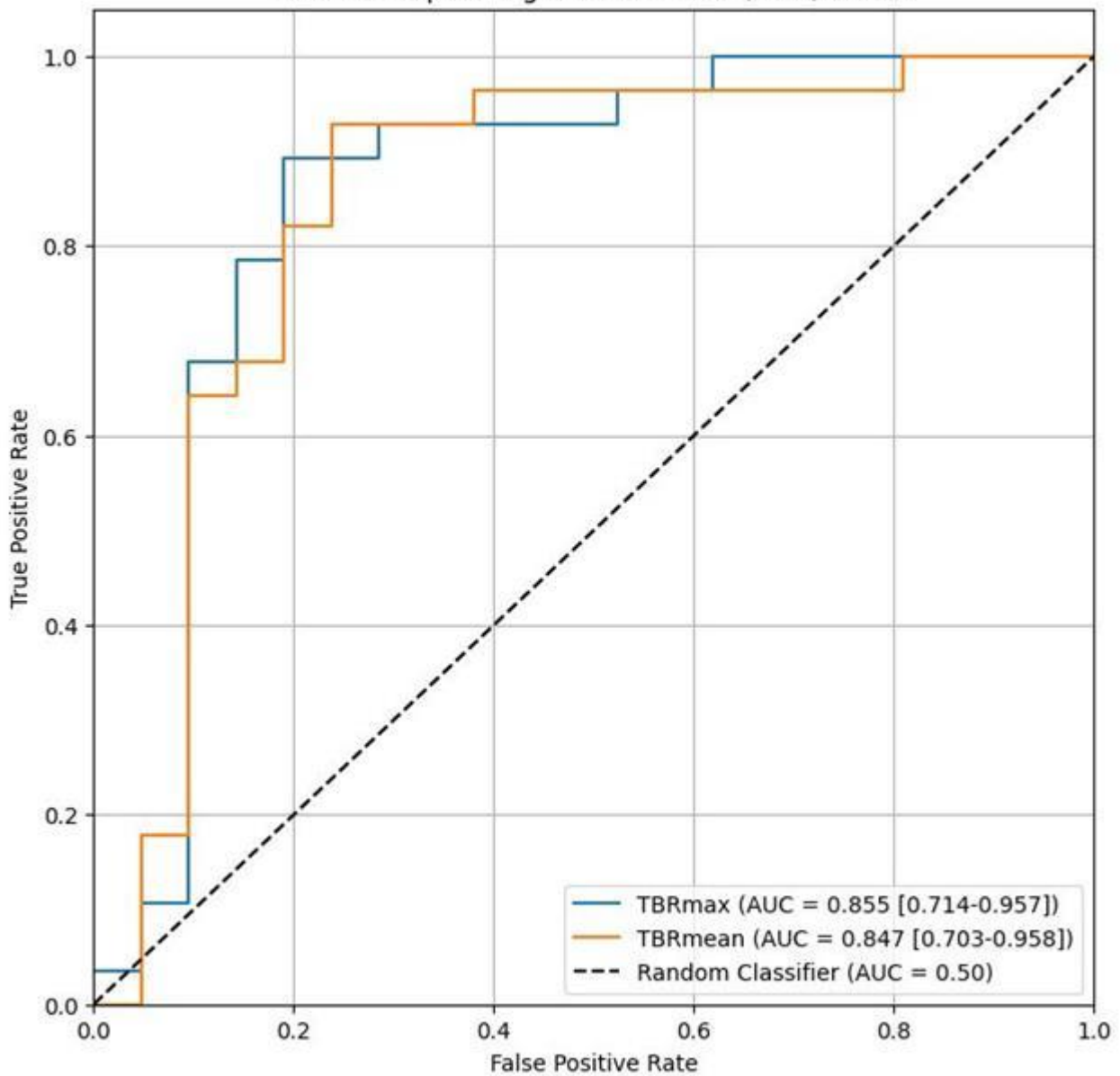
Tumour recurrence was detected in 28/49 lesions. TBR<sub>max</sub> and TBR<sub>mean</sub> were significantly different between tumour recurrence and treatment-related changes ( $p < 0.001$ ), with values of 1.60 (IQR 0.98) and 1.34 (IQR 0.90) treatment-related changes and, respectively, 3.47 (IQR 0.96) and 2.60 (IQR 0.87) for recurrence. ROC analysis identified an optimal TBR<sub>max</sub> cutoff of 2.53 (sensitivity 89%, specificity 81%, AUC 0.855) and TBR<sub>mean</sub> cutoff of 1.90 (sensitivity 93%, specificity 77%, AUC 0.847) for differentiating recurrent glioma from radio necrosis. TAC analysis showed moderate sensitivity (57%) but high specificity (81%), and a significant association (OR 5.67, 95% CI 1.51-21.25; Fisher's  $p = 0.009$ ) with the outcome.

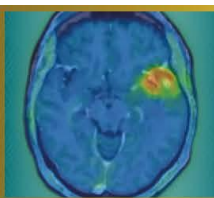
### Discussions and conclusion

In this preliminary analysis, LAFOV [18F]FET PET/CT demonstrated high diagnostic accuracy for differentiating tumour recurrence from radionecrosis. The identified cutoff values were comparable to currently established TBR thresholds used in clinical practice, indicating consistent quantitative performance with LAFOV imaging.



Receiver Operating Characteristic (ROC) Curve





**Abstract Number:** 40

**Abstract Title:** Follow-up on the preclinical evaluation of [18F]AG-120, a radiotracer for the detection of the mutant isocitrate dehydrogenase 1 in a rat model of glioma

**Authors:**

Barbara Wenzel<sup>1</sup>, Lisa Wiesner<sup>1</sup>, Winnie Deuther-Conrad<sup>1</sup>, Sebastian Greiser<sup>2</sup>, Stadjana Dukić-Stefanović<sup>1</sup>, Rodrigo Teodoro<sup>1</sup>, Andreas Maurer<sup>1</sup>, Klaus Kopka<sup>1,3</sup>, Tareq A. Juratli<sup>4,5</sup>, Thu Hang Lai<sup>6</sup>, **Magali Toussaint**<sup>1</sup>

<sup>1</sup>Helmholtz-Zentrum Dresden-Rossendorf, Institute of Radiopharmaceutical Cancer Research, Department of Experimental Neurooncological Radiopharmacy, Leipzig, Germany, <sup>2</sup>Fraunhofer Institute for Cell Therapy and Immunology, Leipzig, Germany, <sup>3</sup>Technische Universität Dresden, School of Science, Faculty of Chemistry and Food Chemistry, Dresden, Germany, <sup>4</sup>National Center for Tumor Diseases (NCT) Dresden, University Hospital Carl Gustav Carus, Dresden, Germany, <sup>5</sup>Department of Neurosurgery, Faculty of Medicine and University Hospital Carl Gustav Carus, Technische Universität Dresden, Dresden, Germany, <sup>6</sup>ROTOP Pharmaka GmbH, Dresden, Germany

**Background**

In this interim analysis, we propose an update on our previous published work aiming at developing a radioligand to noninvasively and quantitatively detect IDH1R132H by PET. We previously demonstrated in vitro the selective uptake of [18F]AG-120 with no saturation up to two-hours. The one-hour PET scans performed in U251-IDH1 or U251-IDH1R132H glioma models, demonstrated a slightly higher retention in the latter (Tumor-to-Background Ratio TBR[30-60min]: ~1.1 vs. ~1.6).

**Methods**

Here, we further investigate the in vivo kinetic of [18F]AG-120, by performing two-hours PET scans and inspecting a potential influence of vascularization discrepancies between the two models on the radioligand uptake. The dynamic PET scans (NanoScan® PET/MR, Mediso) were performed in nude rats bearing orthotopic U251-IDH1 (n=8) or U251-IDH1R132H (n=8) gliomas. The tumor perfusion was evaluated by dynamic contrast-enhanced MRI (Pharmascan 7T, Bruker) and immunofluorescent CD31 staining.

**Results**

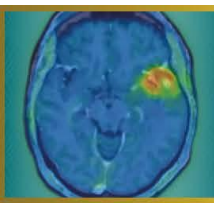
On the day of PET, the U251-IDH1 and U251-IDH1R132H tumors presented a volume of 20±7 mm<sup>3</sup> and 15±5 mm<sup>3</sup>, respectively. Both tumor models exhibited similar TBR at the later time points (TBR[90-120min]: 1.1±0.2 vs. 1.3±0.3). The perfusion curves demonstrated similar features as well, with a mean-transit-time of 7.4±3.1 min vs. 6.4±2.3 min and an elimination constant of 0.16±0.06 min<sup>-1</sup> vs. 0.17±0.05 min<sup>-1</sup> respectively. Finally, the CD31 staining highlighted a lower vascularization pattern in both tumor models compared to the brain-adjacent-tumor tissue.

**Conclusions**

To conclude, the two tumor models present similar perfusion pattern, excluding perfusion as confounding factor in radioligand accumulation. Although the in vitro kinetics of [18F]AG-120 suggested that longer PET acquisition could lead to a clearer distinction between mutant- and wildtype-IDH1 tumors, this result was not reproducible in the more complex in vivo environment.

**Acknowledgements:** We thank Dr. Kessler and Prof. Vordermark, Department of Radiotherapy, Martin Luther University Halle-Wittenberg, for providing the cells.

**Disclosure Information:** This work was funded by the the European-Regional-Development-Fund and the Sächsische-Aufbaubank.



**Abstract Number:** 42

**Abstract Title:** Prognostic relevance of FET PET in patients with newly diagnosed glioblastoma

**Authors:**

**Jan-Michael Werner**<sup>1</sup>, Katharina J. Müller<sup>2</sup>, Maximilian J. Mair<sup>3</sup>, PD Dr. med. Michael Mütter<sup>4</sup>, Wolfgang Roll<sup>5</sup>, Jana-Marie Peplinski<sup>1</sup>, Manuel Kraft<sup>1</sup>, Julia Hilgers<sup>6</sup>, Keith G. Ciantar<sup>6</sup>, Christoph Kabbasch<sup>7</sup>, Anna S. Berghoff<sup>3</sup>, Gereon R. Fink<sup>1,6</sup>, Roland Goldbrunner<sup>8</sup>, Nadim J. Shah<sup>6</sup>, Felix M. Mottaghy<sup>9</sup>, Karl-Josef Langen<sup>6,9</sup>, Philipp Lohmann<sup>6,9</sup>, Matthias Preusser<sup>3</sup>, Norbert Galldiks<sup>1,6</sup>, Nathalie L. Albert<sup>10</sup>

<sup>1</sup>Dept. of Neurology, Faculty of Medicine and University Hospital Cologne, Cologne, Germany, <sup>2</sup>Dept. of Neurology, LMU University Hospital, LMU Munich, Munich, Germany, <sup>3</sup>Division of Oncology, Department of Medicine I, Medical University of Vienna, Vienna, Austria, <sup>4</sup>Department of Neurosurgery, University Hospital Münster, Münster, Germany, <sup>5</sup>Department of Nuclear Medicine, University Hospital Münster, Münster, Germany, <sup>6</sup>Inst. of Neuroscience and Medicine (INM-3, INM-4), Research Center Juelich, Juelich, Germany, <sup>7</sup>Inst. of Radiology, Division of Neuroradiology, Faculty of Medicine and University Hospital Cologne, Germany, <sup>8</sup>Dept. of Neurosurgery, Faculty of Medicine and University Hospital Cologne, Cologne, Germany, <sup>9</sup>Dept. of Nuclear Medicine, University Hospital RWTH Aachen, Aachen, Germany, <sup>10</sup>Dept. of Nuclear Medicine, LMU University Hospital, LMU Munich, Munich, Germany

**Background**

The present study investigates the prognostic relevance of O-(2-[<sup>18</sup>F]fluoroethyl)-L-tyrosine (FET) PET parameters in newly diagnosed glioblastoma.

**Methods**


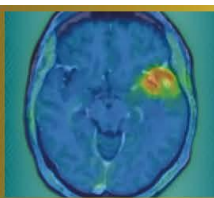
In this retrospective multicenter study, 125 patients with newly diagnosed glioblastoma according to the WHO 2021 classification were included. Patients received FET PET imaging before surgery or after biopsy prior to first-line treatment with radiotherapy alone (n=11), concomitant and adjuvant temozolomide (n=86), or temozolomide plus lomustine (n=28). FET PET-positive tumor volumes were segmented semi-automatically or using the nnUNet-based JuST\_BrainPET based on a tumor-to-brain ratio (TBR) of  $\geq 1.6$ . All segmentations were visually checked. Quantitative PET parameters, i.e., maximum and mean TBR values, and PET-positive volumes (PET-Vol), were correlated with overall survival (OS) using Cox regression models. Additional clinical parameters included age (range, 21-86 years), MGMT promoter methylation status (hypermethylated in 60% of patients), extent of resection, and first-line treatment regimen. The Cutoff Finder web tool (maximally selected log-rank/Cox split) was used to derive an outcome-optimized threshold from continuous variables for OS stratification.

**Results**

In univariate Cox regression, PET-Vol (hazard ratio [HR], 1.02 per mL; 95% CI, 1.01-1.03;  $p < 0.001$ ), radiotherapy alone (HR, 6.44; 95% CI, 2.00-17.73;  $p = 0.003$ ), and unmethylated MGMT promoter (HR, 2.11; 95% CI, 1.26-3.49;  $p = 0.005$ ) were significantly associated with shorter OS. In multivariable Cox regression, PET-Vol emerged as the strongest independent prognostic parameter, showing the largest contribution to model fit (HR=1.03 per mL, 95% CI, 1.01-1.04;  $p < 0.001$ ), outperforming MGMT promoter methylation status ( $p = 0.004$ ) and applied treatment ( $p = 0.014$ ). At exploratory analysis, the optimal cutoff for risk stratification using PET-Vol was 39 mL (HR, 4.00; 95% CI, 2.17-7.37). PET-Vol  $> 39$  mL was associated with a significantly shorter OS (8 vs. 27 months;  $p < 0.001$ ).

**Conclusion**

These data support the integration of the FET PET tumor volume as a prognostic biomarker in glioblastoma risk stratification. Further studies with larger datasets are needed to substantiate our findings.



**Abstract Number:** 44

**Abstract Title:** Virtual postoperative 18F-FET-PET imaging as a surrogate imaging modality in recurrent glioblastoma assessment

**Authors:**

**Jocelyn Castille**<sup>1</sup>, Dr. Wietse Geens<sup>1</sup>, Dr. Iris Dirven<sup>2</sup>, Dr. Cleo Bertels<sup>2</sup>, Prof. dr. Michaël Bruneau<sup>1</sup>, Anass Hamdi<sup>3</sup>, Prof. dr. ir. Jef Vandemeulebroecke<sup>4</sup>, Prof. dr. Bart Neyns<sup>2</sup>, Ir. Laurens Raes<sup>3</sup>, Prof. dr. Hendrik Everaert<sup>3</sup>, Prof. dr. Johnny Duerinck<sup>1</sup>

<sup>1</sup>University Hospital Brussels, department of neurosurgery, Brussels, Belgium, <sup>2</sup>University Hospital Brussels, department of oncology, Brussels, Belgium, <sup>3</sup>University Hospital Brussels, department of nuclear medicine, Belgium, <sup>4</sup>Free University of Brussels, department of electronics and informatics, Belgium

**Background**

The prognostic role of O-(2-[18F]fluoroethyl)-L-tyrosine PET-derived (18F-FET PET) imaging parameters in recurrent glioblastoma (rGBM) are increasingly being recognized, but often only preoperative FET-PET is available. We investigated whether virtual postoperative FET-PET parameters predict overall survival (OS) after re-operation and whether the virtual FET-PET signal predicts recurrence location.

**Materials and Methods**

We retrospectively analyzed 61 patients with rGBM who underwent re-operation followed by intracerebral immunotherapy within a single-center clinical trial. Pre- and postoperative-MRI and preoperative 18F-FET-PET data were available for 49 patients. Virtual postoperative FET MTV was generated by co-registering preoperative FET-PET to postoperative MRI, subtracting the resection cavity and non-tumoral postoperative changes, and quantifying the remaining metabolic tumor volume and static parameters. Univariate and multivariate Cox proportional hazards regression analyses were performed to assess associations with OS from the time of recurrence. Subsequently, a qualitative analysis examined the relationship between the virtual FET-PET signal and rGBM recurrence localization.

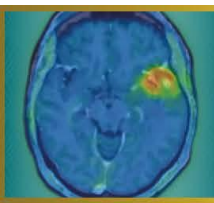
**Results**

On univariate analysis, virtual postoperative FET MTV was significantly associated with OS (HR 1.03, p=0.017), whereas residual CE volume was not (HR 1.07, p=0.090). In multivariate analysis adjusted for KPS and corticosteroid use, FET MTV showed a trend toward independent prognostic significance (HR 1.025, p=0.053), while residual CE volume did not (HR 1.041, p=0.385). The FET MTV-based model demonstrated superior fit compared with the CE volume-based model (AIC 289.9 vs 292.5).

The virtual FET-PET signal accurately predicted glioblastoma recurrence localization in exactly 80% of cases.

**Conclusion**

Virtual postoperative residual 18F-FET-PET metabolic tumor volume appears to be a stronger prognosticator of OS than conventional MRI-based residual CE volume in rGBM patients that received intracerebral immunotherapy. Spatial localization of residual FET-activity is often indicative of location of later recurrence. Validation in larger cohorts and comparison with actual postoperative FET-PET is warranted.



**Abstract Number:** 45

**Abstract Title:** Early-dominant TSR kinetics on dynamic F-DOPA PET: a radiotherapy-relevant biomarker for glioma recurrence

**Authors:**

**Gabor Sipka**<sup>1</sup>, Kristof Apro<sup>1</sup>, Zsofia Miko<sup>1</sup>, Bernadett Bardoczi<sup>1</sup>, Gyöngyi Kelemen<sup>2</sup>, Katalin Hideghety<sup>2</sup>, Zsuzsanna Besenyi<sup>1</sup>

<sup>1</sup>University Of Szeged, Department of Nuclear Medicine, Szeged, Hungary, <sup>2</sup>University of Szeged, Department of Oncotherapy, Szeged, Hungary

**Background**

Dynamic 18F-FDOPA PET provides temporal information beyond static uptake metrics; however, clinically robust kinetic biomarkers applicable to radiotherapy planning remain insufficiently defined. We evaluated tumor-to-striatum ratio (TSR)-based dynamic parameters focusing on early kinetic behaviour, ROI-independent stability, and potential protocol simplification.

**Material and Methods**

In this retrospective study, dynamic FDOPA PET scans of 42 histologically confirmed glioma patients (57 PET-positive lesions) were analyzed in a lesion-based exploratory cohort. Tumor lesion delineation was performed based on MRI guidance. Recurrence versus treatment-related change was determined through multidisciplinary validation with  $\geq 3$ -year follow-up including MRI, histopathology when available, and clinical course. TSR time-activity curves were derived from 25-minute acquisitions. Early (5–10 min) and late (20–25 min) phase averages were calculated across SUVmax, SUVmean, and SUVpeak. Derived parameters included Early-to-Late Ratio (ELR), Washout Index (WI), Early Rise Index, and linear TSR slope. ROI robustness was assessed using coefficient-of-variation analysis.

**Results**


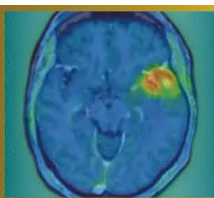
Recurrence lesions predominantly demonstrated early-dominant TSR kinetics, observed in 37/47 lesions (~79%), characterized by rapid tumor uptake preceding progressive striatal activity. ELR showed substantially higher ROI-independent stability than WI (median CV: 0.0468 vs. 0.263). Median ELR values were consistent across SUVmax (1.23), SUVmean (1.19), and SUVpeak (1.24), whereas WI demonstrated greater dispersion (35.6%, 23.2%, and 29.7%, respectively). Linear TSR slope and Early Rise Index reflected rapid uptake dynamics but were more sensitive to peak timing. TSR-derived parameters were reproducible from early and late phase averages.

**Discussion**

These findings indicate a reproducible early-dominant recurrence phenotype and suggest that clinically relevant kinetic information may be captured using simplified dual-time-window imaging.

**Conclusion**

Dynamic TSR analysis identifies ELR as a stable, ROI-robust FDOPA biomarker potentially highlighting biologically active recurrence regions relevant for radiotherapy boost delineation. Early-phase imaging combined with dual-time-point acquisition may support biologically guided radiotherapy workflows. Prospective validation is warranted.



**Abstract Number:** 46

**Abstract Title:** Multi-pinhole SPECT/CT for meningioma imaging: a novel diagnostic approach

**Authors:**

**Kristóf Apró**<sup>1</sup>, László Pávics<sup>1</sup>, Melinda Szolikova<sup>1,2</sup>, Ágnes Dobi<sup>3</sup>, Katalin Hideghéty<sup>3</sup>, Márton Balázsfői<sup>4</sup>, Pál Barzó<sup>4</sup>, Gábor Sipka<sup>1</sup>, Zsuzsanna Besenyi<sup>1</sup>

<sup>1</sup>Department of Nuclear Medicine and Theranostics, Albert Szent-Györgyi Medical School, University of Szeged, Hungary, Szeged, Hungary, <sup>2</sup>Mediso Medical Imaging Systems Ltd, Budapest, Hungary, Budapest, Hungary, <sup>3</sup>Department of Oncotherapy, Albert Szent-Györgyi Medical School, University of Szeged, Hungary, Szeged, Hungary, <sup>4</sup>Department of Neurosurgery, Albert Szent-Györgyi Medical School, University of Szeged, Hungary, Szeged, Hungary

**Background**

Meningiomas are the most common primary brain tumors in adults and are associated with a substantial risk of recurrence despite typically slow growth. Overexpression of somatostatin receptor subtype 2 (SSTR2) enables targeted imaging using somatostatin analogues. This prospective study evaluates the diagnostic performance of SSTR SPECT/CT acquired with parallel-hole (PH) and multi-pinhole (MPH) collimators, using contrast-enhanced MRI as the reference standard in patients with clinically progressive, histologically confirmed World Health Organization (WHO) Grade I–III meningiomas.

**Material and Methods**

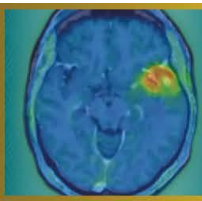
Nineteen patients underwent SSTR-targeted SPECT/CT imaging using [<sup>99m</sup>Tc]Tc-EDDA-HYNIC-TOC (AnyScan TRIO SPECT/CT/PET imaging system, Mediso). Sequential acquisitions were performed with a multi-pinhole collimator followed by a parallel-hole collimator. SPECT/CT datasets were co-registered with contrast-enhanced T1-weighted MRI for tumor delineation. Lesion number, spatial extent, and osseous involvement were compared across modalities. Semi-quantitative analyses were conducted including SUVmax, SUVmean, and tumor-to-background ratio (TBR) in InterView FUSION software (Mediso).

**Results**

Multi-pinhole SPECT/CT detected 36 lesions, compared with 33 lesions on MRI (91.7%) and 26 lesions on parallel-hole SPECT/CT (72%). All lesions were confirmed during follow-up by MRI or histology. MPH-SPECT/CT identified additional multinodular disease and detected bone infiltration in ten lesions, compared with five identified by MRI. Semi-quantitative analysis demonstrated significantly higher tracer uptake and TBR values in MPH acquisitions than in parallel-hole studies (SUVmean,  $p = 0.001$ ; SUVmax,  $p = 0.001$ ; paired t-test).

**Conclusion**

Multi-pinhole SSTR SPECT/CT shows excellent diagnostic performance for meningioma detection and improves assessment of lesion multiplicity and osseous involvement compared with conventional approaches. Advanced SPECT methodology may help narrow the diagnostic gap between conventional SPECT and PET imaging and represents a practical alternative in selected clinical settings.



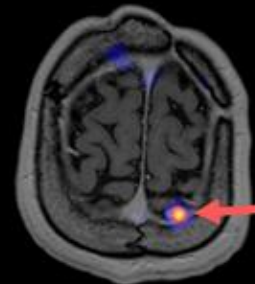
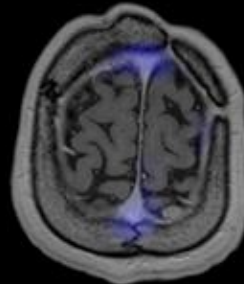
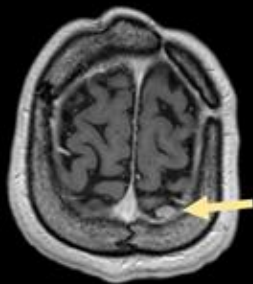
MRI

LEHR-SPECT

MPH-SPECT

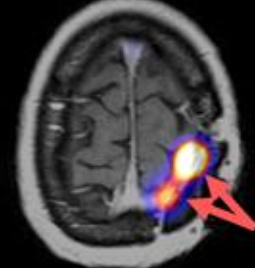
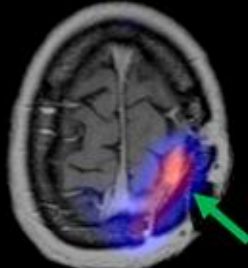
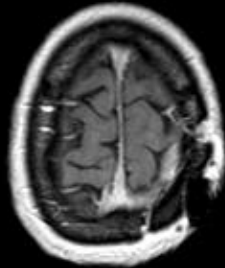
A)

MRI +  
LEHR -  
MPH +



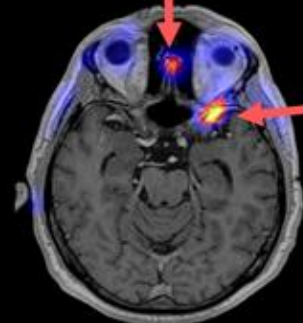
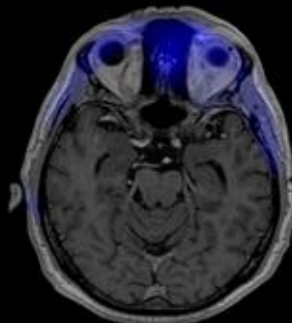
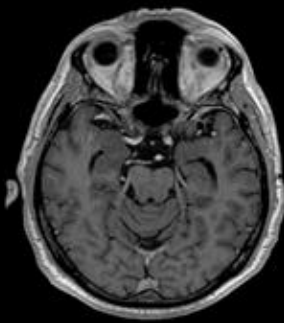
B)

MRI -  
LEHR +  
MPH +



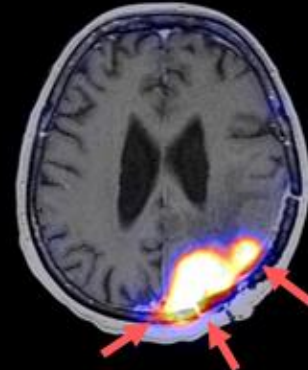
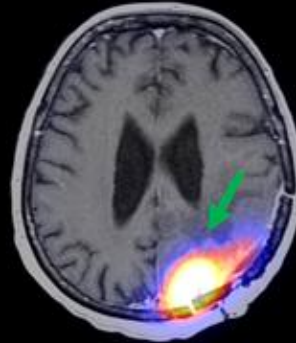
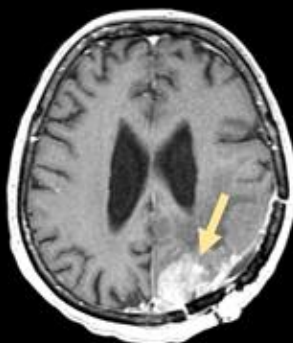
C)

MRI -  
LEHR -  
MPH +



D)

MRI +  
LEHR +  
MPH ++  
*\*(additional  
informations)*



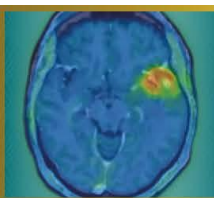
From left to right: contrast-enhanced T1-weighted MRI ; MRI-SPECT fusion with LEHR (low-energy,high-resolution) collimator, MRI-SPECT fusion with MPH (multi-pinhole) collimator.

Radiopharmaceutical:  $^{99m}\text{Tc}$ -EDDA/HYNIC-TOC (Tektrotyd®)

'+' indicates detected meningioma, '-' indicates no detection.

Yellow arrow indicates meningioma detected by MRI; green arrow by LEHR-SPECT; red arrow by MPH-SPECT.

\* midline crossing, bone infiltration, other meningeal involvement



**Abstract Number:** 47

**Abstract Title:** ReSPECT-LM: Pharmacokinetic and Pharmacodynamic assessment of Reyobiq in Leptomeningeal Metastases

**Authors:**

**Andrew Brenner<sup>1</sup>**

<sup>1</sup>University of Texas Health San Antonio, San Antonio, United States, <sup>2</sup>Mays Cancer Center at UT Health San Antonio, SAN ANTONIO, United States

### Background

Rhenium obisbameda (186RNL, REYOBIQ) is 186Re encapsulated in liposomal nanoparticles. We reported excellent safety and promising activity for 186RNL in leptomeningeal metastases (LM). The recommended phase-2 single dose was 44mCi with an MTD of 66mCi. We now report the pharmacokinetic and pharmacodynamic results.

### Methods


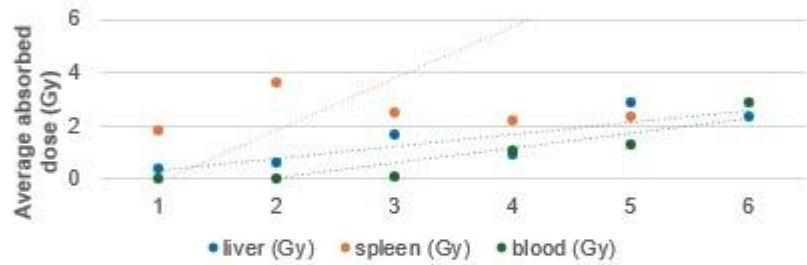
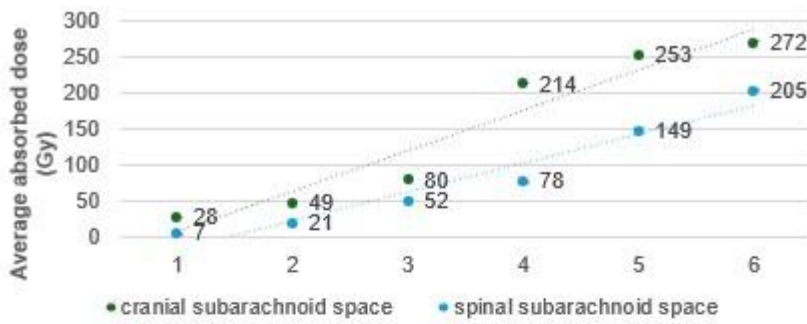
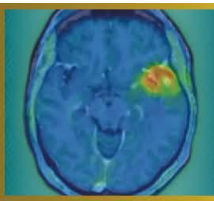
Planar imaging was performed postdose, and 24-168hrs. Computations of target and normal organ doses were performed using OLINDA/EXM. CSF was collected at baseline, 8, 24, 48hrs; days 14 and 28. Cells underwent immediate processing and batch RNA-sequencing. To further characterize immunologic changes, an ID8agg/C57BL6 model was used.


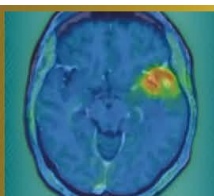
### Results

A linear dose response was observed from average 28Gy-272Gy and 7-205Gy to the cranial and spinal subarachnoid spaces respectively. Organ absorbed doses were 1-3Gy average liver, 2-6Gy spleen, and 0-3Gy blood. RNAseq of CSF samples (n=60 from 11 patients) revealed two distinct temporal gene expression patterns: early inflammation/innate immune cluster and subsequent proliferation/DNA repair cluster. Immune deconvolution demonstrated a delayed adaptive immune response driven primarily by CD8 T-cells across multiple timepoints, suggesting immune remodeling rather than acute exhaustion following 186RNL. Characterization of biological response in ID8agg ascites demonstrated that combination therapy with 186RNL and anti-PD1 induced a CD8-dominant immune response with increased activated CD8+ T-cells (CD69+, CD25+), preferential expansion of CD4+ effector T-cells over regulatory T-cells, and enhanced NK-cell populations while reducing monocytes. Combination therapy resulted in superior tumor control (p=0.008) and evidence of reduced omental tumor burden.

### Conclusions

186RNL safely achieves absorbed doses to LM over 8-fold conventional EBRT. In addition to tumor cells responses (apoptosis, G2M arrest), bulk RNAseq of CSF reveals temporal immune remodeling with delayed CD8 T-cell engagement following 186RNL, while flow cytometry of ovarian ascites confirms that this CD8-dominant adaptive response is functionally enhanced and therapeutically leveraged through anti-PD1 combination therapy. Further evaluation is ongoing in a repeated dosing trial (ReSPECT-LMM, NCT07098806).





**Abstract Number:** 48

**Abstract Title:** PET-Based Dosimetry of Intra-Arterial Y-90 Neurovascular Radiotherapy in Recurrent Glioblastoma: First-in-Human Feasibility

**Authors:**

**Dr. Kazim Narsinh**<sup>2</sup>, Dr. Nicholas Butowski<sup>2</sup>, Dr. Sam Mouli<sup>3</sup>, Dr. Sameer Ansari<sup>3</sup>, Dr. Matthew Tate<sup>3</sup>, Dr. Rimas Lukas<sup>3</sup>, Dr. Jonathan Weinstein<sup>4</sup>, Dr. Yafell Serulle<sup>4</sup>, Dr. John Boockvar<sup>4</sup>, Mr. Matthew Dreher<sup>1</sup>, Amanda Eldridge<sup>1</sup>, Mr. Paul Kennedy<sup>1</sup>, Ms. Samantha Ryan<sup>1</sup>, Mr. Franco Basarabescu<sup>1</sup>, Mr. Mohammed Goryawala<sup>1</sup>, Dr. Riad Salem<sup>3</sup>, Dr. Roger Stupp<sup>3</sup>

<sup>1</sup>Boston Scientific, Maple Grove, United States, <sup>2</sup>University of California San Francisco, San Francisco, United States, <sup>3</sup>Northwestern Memorial Hospital, Chicago, United States, <sup>4</sup>Lenox Hill Hospital Northwell Health, New York City, United States

**Background**

Treatment options for recurrent glioblastoma (rGBM) are limited. Neurovascular radiotherapy (NVRT) is a novel intra-arterial approach using glass yttrium-90 (Y-90) microspheres (TheraSphere™, Boston Scientific) to superselectively deliver high-dose radiation to malignancy. The FRONTIER trial is the first trial to adapt this technology to treat rGBM.

**Methods**

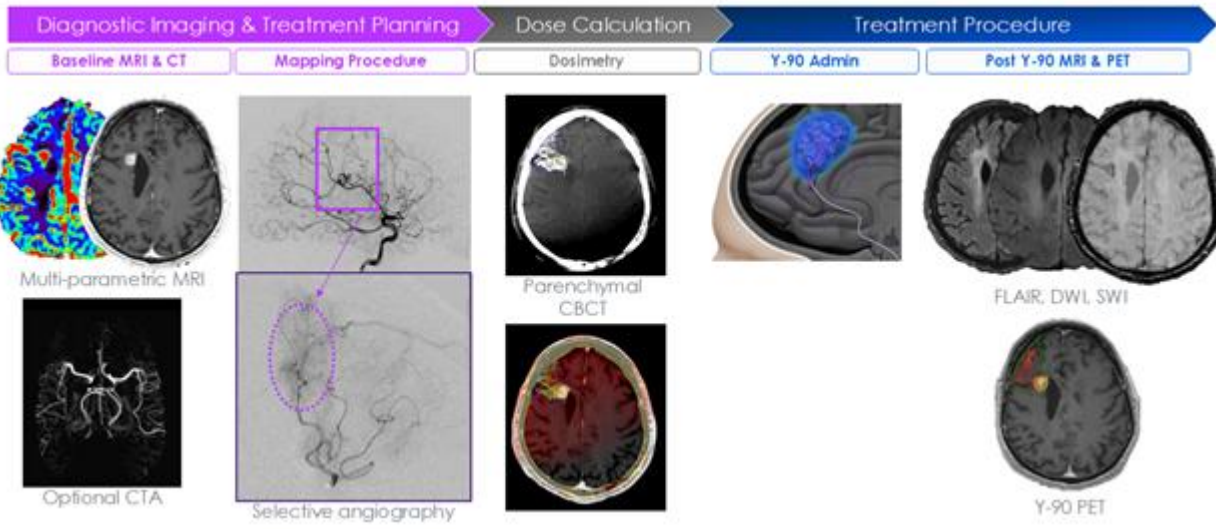
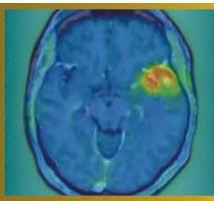
Multicenter, phase-1 study evaluating safety, feasibility, technical success, and quantitative dosimetry of NVRT in rGBM patients. Patients with 1-5cm diameter contrast-enhancing disease located in non-dominant, non-eloquent brain regions, who received ≤two prior lines of therapy underwent angiographic assessment. Patients were deemed eligible if perfused volume (PV) encompassed enhancing-disease without involving dominant/eloquent regions. Eligible patients underwent NVRT targeting 40Gy absorbed dose (AD) to the PV. Y-90-PET imaging performed within 36-hours post-treatment enabled quantification of AD distribution. Technical success was defined as achieving an AD within ±20% of the prescribed target. PET-based dosimetry and correlation with clinical outcomes were analyzed.

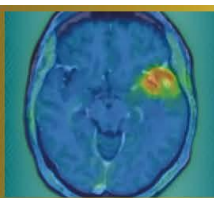
**Results**

Twenty patients underwent feasibility angiography, and 12 proceeded to NVRT. Technical success was achieved in all patients. Y-90-PET confirmed ≥96% of activity was confined to PV with a median AD of 41.5Gy. Dose to enhancing and non-enhancing volumes within PV was 124.2Gy (range 58.5-508.5Gy) and 36.3Gy, respectively, with a median tumor-normal-ratio of 3.8. No device-related adverse events (grade ≥3) or symptomatic radiation necrosis were reported throughout follow-up (median 12.1 months). Patients with tumor AD above the median (>124Gy) had improved OS (median 11.9 vs 5.7 months, Log-Rank p=0.0073).

**Conclusions**

Quantitative PET-based dosimetry confirmed delivery of Y-90 microspheres to the treatment volume with preferential deposition in rGBM, achieving tumor ADs greatly exceeding those feasible with EBRT while maintaining an acceptable safety profile. This imaging-guided workflow was successfully reproduced across 3 sites, demonstrating technical feasibility and establishing proof-of-concept for NVRT in rGBM. Future studies will refine dose planning and response modeling to optimize therapeutic efficacy.





**Abstract Number:** 49

**Abstract Title:** A Semi-Automated Approach to Glioblastoma Delineation on [18F]FET PET to Improve Automated Segmentation

**Authors:**

**Anass Hamdi**<sup>1,2</sup>, Selene De Sutter<sup>1</sup>, Ir. Laurens Raes<sup>3</sup>, Dr. Wietse Geens<sup>4</sup>, Prof. dr. Hendrik Everaert<sup>3</sup>, Sophie Bourgeois<sup>3</sup>, Pieter Boonen<sup>1,5</sup>, Jef Vandemeulebroucke<sup>1,5,6</sup>, Ine Dirks<sup>1,6</sup>, Prof. dr. Johnny Duerinck<sup>4</sup>

<sup>1</sup>Department of Electronics and Informatics (ETRO), Vrije Universiteit Brussel, Brussels, Belgium, <sup>2</sup>Fonds Wetenschappelijk Onderzoek (FWO), Brussels, Belgium, <sup>3</sup>Department of Nuclear Medicine, Vrije Universiteit Brussel, Universitair Ziekenhuis Brussel, Brussels, Belgium, <sup>4</sup>Department of Neurosurgery, Vrije Universiteit Brussel, Universitair Ziekenhuis Brussel, Leuven, Belgium, <sup>5</sup>Department of Radiology, Vrije Universiteit Brussel, Universitair Ziekenhuis Brussel, Brussels, Belgium, <sup>6</sup>Imec, Leuven, Belgium

### Background

Glioblastoma delineation guidelines on [18F]FET PET include background estimation through crescent VOI annotation and a spherical VOI enclosing the tumor. This approach shows high interobserver variability, causing diagnostic uncertainty and limiting performance of automated segmentation trained on such annotations.

### Methods

We present a semi-automated method for background estimation based on the contralateral side of a brain mask relative to the midsagittal plane. Background activity was estimated through linear regression relating the median SUV of this ROI to crescent VOI measurements. We evaluated the method on an in-house UZ Brussel [18F]FET PET cohort of 174 patients (85 newly diagnosed, 89 recurrent) where the mean MTV was  $32.1 \pm 32.3$  mL. Four experts (HE, SB, LR, WG) provided manual annotations according to PET RANO 1.0, leading to two annotations per image. We evaluated our method by comparing its performance to manual annotations in terms of interobserver variability and concordance of deep segmentation models when trained on the respective annotations. A 3D nnU-Net is used for segmentation.

### Results

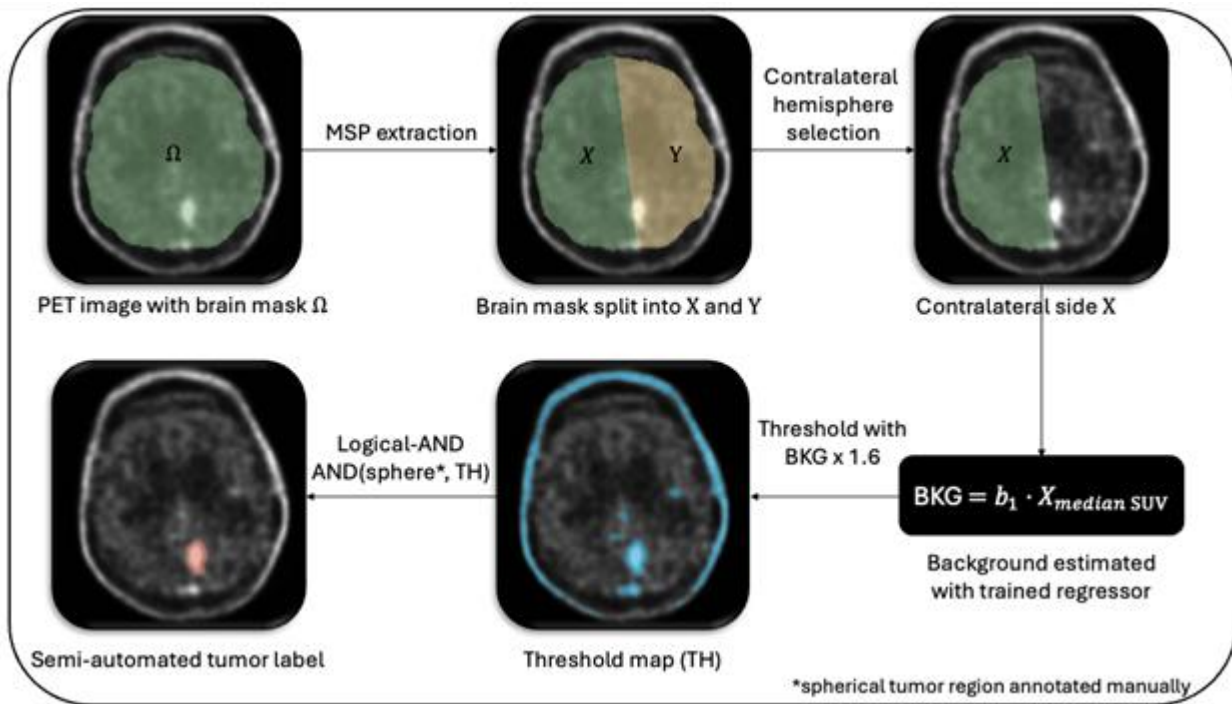
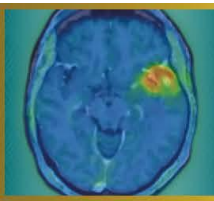
Results, reported as median (IQR), show manual and semi-automated delineations of the same annotator aligned closely with DSC 0.919 (0.162). However, interobserver variability showed DSC 0.882 (0.116) vs 0.787 (0.211) and AVE 2.899 (5.155) mL vs 4.270 (9.340) mL (semi-automated vs manual). Finally, nnU-Net trained on semi-automated annotations achieved DSC 0.871 (0.200) vs 0.772 (0.248) when trained on manual annotations.

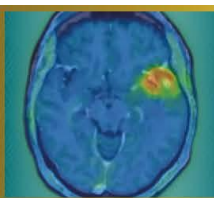
### Discussion

Automated background estimation reduced interobserver variability of semi-automated delineations, highlighting the importance of this step in the delineation procedure. This translated into better nnU-Net segmentation performance (median DSC=0.88), exceeding the state-of-the-art [18F]FET PET automated segmentation (median DSC=0.83).

### Conclusion

We propose a semi-automated approach to glioblastoma delineation on [18F]FET PET, which reduces interobserver variability and leads to more consistent automated segmentation. Future work should assess accuracy with respect to biological ground truth.





**Abstract Number:** 50

**Abstract Title:** Radiographic regression of parenchymal brain metastases after PRRT in metastatic well-differentiated neuroendocrine tumor: a case study

**Authors:**

**Joshua Qian**<sup>1</sup>, Zoe Goldberg<sup>1</sup>, Ross Weber<sup>1</sup>, Kaitlyn Lapen<sup>1</sup>, Alexander Terry<sup>1</sup>, Daniel Gorovets<sup>1</sup>, Lisa Bodei<sup>1</sup>, Brandon Imber<sup>1</sup>

<sup>1</sup>Memorial Sloan Kettering Cancer Center, New York City, United States

### Background

The suitability of radiopharmaceutical therapies, including peptide receptor radionuclide therapy (PRRT) for intracranial parenchymal metastases from well-differentiated (WD) neuroendocrine tumors (NETs) is poorly defined. While surgical resection and/or stereotactic radiosurgery (SRS) are standard of care, PRRT may be an option for addressing small, multiple asymptomatic intraparenchymal metastases. Despite precedents in meningioma, data on somatostatin receptor (SSTR)-directed radionuclide therapy in intraparenchymal metastases are essentially nonexistent, given their rarity. We describe the radiographic response of cerebellar metastases after <sup>177</sup>Lu-DOTATATE therapy in a patient with metastatic WD NET.

### Material and Methods

A 68-year-old woman with metastatic WD ileal NET (diagnosed 2012, later metastatic to liver, peritoneum, adnexa, and bone) previously received somatostatin analogs and PRRT (4 cycles, 2022) with favorable systemic response. She experienced extreme fatigue on octreotide and had treatment break (Aug 2024-July 2025). After resuming lanreotide, <sup>68</sup>Ga-DOTATATE PET/CT demonstrated new intensely octreotide-avid punctate posterior fossa lesions (SUVmax 5.1-15.8) and extracranial disease (including bones, intraabdominal nodes, peritoneal implants; size range: 1.1-3.3cm; SUVmax 9.1-44.9; Figure 1a). MRI confirmed multiple sub-centimeter (range: 0.3-0.6cm) enhancing cerebellar lesions suspicious for metastases without edema. Given small asymptomatic lesions, strong DOTATATE avidity, and plan for additional PRRT, multidisciplinary consensus elected observation with short-interval MRI rather than upfront SRS. The patient proceeded with <sup>177</sup>Lu-DOTATATE.

### Results

After 1 cycle of PRRT, MRI showed decrease in size of four cerebellar enhancing metastases (largest reduced from 0.6×0.6cm to 0.4×0.3cm; Figure 1b) with no new parenchymal or leptomeningeal enhancement and no suspicious perfusion increase. The patient remained neurologically asymptomatic; reported toxicity was limited to mild fatigue and alopecia. Repeat MRI after two additional cycles is planned.

### Conclusion

Octreotide-avid cerebellar parenchymal metastases demonstrated early radiographic regression after PRRT. Given SSTR expression can occur in histologies beyond NETs, this observation highlights a potential role for SSTR-directed PRRT in select patients and warrants further study.

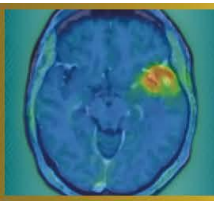
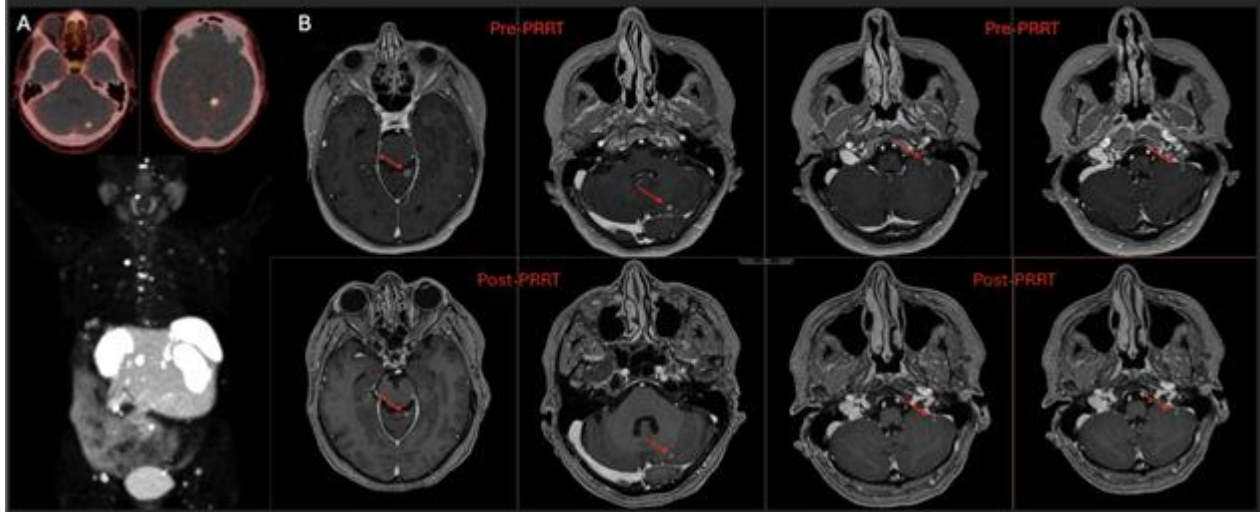
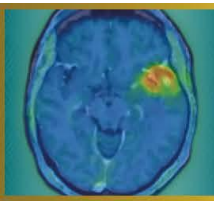


Figure 1. (A) Whole-body  $^{68}\text{Ga}$ -DOTATATE PET/CT axial slices of two intraparenchymal brain metastases and maximum intensity projection showing somatostatin receptor-avid metastatic disease. (B) Representative axial post-contrast T1 MP-RAGE MRI demonstrating interval decrease in size of sub-centimeter cerebellar metastases pre-PRRT versus post-PRRT ( $^{177}\text{Lu}$ -DOTATATE).





**Abstract Number:** 51

**Abstract Title:** Multimodal Imaging: MRI and 68Ga-DOTA-TATE PET/CT for Detection of Residual Meningioma with Transverse Sinus Invasion

**Authors:**

**Elif Reyhan Aslan**<sup>1</sup>, Nazım Coşkun<sup>1</sup>, Turan Kaya<sup>2</sup>, Mehmet Burak Bölükbaşı<sup>3</sup>, Fevziye İlknur Kayalı<sup>3</sup>, Servet Güreşçi<sup>4</sup>, Elif Özdemir<sup>1</sup>

<sup>1</sup>Ankara Bilkent City Hospital Department of Nuclear Medicine, Ankara, Türkiye, <sup>2</sup>Ankara Bilkent City Hospital Department of Radiology, Ankara, Türkiye, <sup>3</sup>Ankara Bilkent City Hospital Department of Radiation Oncology, Ankara, Türkiye, <sup>4</sup>Ankara Bilkent City Hospital Department of Pathology, Ankara, Türkiye

### Background

Venous sinus invasion represents a critical prognostic and surgical challenge in meningiomas, as complete resection may be limited by the need to preserve venous outflow. Postoperative contrast-enhanced Magnetic Resonance Imaging (MRI) remains the standard imaging modality; however, postoperative enhancement along the sinus may be nonspecific and cannot reliably differentiate residual tumor from postoperative changes or sinus thrombosis. Molecular imaging targeting somatostatin receptor subtype 2 (SSTR2), which is commonly expressed in meningiomas, offers the potential to differentiate viable tumor tissue from non-neoplastic postoperative changes.

### Case Presentation

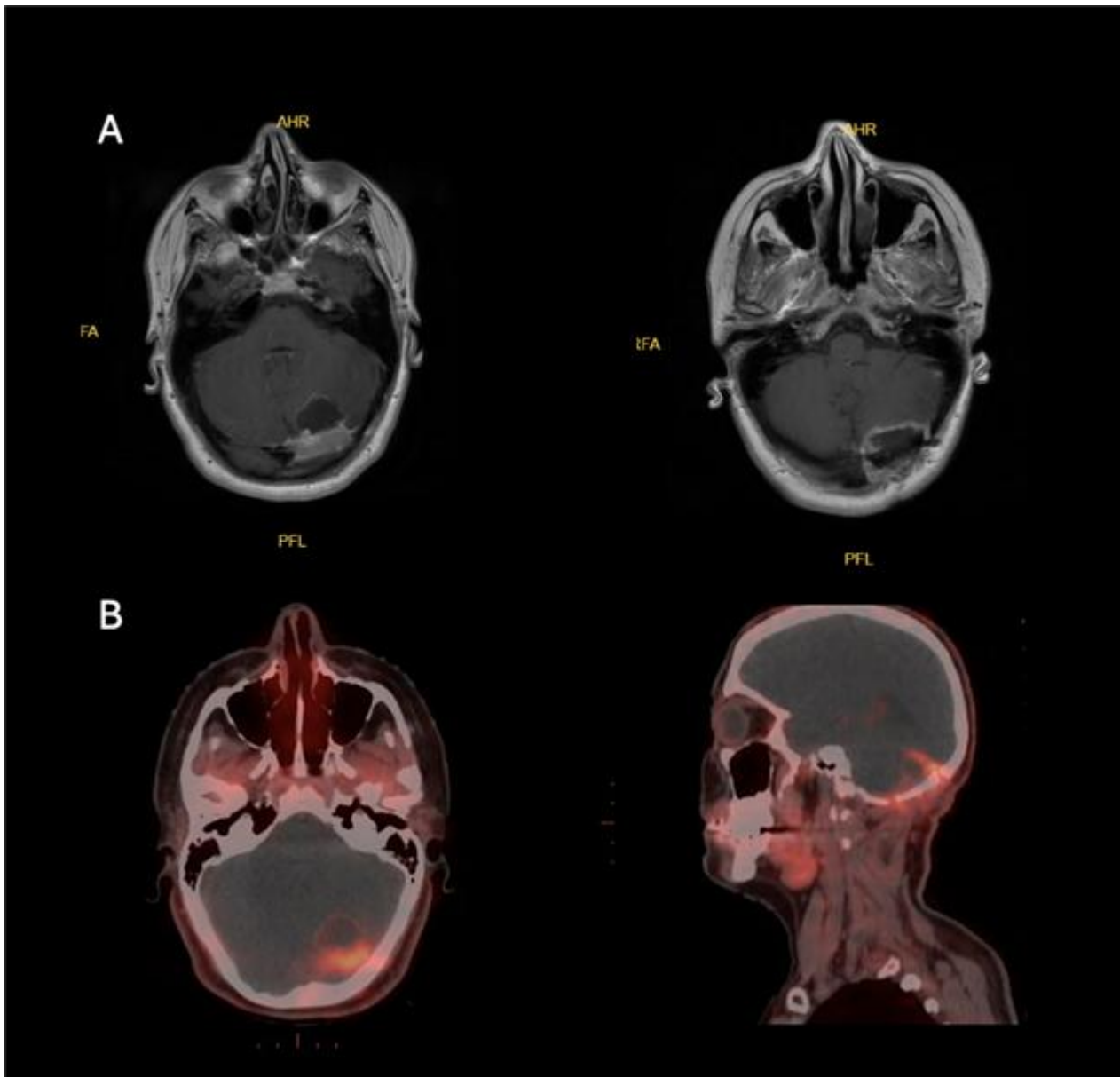
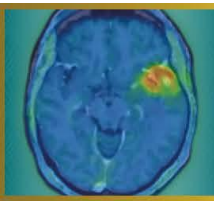
We report a 33-year-old woman who underwent surgical resection of an atypical meningioma (WHO grade II, Ki-67 proliferation index: %8-10). Postoperative MRI demonstrated indeterminate findings along the transverse sinus, precluding confident differentiation between residual tumor and thrombosis (Figure A). 68Ga-DOTA-TATE PET/CT was performed before adjuvant treatment planning. The study demonstrated radiotracer uptake supporting the presence of residual SSTR2-expressing meningioma along the transverse sinus (Figure B).

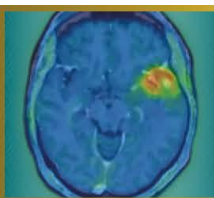
### Discussion

Postoperative MRI alone often cannot reliably distinguish residual tumor from reactive changes or sinus thrombus, particularly along the venous sinus. Therefore, integration of PET/CT with MRI is important for accurate characterization and optimal treatment planning. This multimodal approach may guide adjuvant therapy and improve radiotherapy target delineation for meningiomas.

### Conclusion

In meningiomas with venous sinus invasion, 68Ga-DOTA-TATE PET/CT can offer important molecular confirmation of residual tumor when MRI findings are equivocal, potentially influencing postoperative management and improving precision in adjuvant therapy planning.





**Abstract Number:** 52

**Abstract Title:** Significant uptake of a copper-64 labelled non-specific isotype antibody by myeloid cells in the tumor microenvironment of murine glioblastoma

**Authors:**

**Lena Wesser**<sup>1</sup>, Laura M. Bartos<sup>1</sup>, Marlies Härtel<sup>1</sup>, Lea H. Kunze<sup>1</sup>, Dr. Felix Lindheimer<sup>1</sup>, Prof. Dr. Rudolf A. Werner<sup>1,2</sup>, Prof. Dr. Luisa von Baumgarten<sup>3,4</sup>, Nathalie L. Albert<sup>1,4,5</sup>, Dr.rer.nat. Simon Lindner<sup>1,6</sup>, Matthias Brendel<sup>1,4,6,7</sup>

<sup>1</sup>Department of Nuclear Medicine, LMU University Hospital, LMU Munich, Munich, Germany, <sup>2</sup>Russell H. Morgan Department of Radiology and Radiological Sciences, Johns Hopkins School of Medicine, Baltimore, United States of America, <sup>3</sup>Department of Neurosurgery, University Hospital of Munich, LMU Munich, Munich, Germany, <sup>4</sup>German Cancer Consortium (DKTK), Partner Site Munich, German Cancer Research Center (DKFZ), Heidelberg, Germany, <sup>5</sup>Bavarian Cancer Research Center (BZKF), Erlangen, Germany, <sup>6</sup>Munich Cluster of Systems Neurology (SyNergy), Munich, Germany, <sup>7</sup>German Center for Neurodegenerative Diseases (DZNE), Munich, Germany

**Background**

Tumor-associated myeloid cells (TAMs) are pivotal components of the tumor microenvironment (TME) of glioblastoma as they display heterogenous and immunosuppressive phenotypes. This study investigates uptake of a non-specific isotype antibody in TAMs and its potential implications for cellular distribution of radiotracers.

**Methods**


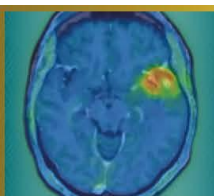
Twelve APPSAA x hTfR KI mice were inoculated with 1,000 SB28 tumor cells. Five mice received  $57 \pm 4$  MBq of [<sup>64</sup>Cu]Cu-NODAGA-ATV:4D9 (a brain shuttle-mediated tracer targeting myeloid cells), while seven were injected with  $54 \pm 1$  MBq of the corresponding isotype. APPSAA mice, characterized by increased myeloid activation, were used for all conditions. The isotype antibody shares the same immunoglobulin class and subclass as the ATV:4D9, but lacks specificity for TREM2. Static PET imaging was performed 20 hours post-injection, followed by brain extraction for immunomagnetic cell sorting and gamma counting. Additionally, 16 mice without tumor inoculation received either ATV:4D9 (n=7) or the isotype (n=9) and underwent identical procedures.

**Results**

Tracer uptake was highest in TAMs from mice injected with ATV:4D9 ( $1.05 \times 10^{-6} \pm 1.76 \times 10^{-7}$  %ID\*BW per cell), but remained substantial in TAMs from mice receiving the non-specific isotype antibody ( $7.38 \times 10^{-7} \pm 1.64 \times 10^{-7}$  %ID\*BW per cell, i.e. 70% of the specific antibody). In mice without tumor, myeloid cell tracer uptake was significantly lower compared to glioblastoma mice (ATV:4D9: 9.9-fold lower,  $p < 0.0004$ ; isotype: 150-fold lower,  $p < 0.0001$ ). Myeloid cell tracer uptake strongly correlated with PET signal across all conditions ( $p < 0.0001$ ).

**Conclusion**

The significant uptake of a non-specific isotype antibody in TAMs of mice with glioblastoma suggests an additional uptake mechanism, likely via phagocytosis. This effect appears specific to TAMs within the TME of glioblastoma and may generally contribute to radiotracer uptake in glioblastoma.



**Abstract Number:** 53

**Abstract Title:** Mapping of Myeloid Cells in the Tumor Microenvironment of Glioblastoma using Transport Vehicle Mediated TREM2 PET Imaging

**Authors:**

**Laura Bartos**<sup>1</sup>, Ruoqing Feng<sup>2</sup>, Katharina Müller<sup>1</sup>, Anna Kössinger<sup>1</sup>, Nina Teske<sup>1</sup>, Tobias Greve<sup>1</sup>, Jens Blobner<sup>1</sup>, Rebecca Schaefer<sup>1</sup>, Marlies Haertel<sup>1</sup>, Lu Liu<sup>2</sup>, Dario Dhoqina<sup>1</sup>, Johannes Gnörich<sup>1</sup>, Rudolf Werner<sup>1</sup>, Veit Stoecklein<sup>1</sup>, Florian Ringel<sup>1</sup>, Ana-Claire Meyer<sup>3</sup>, Joseph Lewcock<sup>3</sup>, Kathryn Monroe<sup>3</sup>, Kai Schlepckow<sup>2</sup>, Christian Haass<sup>2</sup>, Jochen Herms<sup>1</sup>, Nathalie Albert<sup>1</sup>, Louisa von Baumgarten<sup>1</sup>, Patrick Harter<sup>1</sup>, Mikael Simons<sup>2</sup>, Simon Lindner<sup>1</sup>, Matthias Brendel<sup>1</sup>

<sup>1</sup>University Hospital of Munich (LMU), Munich, Germany, <sup>2</sup>German Center for Neurodegenerative Diseases (DZNE), Munich, Germany, <sup>3</sup>Denali Therapeutics, San Francisco, USA

**Background**

Glioblastoma combines a lack of immunogenicity with a highly immunosuppressive tumor microenvironment (TME), including both tumor cells and tumor-associated microglia/macrophages (TAMs). However, biomarkers that allow for specific detection, monitoring and therapy response assessment of the TAM phenotype in glioblastoma are still lacking.

**Material and Methods**


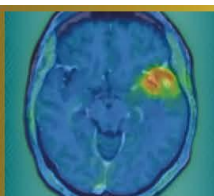
We analyzed the dynamics of TAM populations in the TME of experimental SB28 glioblastoma using single-cell RNA sequencing, immunofluorescence and molecular imaging, and identified Triggering Receptor Expressed on Myeloid Cells 2 (TREM2) as a TAM-specific target with dynamic expression across distinct tumor stages. We next evaluated a novel <sup>64</sup>Cu-labeled TREM2 PET tracer engineered with a blood–brain barrier transport vehicle for in vivo assessment of TAMs in the glioblastoma TME. The tracer was tested in different experimental settings, including myeloid cell depletion and TREM2 stimulation, and finally translated into a pilot cohort of patients with glioblastoma.

**Results**

We found strong and highly TAM-specific PET signals that followed the trajectory of TREM2 gene expression from early- towards late-stage tumors. Transient myeloid cell depletion via CSF1R inhibition showed a reduction of TREM2 PET signals compared to placebo and prolonged survival in SB28 glioblastoma mice, while TREM2 stimulation led to increased TREM2 PET signals. Translation into a pilot cohort of patients with glioblastoma revealed strong TREM2 PET signals predominantly at lesion edges, showing only partial overlap with the area of contrast enhancement in MRI or tumor volumes in amino acid PET. We observed high heterogeneity across patients, matching with the individual TREM2 immunohistochemistry.

**Conclusion**

TREM2 PET imaging enables specific, non-invasive assessment of TAMs in glioblastoma and is sensitive to immunomodulatory treatment effects. Thus, TREM2 PET holds promise as an immune cell-specific biomarker for personalized characterization of the glioblastoma tumor microenvironment.



**Abstract Number:** 54

**Abstract Title:** SSTR SPECT/CT volumetric changes during  $^{177}\text{Lu}$ -DOTATATE therapy and their relation to progression and quality of life in recurrent meningioma.

**Authors:**

**Stela Asadurova**<sup>1</sup>, Diego Gomez<sup>1</sup>, David Sanchez<sup>1</sup>, Cristina Auger<sup>1</sup>, Fidel Nuñez<sup>1</sup>, Fran Martinez<sup>1</sup>, Esteban Cordero<sup>1</sup>, Antonio Biroli<sup>1</sup>, Xavier Maldonado<sup>1</sup>, Josep Garré<sup>1</sup>, Helena Ariño<sup>1</sup>, Elena Martinez<sup>1</sup>, Amparo García<sup>1</sup>, Judith Suits<sup>1</sup>, Carles Lorenzo<sup>1</sup>, Cristina Gamez<sup>1</sup>, Maria Vieito<sup>1</sup>

<sup>1</sup>University Hospital Vall d'Hebron, Barcelona, Spain

**Background**

Radioligand therapy (RLT) with  $^{177}\text{Lu}$ -DOTATATE is currently used in recurrent meningioma, but somatostatin-receptor (SSTR) imaging dynamics data and patient-reported outcome are limited.

**Material and Methods**

Five patients with recurrent meningioma received four cycles RLT with  $^{177}\text{Lu}$ -DOTATATE. Baseline  $^{68}\text{Ga}$ -DOTATOC PET/CT was used to calculate MTV, TL-SSRE, SUVmax and Krenning score. Post-treatment SPECT/CT at each cycle (C1-C4) was performed on 360° CZT SPECT/CT gammacamera and used to calculate MTV, equivalent SUVmean and TL-SSRE. Per-patient change was assessed from first available cycle to C4. Quality of life was collected at each cycle using EORTC QLQ-BN20 and linearly transformed to 0-100 score (higher=worse). Imaging, outcome and QoL trends were explored descriptively.

**Results**


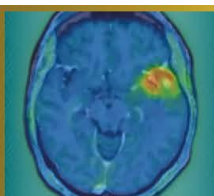
PFS-6 was 80% (4/5) with stable disease (SD) and 1 patient (20%) progressed early on treatment (PD; PFS 3.4 months). Among patients with 1-year follow-up, OS-1 was 100% (3/3). The PD case had markedly lower baseline receptor burden (PET MTV 2.44 and TL-SSRE 11.7 vs 23.3 - 107.9 and 157.7 - 782.9 in SD, respectively) and showed concordant SPECT declines to C4 (MTV -19.3%, SUVmean -14.6%, TL-SSRE -30.9%) with worsening score on BN20 (including neurological symptoms and bladder dysfunction). In SD patients, SPECT MTV and TL-SSRE increased on average (+26.6% and +28.3%; SUVmean +1.4%). BN20 total symptom burden remained low (mean 14.6 at baseline to 18.8 at C4): neurologic domains stayed low (mean 13-17) while toxicity emerged (hair loss and pruritus). One G2 patient with Krenning 4 had delayed progression (PFS 14.4 months).

**Discussion**

This very small cohort limits generalizability; larger prospective studies are needed to validate imaging and quality-of-life associations.

**Conclusion**

Very low baseline TL SSRE and falling on-treatment SPECT SSTR metrics aligned with early PD and neurologic deterioration, whereas SD (PFS-6 80%) was associated with preserved neurologic QoL despite frequent increases in SPECT-derived volumetrics and mild treatment-related symptoms.



**Abstract Number:** 55

**Abstract Title:** Targeting SSTR2 With [<sup>212</sup>Pb]VMT-α-NET in meningioma patients: Design of the First in Human Phase I/IIa LEMONαDE Trial

**Authors:**

**Nathalie Albert**, Lucia Baratto, Alaa Hanna, Wenjing Yang, Steve Keefe, Markus Pulhman, Matthias Preusser<sup>1</sup>

<sup>1</sup>Division of Oncology, Department of Medicine I, Medical University of Vienna, Vienna, Austria

### Background

[<sup>212</sup>Pb]VMT-α-NET is a novel targeted alpha-particle radiopharmaceutical targeting somatostatin receptor type 2 (SSTR2)-expressing tumors. Safety and efficacy data from the dose-finding Phase 1/2a clinical trial in neuroendocrine tumors (NETs) (NCT05636618) demonstrated a favorable safety profile and signals of sustained antitumor activity at the 2.5 mCi and 5 mCi dose levels. Here, we describe the design of a first-in-human Phase I/IIa study evaluating [<sup>212</sup>Pb]VMT-α-NET in patients with meningioma (LEMONαDE: [<sup>212</sup>Pb]VMT-α-NET for Meningioma; NMN-03).

### Materials and Methods

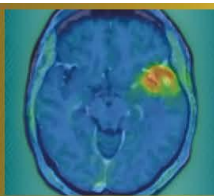
The LEMONαDE study will include up to 20 subjects with meningioma. The first 3 subjects will be enrolled in a short run-in period at a dose level of 185 MBq (5 mCi) of [<sup>212</sup>Pb]VMT-α-NET for safety assessment; the remaining 17 subjects will be enrolled in a Simon's 2-stage design at a dose level deemed safe to evaluate treatment. Participants may receive up to four administrations of [<sup>212</sup>Pb]VMT-α-NET at their assigned dose level, and they are monitored for dose limiting toxicities (DLTs) for 42 days and safety throughout the study. Subjects with meningioma will also participate in a dosimetry sub-study. The primary efficacy endpoint is response rate as evaluated by local investigators according to RANO meningioma criteria (null hypothesis: 5%, alternative hypothesis: 25%). Dosimetry is included as a supportive analysis.

### Results

Eligible patients must have histologically confirmed meningioma of any grade, have undergone at least one prior surgical procedure (resection or biopsy), received no more than one prior line of external beam radiotherapy, and demonstrated radiographic disease progression as well as SSTR positivity on PET imaging prior to enrollment. Patients previously treated with systemic peptide receptor radionuclide therapy are excluded.

### Conclusions

LEMONαDE is a first-in-human study designed to characterize safety, dosimetry, and preliminary efficacy of targeted alpha-therapy with [<sup>212</sup>Pb]VMT-α-NET in meningioma. The study is not yet enrolling.



**Abstract Number:** 56

**Abstract Title:** Hijacking low-density lipoprotein receptors (LDLR) to target glioblastoma

**Authors:**

**Izabela Tworowska**<sup>1</sup>, Leo Flores<sup>1</sup>, Cedric Malicek<sup>2</sup>, Rafal Zielinski<sup>3</sup>, Perry Davis<sup>1</sup>, Pretty Joy<sup>1</sup>, Pascaline Lecorche<sup>3</sup>, Jamal Temsamani<sup>3</sup>, Ebrahim Delpassand<sup>1</sup>

<sup>1</sup>Radiomedix, Houston, United States, <sup>2</sup>Vect-Horus, Marseille, France, <sup>3</sup>MDAnderson Cancer Center, Houston, United States

**Background**

Low-density lipoprotein-receptors (LDLR) are upregulated in glioblastoma (GBM), where they support tumor growth and altered-metabolic needs. LDLRs are also present at the blood–brain-barrier (BBB), creating an opportunity to leverage receptor-mediated-transport for the radiotheranostic applications. Here, we report results for the second-generation LDLR-targeting agent, RMX-VH-PKM, engineered to prolong blood-circulation-time and enhance tumor uptake.

**Materials and Methods**

The RMX-VH-PKM was labeled <sup>212</sup>Pb (4-8mCi, RAHA <sup>224</sup>Ra/<sup>212</sup>Pb generator, Radiomedix) in buffer pH=6.0/temp80°C in the presence of scavengers. Radiolabeling with <sup>203</sup>Pb (4-5mCi, UA Cyclotron Facility) was conducted under similar conditions. SPECT/CT imaging of <sup>203</sup>Pb/<sup>212</sup>Pb-RMX-VH-PKM in U87MG- xenografts was performed at multiple time-points, followed by biodistribution studies. In parallel, pilot efficacy studies of <sup>212</sup>Pb-RMX-VH-PIB were evaluated in an orthotopic-U251 model. Mice (n = 5/group) received fractionated-dosing to achieve cumulative activities of 17.4±1uCi (cohort 1) or 33.3±2uCi (cohort 2), while control received no-treatment. Therapeutic response was assessed using PET/CT imaging with <sup>18</sup>F-fluciclovine(Axumine), along with monitoring of body weight and clinical signs.

**Results**

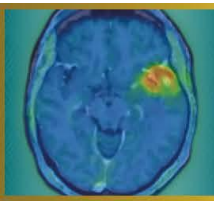
Biodistribution studies of <sup>212</sup>Pb-RMX-VH-PKM in U87MG xenografts demonstrated sustained tumor retention, with uptake of 6.6±0.4%ID/g at 1h post-injection, decreasing to 4.8±0.6%ID/g at 3h and further to 2.7±0.6%ID/g at 24h post-injection. Administering a 40-fold excess of non-radiolabeled RMX-VH-PIB before <sup>203</sup>Pb-RMX-VH-PKM minimally affected tumor uptake but reduced liver uptake by 42.2% at 1–3h compared to the <sup>203</sup>Pb-analog alone. Biodistribution of <sup>22</sup>Pb-RMX-VH-PKM, showed a comparable distribution to the <sup>203</sup>Pb-labeled-analogue, with the highest tumor-retention at 1-3h (13.4±5.2%ID/g and 12.4±1.6%ID/g, respectively, 6.2±2%ID/g at 24h). In pilot survival-studies using a fractionated-dosing of <sup>212</sup>Pb-RMX-VH-PIB in an orthotopic-U251-model, a statistically significant tumor growth inhibition was observed in both treatment cohorts for up-to-35days following therapy initiation.

**Discussion**

<sup>203</sup>Pb/<sup>212</sup>Pb-RMX-VH-PIB consistently targets LDLR-expressing GBM. Adjusting specific-activity decreased uptake in liver without affecting tumor accumulation, and fractionated <sup>212</sup>Pb-RMX-VH-PKM doses produced encouraging results.

**Conclusions**

These results support further dosing optimization and clinical translation of the LDLR-targeted-radiotheranostics.

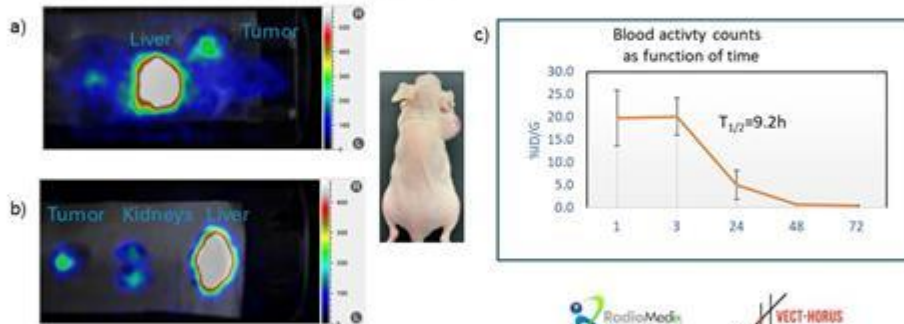


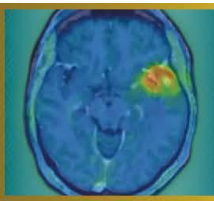
**Figure 1.**

a) SPECT/CT studies of  $^{203}\text{Pb}$ - RMX-VH-PKM in U87MG xenografts acquired 3h post injection.

b) SPECT imaging of selected organs dissected during biodistribution studies done 3h post-injection

c) Blood circulation half life of  $^{203}\text{Pb}$ - RMX-VH-PKM





**Abstract Number:** 57

**Abstract Title:** TSPO PET reveals dynamic myeloid activation in the skull bone marrow of glioblastoma patients

**Authors:**

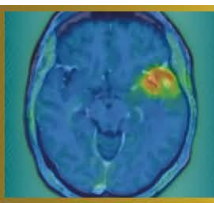
Laura M. Bartos<sup>1,2,3</sup>, Meghma Mukherjee<sup>4</sup>, Lukas Frontzkowski<sup>1,5</sup>, Gloria Mueller<sup>1</sup>, Sena Gül Turhan<sup>1</sup>, Abir Hussein<sup>4</sup>, Artem Zatcepin<sup>1,6</sup>, Justus Thevis<sup>1</sup>, Ha Eun Park<sup>1</sup>, Marlies Härtel<sup>1</sup>, Lea H. Kunze<sup>1</sup>, Karin Wind-Mark<sup>1</sup>, Rudolf A. Werner<sup>1,7</sup>, Veit Stöcklein<sup>8</sup>, Nicolai Franzmeier<sup>5,9,10</sup>, Louisa von Baumgarten<sup>8,11,12,13</sup>, Martin Proescholdt<sup>14,15</sup>, Nathalie L. Albert<sup>1,12,13</sup>, Peter Hau<sup>15</sup>, Philipp Beckhove<sup>4,16</sup>, Matthias Brendel<sup>1,6,9,12</sup>, Zeynep Ilgin Kolabas<sup>1,9</sup>

<sup>1</sup>Department of Nuclear Medicine, University Hospital, LMU Munich, München, Deutschland, <sup>2</sup>Institute of Clinical Neuroimmunology, University Hospital Munich, Ludwig-Maximilians University Munich, München, Deutschland, <sup>3</sup>Biomedical Center (BMC), Faculty of Medicine, LMU Munich, München, Deutschland, <sup>4</sup>Department of Interventional Immunology, Leibniz Institute for Immunotherapy, Regensburg, Deutschland, <sup>5</sup>Institute for Stroke and Dementia Research, LMU University Hospital, LMU Munich, 81377 Munich, Germany <sup>6</sup>German Center for Neurodegenerative Diseases (DZNE) Munich, München, Deutschland <sup>7</sup>Russell H. Morgan Department of Radiology and Radiological Sciences, Johns Hopkins School of Medicine, Baltimore, USA, <sup>8</sup>Department of Neurosurgery, LMU University Hospital, LMU Munich, München, Deutschland, <sup>9</sup>Munich Cluster for Systems Neurology (SyNergy), München, Deutschland, <sup>10</sup>Department of Psychiatry and Neurochemistry, University of Gothenburg, Sahlgrenska Academy, Institute of Neuroscience and Physiology, Mölndal and Gothenburg, Sweden <sup>11</sup>Department of Neurology, LMU University Hospital, LMU Munich, München, Deutschland, <sup>12</sup>German Cancer Consortium (DKTK), Partner Site Munich, A Partnership Between the DKFZ Heidelberg and the University Hospital of the LMU, München, Deutschland, <sup>13</sup>Bavarian Cancer Research Center (BZKF), Partner Site Munich, München, Deutschland, <sup>14</sup>Department of Neurosurgery, University Regensburg Medical Center, Regensburg, Deutschland <sup>15</sup>Department of Neurology-NeuroOncology and Wilhelm Sander NeuroOncology, University Hospital Regensburg, Regensburg, Deutschland, <sup>16</sup>Department of Internal Medicine III, University Hospital Regensburg, Regensburg, Germany.

**Background:** Glioblastoma (GB) is a highly malignant primary brain tumor with persistently poor prognosis despite intensive research efforts. Growing evidence indicates that the tumor-associated immune microenvironment plays a central role in disease progression and treatment response. Alongside intratumoral immune cell populations, extracranial compartments are increasingly attracting attention. In particular, the skull bone marrow is now recognized as an active immune compartment that communicates directly with the central nervous system.

**Objective:** The aim of this study was to translationally characterize immune cell activity in the skull bone marrow of GB patients using translocator protein (TSPO) positron emission tomography (PET). In addition, we sought to investigate whether skull TSPO PET signals correlate with tumor parameters and how they change longitudinally over the disease course and in response to therapy.

**Methods:** TSPO PET data from patients with newly diagnosed GB (n = 40) were analyzed to investigate immune cell activity in the skull bone marrow. Regional skull TSPO PET signals were compared with an age- and sex-matched control group and correlated with tumor location and tumor volumes derived from TSPO PET and MRI. A subgroup of patients (n = 7) who underwent TSPO PET after radiochemotherapy (RCT) without prior surgical resection was used to monitor longitudinal assessment of skull signal and therapy effects. For experimental validation, longitudinal TSPO PET was performed in the SB28 GB mouse model at early, intermediate, and late stages of tumor growth. Specificity testing was performed using unlabeled (cold) TSPO tracer to confirm that PET signals originate predominantly from TSPO-expressing cells rather than from free tracer in the bone marrow or adjacent tissue. Finally, flow cytometric analyses were conducted on intraoperatively obtained bone samples from GB patients and from patients with idiopathic intracranial hypertension as controls, to determine TSPO expression and immune cell composition.



**Results:** GB patients showed globally elevated skull bone marrow TSPO PET signals, most pronounced in frontotemporal areas (+24%;  $p < 0.001$ ). Skull signal intensity correlated with the TSPO PET signal of the tumor ( $R = 0.39$ ;  $p = 0.016$ ), with TSPO-positive tumor volume ( $R = 0.39$ ;  $p = 0.019$ ), and with T2-FLAIR tumor volume ( $R = 0.46$ ;  $p = 0.0042$ ). Superficially located tumors exhibited higher TSPO PET signals in the adjacent skull bone, with signal elevation spatially corresponding to tumor location. In the longitudinally assessed subgroup, a high regional correlation of baseline and follow-up skull TSPO PET signals was observed ( $R = 0.77$ ;  $p < 0.001$ ), as well as a consistent reduction in signal intensity after RCT ( $-17\%$ ;  $p = 0.039$ ). In the mouse model, comparable regional distribution patterns were found, with peak signal at the intermediate time point followed by a decline. Cold tracer administration reduced skull bone marrow signal, confirming the cell-specific origin of the PET signals. Human bone samples from GB patients showed elevated TSPO expression and increased proliferation of myeloid cell populations compared to controls.

**Conclusions:** The present findings provide evidence for a functionally active myeloid immune cell population in the skull bone marrow of GB patients, which displays dynamic changes over time and can be detected by TSPO PET. These results extend existing knowledge on lymphocytes and neutrophils in the skull bone marrow and highlight the importance of this previously underexplored immune compartment. The study also opens new perspectives for the development of imaging-based biomarkers for detecting myeloid immune cell activity, and for targeted immunomodulatory therapeutic approaches in neuro-oncology.